



## **The Effect of Commercial Probiotics on Histological changes in the muscle of Ornamental fish *Puntius conchoni*us.**

**S. Kalaimani<sup>1</sup> and K. Parvathi<sup>2\*</sup>**

<sup>1</sup>GTN College, Dindigul, Tamil Nadu, India.

<sup>2</sup>Erode Arts and Science College (Autonomous), Erode – 09, Tamil Nadu, India.

\*Corresponding author: **Dr. K. Parvathi**, E-mail : [parsieac95@gmail.com](mailto:parsieac95@gmail.com)

### **Abstract**

The present study aims to find out the effect of commercial probiotics (Lact – Act) on histological changes in the skeletal muscle of Ornamental fish *Puntius conchoni*us. The similar size (5.00 gm weight and 5.4 cm length) of the ornamental fish were divided into two groups as control and experimental. Control groups were fed with supplementary feed and the experimental groups were fed with commercial probiotics along with supplementary feed. The experiments were carried out for 30 days and tissue samples were observed on 15<sup>th</sup> and 30<sup>th</sup> days of an experiment. The increased cell proliferation and cytoplasmic size were observed in the muscle of probiotic fed fish.

**Keywords:** *Puntius conchoni*us, commercial probiotics, skeletal muscle.

### **Introduction**

Probiotics are bio-friendly agent which can be introduced into the surrounding environment to promote the growth of aquatic organism by inhibiting the growth of pathogenic bacteria in the same habitat (Parvathi *et al.*, 2013). Probiotics are live microbial feed which beneficially affects the host animal by improving its intestinal microbial balance” (Fuller, 1988). Probiotics have been used in aquaculture to increase the growth of cultivated species and may also stimulate appetite and improve nutrition by the production of vitamins, detoxification of injurious compounds in the diet by the breakdown of indigestible components (Abd El-rhman *et al.*, 2008a). Rosy barb, *Puntius conchoni*us is an ornamental fish, found in natural conditions in the tropical water of south east Asia, it is a popular domestic aquarium fish with attractive colour and ease breeding (Cek *et al.*, 2001; Cek and Gokce,

2005). Histological studies are important for an evaluation of changes in aquatic animals exposed to various hazards in an aquatic environment (Mayer and Hendricks, 1985). The use of probiotics in aquaculture (Kozasa 1986; Gatesoupe 1991; 1994; Uma *et al.* 1999; Irianto and Austin 2002), and freshwater ornamental fish culture (Abraham *et al.* 2007a, b; Abraham, 2008) is well documented. The use of a feed probiotic for improved health and reproductive performance has also been reported in ornamental fish (Dhert *et al.*, 1997; Geiger, 2001; Irianto *et al.* 2003; Ghosh *et al.*, 2007a). Gobinath and Ramanibai, (2014) reported the histological alterations of gills, muscles, liver and kidney in probiotic fed rohu fish, but research on the effect of commercial probiotics on the muscle histology of ornamental fish are lacking. Hence, the present investigation aims to find out the influence of commercial probiotics "Lact-act" on histological

changes in the skeletal muscle of Ornamental fish *Puntius conchoni*us.

## Materials and Methods

### Collection of experimental animals

The experimental animal selected for the present study was ornamental fish Rosy Barb (*Puntius conchoni*us) (Plate no.1). Fish with similar size (5.00 gm weight

and 5.4 cm length) were purchased from Sirago fish farm, Nerinjipet, Erode District, Tamil Nadu and acclimatized in laboratory conditions (23<sup>0</sup> C/74<sup>0</sup> F, pH 7.0) with continuous aeration for two weeks prior to the commencement of an experiment. Stocked fish were fed with supplementary diet *ad libitum*.



Plate No.1. Experimental fish *Puntius conchoni*us

### Commercial feed probiotics

Lact -act is a gut probiotic, commercially available and were purchased from Poseidon Biotech

Company, Chennai-37, Tamil Nadu. Each kg powder contains: *Lactobacillus sporogens*(1500 million spores per gm), *Bacillus subtilis*, Yeast hydrolystate, Alpha amylase and Vitamin and mineral mix.

### Ingredients of supplementary feed

Table-1.Ingredients of Supplementary Feed.

S.No	Ingredients	Gram
1	Rice bran	23
2	Ground nut oil cake	21
3	Fish meal (Dry)	30
4	Soya beans	10
5	Wheat flour	15
6	Vitamins & Minerals	1

### Experimental design

*Puntius conchoni*us with similar weight (5.00 gm wt and 5.4 cm length) were chosen for the present experiment. The initial weight and length of the fish were recorded. One tub was kept as control (C) and another tub was kept as Experiment (E). Fifteen fish were introduced into each tub. The control fish were fed only with supplementary diet (without probiotics) and fish in an experimental tub were fed with

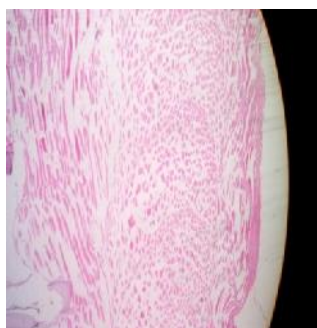
supplementary diet along with 0.2g commercial feed probiotic 'Lact - act' once in a day (morning at 6 am to 7 am). Each treatment had three replicates. Experiments were carried out for 30 days. At the end of 15<sup>th</sup> and 30<sup>th</sup> day of experimental periods, fish from control and experimental groups were sacrificed and muscle were dissected out by Culling method (1974) and sectioned at 7 mm thickness and stained with haematoxylin – Eosin and changes were photographed using Nikon photomicroscope.

## Results and Discussion

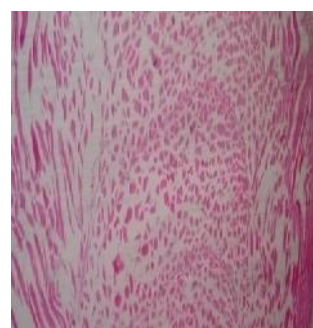Aquatic environment is an inter-linking process. Use of suitable feed additives including growth stimulants, prebiotics, herbal extracts and probiotics in the aquafeeds helps to improve growth performance and immunity is an interesting field in the industry of ornamental fish culture. The positive effect depends on both the action mechanism and the capacity of colonization. Among the protein sources, microbial origin appears to be a promising alteration for fish meal replacing up to 25-30 % (Dharmaraj *et al.*, 2010). The ornamental fish *Puntius conchonius* were

fed with commercial probiotic “Lact-act” histological section of skeletal muscle were taken at the end of 15<sup>th</sup> days and 30<sup>th</sup> days of an experimental period and presented in various Plates. Plate 1a & 1b shows that the section of skeletal muscle of control fish at the end of 15<sup>th</sup> and 30<sup>th</sup> days of an experimental period shows that bundle of skeletal muscle fibres with striated appearance and peripherally placed nucleus (Gopinath and Ramanibai, 2014).

**Plate 1.a. and 1.b shows histological changes in the muscle of control *Puntius conchonius* after 15 days and 30 days of an experimental period.**



**1.a. Section of control fish muscle after 15 days**

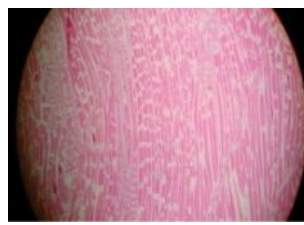


**1.b. Section of control fish muscle after 30 days**

**Plate 2.a. and 2.b shows histological changes in the skeletal muscle of probiotic fed fish *Puntius conchonius* after 15 days and 30 days of an experimental period.**



**2.a. Section of probiotic fed fish muscle after 15 days**



**2.b. Section of probiotic fed fish muscle after 30 days**

Skeletal muscles of probiotic fed fish (Plate 2a & 2b) shows the bundle of skeletal muscle fibres with striated appearance and marked heterotrophy with increased in cytoplasmic size and peripherally placed benign nucleus and no evidence for inflammatory changes. Increased cell proliferation and cytoplasmic size indicates the better growth. It is concluded that commercial probiotics Lact-Act improved the water quality which inturn results in better growth and maintains good health.

## References

1. Abd-El-Rahman, A. M., John, G. and Mohamed, F. M. 2008a. Characterization of some bacteria isolated from *Oreochromis niloticus* and their potential use as probiotics. *Aquaculture*, 277: 1–6.
2. Abraham, T. J. 2008. Antagonistic fish gut bacterium *Lactobacillus* sp. as biocontrol agent in ornamental fish Culture. *Fish Technol.*, 45 (2): (In Press) acid bacteria in the feed on growth and survival of fry of Atlantic cod (*Gadus morhua*). *Hydrobiologia*, 352:279-285.

3. Abraham, T. J., CH. S. Babu, and T. Banerjee. 2007a. Influence of a fish gut bacterium *Lactobacillus* sp. on the production of swordtail *Xiphophorus helleri* (Heckel 1848). Bangladesh J. Fish. Res., 11(1): 65-74.
4. Abraham, T.J., CH. S. Babu, S. Mondal, and T. Banerjee. 2007b. Effects of dietary supplementation of commercial human probiotic and antibiotic on the growth rate and content of intestinal microflora in ornamental fishes. Bangladesh. J Fish. Res., 11(1): 57-63.
5. Cek S., Bromage N., Randall C., Rana K. 2001. Oogenesis, hepatosomatic and gonadosomatic indexes, and sex ratio in rosy barb (*Puntius conchonioides*). Tr. J. F. A. S. 1: 33-41.
6. Cek S., Gokce M.A. 2005. Evaluation of the photocopy method for counting *Puntius Conchonioides* eggs. Turk. J. Vet. Anim. Sci., 29: 685-689. Czech Journal of Animal Sciences 43, 231-235.
7. Culling CFA 1974. Handbook of histopathological techniques. Ed.2, Butterworth, London, U.K.
8. Dharmaraj S. and K. Dhevaran, 2010. "Evaluation of Streptomyces as a probiotic feed for the growth of ornamental fish *Xiphophorus helleri*," Food Technology and Biotechnology, vol. 48, no. 4, pp. 497-504.
9. Dhert, P., Lavens, P. and Sorgeloos, P. 1992. Stress evaluation: a tool for quality control of hatchery-produced shrimp and fish fry. Aquaculture Europe, 17: 6-10.
10. Fuller R. 1992. Probiotics. The Scientific Basis. Chapman & Hall, London, UK, 398pp.
11. Gatesoupe F.J. 1994. Lactic acid bacteria increase the resistance of turbot larvae, *Scophthalmus maximus*, against pathogenic *Vibrio*. Aquatic Living Resources 7, 277-282.
12. Gatesoupe FJ 1999. The use of probiotics in aquaculture. Aquaculture 180:147-165.
13. Ghosh, S., A. Siha and C.Sahu, 2007. Effect of probiotic on reproductive performance in female live bearing ornamental fish. Aquacult. Res., 38:518-526.
14. Ghosh S, Sinha A, Sahu C 2007a. Effect of probiotic on reproductive performance in female live bearing ornamental fish. Aquac Res 38:518-526.
15. Gobinath. J and Ramanibai.R. (2014). Histopathological studies in the gill, liver, kidney of the freshwater fish *Labeo rohita* fingerlings. Inter. J. Inno. Res. Sci. Engi. and Tech., 3(3), 10296-10301.
16. Irianto, A. and Austin, B. 2003. Use of dead probiotic cells to control furunculosis in rainbow trout, *Onchorhynchus mykiss* (Walbaum). J. Fish Dis., 26: 59-62.
17. Izquierdo M.S., Fernandez-Palacios H. & Tacon A.G.J. 2001. Effect of broodstock nutrition on reproductive performance of fish. Aquaculture 197, 25-42.
18. Kozasa, M. 1986. Toyocerin (*Bacillus toyoi*) as growth promoter for animal feeding. Microbiologia Aliments Nutrition 4: 121-125.
19. Parvathi K, Sivakumar P, Vinoth M. Influence of Selected Probiotics on Some Physico-Chemical Parameters of Water. Bonfring. 2013, 394-396.
20. Uma, A., T. J. Abraham, M. J. P. Jeyaseelan, and V. Sundararaj. 1999. Effect of probiotic feed supplement on performance and disease resistance of Indian white shrimp *Penaeus indicus* H. Milne Edwards. J. Aqua. Trop. 14: 159-164.

<b>Access this Article in Online</b>	
	Website: <a href="http://www.ijarbs.com">www.ijarbs.com</a>
<b>Quick Response Code</b>	Subject: <b>Medicinal Plants</b>
DOI: <a href="https://doi.org/10.22192/ijarbs.2017.04.08.025">10.22192/ijarbs.2017.04.08.025</a>	

**How to cite this article:**

S. Kalaimani and K. Parvathi. (2017). The Effect of Commercial Probiotics on Histological changes in the muscle of Ornamental fish *Puntius conchonioides*. Int. J. Adv. Res. Biol. Sci. 4(8): 206-109.

DOI: <http://dx.doi.org/10.22192/ijarbs.2017.04.08.025>