



Anti-Urolithiatic Evaluation of Siddha formulation *Seenakara Parpam* against Zinc Disc Implantation induced Urolithiasis in Wistar Albino Rats

A. Mariappan^{*1}, G.Ganapathy², V.Banumathi³

¹Lecturer, Department of Gunapadam, National Institute of Siddha, Tambaram Sanatorium, Chennai 600047, Tamilnadu, India

²Professor, Former HOD, National Institute of Siddha, Tambaram Sanatorium, Chennai 600047, Tamilnadu, India

³Director, National Institute Of Siddha, Tambaram Sanatorium, Chennai 600047, Tamilnadu, India

Corresponding Author: **Dr. A.Mariappan M.D(S)**

Corresponding Address: Department of Gunapadam, National Institute of Siddha, Tambaram Sanatorium, Chennai 600047, Tamilnadu, India. E-mail: mariappannis@gmail.com

Telephone: 9894690733

Abstract

Urolithiasis is one such disease that after extensive research in the field of urology has remained incurable in allopathy. It is a process of stone formation which occurs either in the kidney (commonly known as nephrolithiasis) and or in any part of the urinary tract, including the ureters (known as ureteral stone) and bladder (bladder stone). Urolithiasis has an important effect on the health care system with a prevalence of >10% and an expected recurrence rate of ~50%. Siddha system of medicine is a source of treatment for many ailments. Some medicinal plants and proprietary composite herbal preparations are reported to be effective in the treatment as well as prevention of recurrence of renal calculi with minimal side effects. In Indian indigenous system of medicine, several formulations including *Seenakara parpam* (SKP) are claimed to be useful for the renal calculi but needs scientific documentation. The present investigation was aimed at evaluating the anti-urolithiatic activity of *Seenakara parpam* (SKP) on zinc disc implantation induced experimental urolithiasis on wistar albino rats. Implantation was carried out by a surgical procedure followed by the recovery period of three days. Soon after recovery animals were treated with SKP at the dose of 200 and 400 mg/kg b.wt, p.o. Animals belonging to standard group received cystone 500 mg/kg, p.o. for a period of 7 days. Parameters such as urine volume, urinary calcium output and calculi weight were measured at the end of the study. Treatment with SKP and cystone significantly reduced the excretion of calcium further the volume of urine output increased in treatment group when compared to that of the disc implanted group rats. Weight of the calculi is considered to be one of the important parameter in evaluating the efficacy of the drug. The results of the study clearly reflects that treatment with SKP at the dose of 200 and 400 mg/kg and standard drug cystone 500 mg/kg shown significant decrease in the weight of calculi from 113.5 mg to 10.5 mg. In conclusion formulations like SKP may be considered as a potential lead for the clinical management of urolithiasis.

Keywords: *Seenakara parpam*, zinc disc, urolithiasis, cystone, urine volume, calcium output, calculi weight.

Introduction

Urolithiasis is the third prevalent disorder of the urinary system that is approximately 2–3% in the general population. Urinary calculi, if untreated, may cause serious medical consequences such as extreme obstruction, hydronephrosis, infection, and hemorrhage in the urinary tract system [1]. Surgical operation, lithotripsy, and local calculus disruption using high-power laser are commonly used techniques to remove the calculi. However, these procedures are associated with the risk of acute renal injury leading to decrease in renal function. Moreover, an increase in stone recurrence is also observed [2]. The recurrence rate without preventive treatment is approximately 10% at 1st year, 33% at 5th year, and 50% at 10th year indicating the need to develop suitable alternative therapy [3-6].

The worldwide incidence of urolithiasis is quite high, and more than 80% of urinary calculi are calcium oxalate (CaOx) stones alone or CaOx mixed with calcium phosphate. Epidemiological studies revealed that the nephrolithiasis is more prevalent in men (12%) than in women (6%) and is more prevalent between the ages of 20–40 in both sexes [7].

Urinary supersaturation of various stone-forming elements is commonly considered to be one of the causative factors in the stone formation [8]. Renal calcium oxalate (CaOx) crystal deposition induced by ethylene glycol is the most appropriate animal model that is frequently used to mimic the stone formation in humans. Previously reported studies showed that after the 28 days period of ethylene glycol (0.75% v/v) administration in the drinking water of laboratory animals significantly cause renal stone formation that mainly consist CaOx by increasing the urinary concentration of oxalate [9-13].

In the traditional systems like Siddha medicine, most of the remedies were formulated from plants and minerals that were proved to be useful in various disease conditions. Noteworthy, traditional Siddha medicines are efficacious and have lesser side effects compared to chemical drugs and also reduce the recurrence rate of the renal stone. The vast literature indicate a number of formulations to be useful in the treatment of urinary stones. Many formulations need to be explored for their pharmacological actions [14].

In the indigenous system of medicine, the *Seenakara Parpam* (SKP) is reported to be useful in the treatment of urinary stones. However, so far no systematic study

has been reported with respect to the anti-urolithiatic property of SKP. Hence the main aim of the present study is to evaluate the anti-urolithiatic property of SKP using zinc disc implantation induced experimental model of urolithiasis.

Materials and Methods

Evaluation of Anti-urolithiatic activity by zinc disc implantation induced urolithiasis in rats

Animals

Healthy adult albino wistar male rats weighing between 200-220gm were used for the study. The animals were housed in poly propylene cages and were kept in well ventilated with 100 % fresh air by air conditioning. A 12h light/dark cycle was maintained. Room temperature was maintained between 22±2 °C and relative humidity 40–65%. They were provided with food and water *ad libitum*. All the animals were acclimatized to the laboratory about 7 days prior to experimentation.

Experimental Protocol

Before day of implantation Zinc disc were prepared having weight 20±2 mg. Prior to surgery, rats were fasted for 8–10 hours. Just before anesthesia, they were orally administered with 4mL of water to dilate their urinary bladders. Zinc disc implantations in urinary bladders were carried out by an earlier reported method by Vermeulen et al [15]. The rats were operated in sterile conditions under Ketamine (80mg/kg/i.p.) and diazepam (4mg/kg/i.m.) anesthesia. The urinary bladders were exposed through a suprapubic incision and a small cut was taken to open the lumen of the bladder. In zinc disc implanted groups, discs of average weight of 20 ± 2 mg were inserted and the incision was closed by 1 or 2 stitches of absorbable sterile surgical sutures (Centennial CNW 2670 6-0 USP). The abdominal incisions were sutured with sterile silk suture. The rats in sham operated groups were similarly operated except implantation of zinc disc in the bladder [16].

All the operated rats were treated topically with antibiotic dusting powder and allowed to recover for three days without any interventions. Treatment was started after the three days of recovery [17]. Rats were divided into six groups of six animals each as normal control group, sham operated group (the same surgical procedure but without implantation of zinc disc), zinc disc implanted group, zinc disc implanted group after

recovery treated with Cystone 500mg/kg/day for seven days, Similarly zinc disc implanted rats treated with SKP at the dose of 200 and 400 mg/kg, p.o for seven days.

Grouping

- Group I: Control group rats received normal saline
- Group II: Sham operated group without implantation
- Group III: Disease control group surgically implanted with zinc disc.
- Group IV: Implanted with zinc disc and treated with cystone 500 mg/kg, p.o
- Group V: Implanted with zinc disc and treated with SKP at 200 mg/kg, p.o
- Group VI: Implanted with zinc disc and treated with SKP at 400 mg/kg, p.o

Urine Collection

At the end of the treatment period, individual animal was placed in the metabolic cage for collection of 24-hour urine samples. Initially a drop of chlorhexidine gluconate was added to the test tubes as a preservative.

Radio Graphic Examination

Radio graphic examination was done before sacrificing the animals to confirm the formation of stones. The animals were kept under light ether anaesthesia in anteroposterior position on the X-ray board to expose the pelvic region, with digital X-ray instrument (GE-525DX, USA) by Fuji computerized radiographic system Japan. The film focus distance was 60 inches and machine was operated at 43 kV peak, 2mA [19].

Calculi Weight

The weight of urinary calculi determined by sacrificing the animals at the end of study. The urinary bladders were exposed and zinc disc along with the adhered crystals was removed and wrapped in separated polyethylene bags.

Results

Effect of Seenakara Parpam on Urine volume, Calcium and Calculi weight.

Zinc discs were implanted in the urinary bladder of experimental rats. The zinc discs initiate and fasten the nucleation process which is the rate limiting step in the formation of urinary calculi. It was observed that there was a significant decrease in urine volume of rats belongs to zinc disc implanted group (1.5 ± 0.1 ml) when compared to normal control (2.6 ± 0.2 ml). Treatment with SKP at both the dose shown significant increase in urine volume of about 2.3 ml in 200mg/kg treated group and 2.4 ml in 400mg/kg treated rats. Similar type of results were observed in standard drug cystone 500 mg/kg treated group (2.5 ± 0.2 ml). Rats treated with SKP showed dose dependent increase in urine output.

Urolithiatic animals showed increase urinary calcium excretion of about (23.8 ± 4.6 mg/dL). Treatment with SKP at both the dose had shown significant decrease in calcium excretion of about 11.6 ± 3.1 mg/dl in 200mg/kg treated group and 10.2 ± 2.5 mg/dl in 400mg/kg treated rats. Similar type of results were observed in standard drug cystone 500 mg/kg treated group (12.3 ± 3.9 mg/dl). Rats treated with SKP showed dose dependent increase in urine output.

At the end of the study all the experimental animals were sacrificed with excess dose of pentobarbitone and the zinc discs were removed and weighed. The average weight of zinc discs along with the deposited crystals in the only disc implanted group without any treatment was found to be 113.55 ± 7.90 mg. Group that received Cystone 500 mg/kg, showed significant reduction in the depositions hence there was significant difference in the weight of bladder content as compared to zinc disc implanted group ($P < 0.001$). Similarly, the rats treated with SKP 200mg/kg/day, and 400mg/kg/day showed reduced formation of depositions around the zinc disc ($P < 0.001$) and the corresponding results were tabulated in Table 1.

Table 1: **Effect of Seenakara Parpam on Urine volume, Calcium and Calculi weight.**

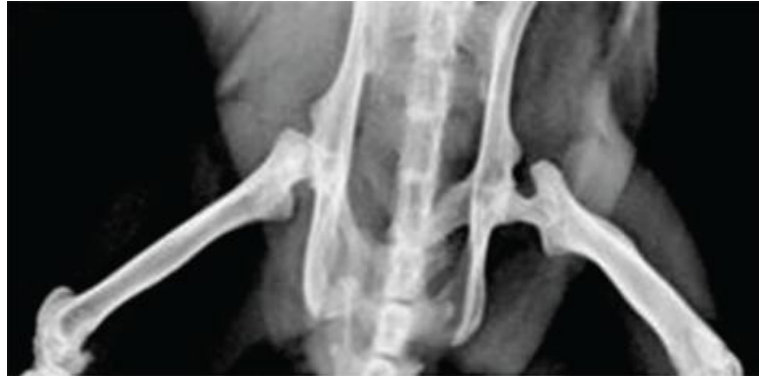Groups	Urine output	Urinary calcium output	Weight of calculi (mg)
Normal control	2.6 ± 0.2	-	-
Sham control	2.2 ± 0.1	$10.4 \pm 2.5^{**}$	-
Disc implanted control	$1.5 \pm 0.1^*$	23.8 ± 4.6	113.55 ± 7.90
Cystone 500mg/kg	2.5 ± 0.2	$12.3 \pm 3.9^{**}$	$6.90 \pm 1.95^{***}$
SKP 200mg/kg	2.3 ± 0.2	$11.6 \pm 3.1^{**}$	$11.6 \pm 2.35^{***}$
SKP 400mg/kg	2.4 ± 0.2	$10.2 \pm 2.5^{**}$	$10.5 \pm 1.93^{***}$

Value represents; mean \pm SEM. Statistical analysis was performed by Newman-keuls multiple range tests. $*P < 0.05$, as compared with naive control, $**P < 0.01$, and $***P < 0.001$ as compared with disc implanted group.

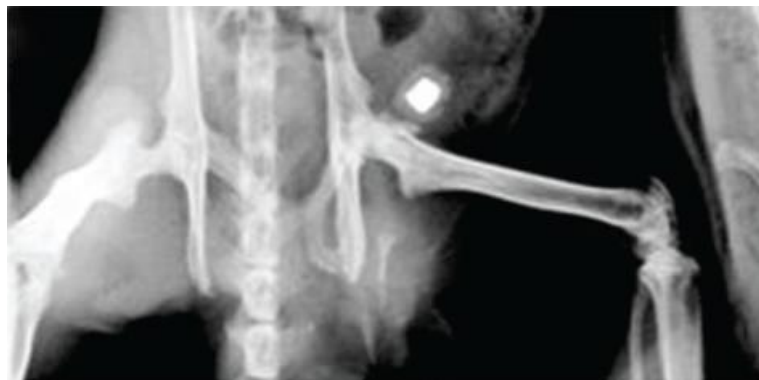The X-ray images of rats revealed presence of deposits around the implanted zinc disc within 10 days after implantation. Treatment with SKP at both the dose level and Cystone at dose of 500mg/kg/day shown significantly reduction in the formation of such deposits within 10 days. These observations were

confirmed in actual weights of the bladder contents. As shown in Figure 1 (A-E).

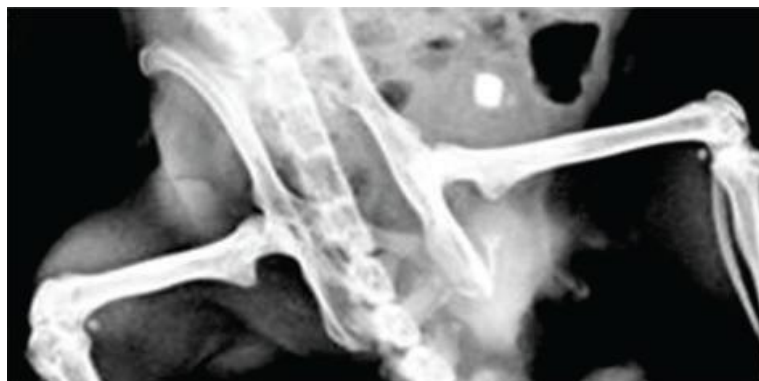
Figure 1 shows the results of effects of Seenakara Parpam on zinc disc implantation model of urolithiasis.



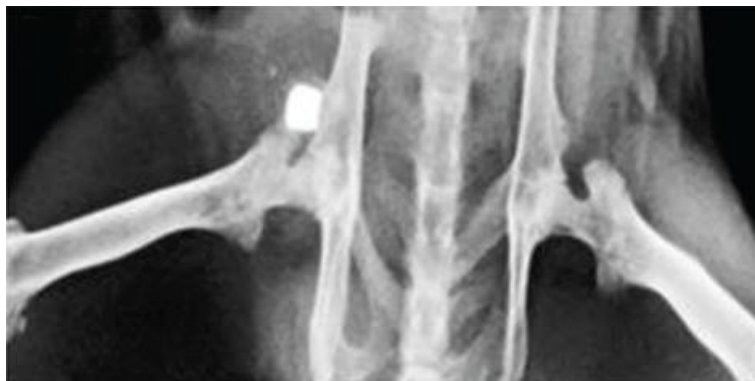A. Sham operated group without implantation



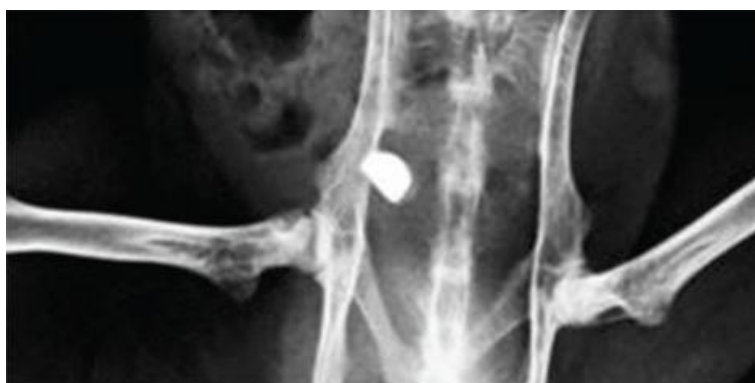B. Disease control group surgically implanted with zinc disc



C. Implanted with zinc disc and treated with cystone 500 mg/kg



D. Implanted with zinc disc and treated with SKP 200 mg/kg



E. Implanted with zinc disc and treated with SKP 400 mg/kg

Figure 1: X-ray of image of rats in zinc disc implantation model of urolithiasis. (a) Sham operated (b) Zinc disc implanted, (c) Cystone treated, (d) SKP 200mg/kg, (e) SKP400mg/kg,

Discussion

Renal calculi can be experimentally induced by either administration of various chemicals such as sodium oxalate or surgical implantation of foreign material like zinc disc in the urinary bladder of rats. The chemically-induced calculi model associated with high incidence of nephrotoxicity, metabolic acidosis, and occurrence of calculi in the renal cortex that is situation opposite to that found in human urolithiasis[20]. However, zinc disc model induces renal calculi with minimal renal damage and mimic the etiology of urinary stone formation in humans [21]. Therefore, zinc disc implantation-induced urolithiasis model was selected to induce urolithiasis in rats. In this model, the implanted zinc disc act as a nidus that subsequently leads to deposition of a urolith minerals composed of magnesium ammonium phosphate around the disc [22].

Hyperoxaluria and hypercalciuria are important risk factors in the pathogenesis of urinary stone formation. In zinc disc implantation model, the urine output was decreased in disc implanted group as compared to

naive control group. This suggests obstruction of urinary bladder due to formation of large urinary calculi. Partial obstruction of the urinary bladder outlet leads to a compensatory growth of the detrusor smooth muscle cells, and this occurs as a feedback response to the increased intravesical pressure required to empty the bladder. Partial obstruction of the urinary bladder was also shown to induce a decrease in the density of autonomic innervation and sensitivity to the muscarinic agonist. In fact, increase of diuresis could reduce super saturation of the urine with precipitating substances which is normally associated with formation of urinary calculi [23].

Urine output was decreased in disc implanted group [24]. This suggests obstruction of urinary bladder due to the formation of urinary calculi. In the present investigation, treatment with SKP at the dose of 200, 400mg/kg and the standard drug cystone at the dose of 500 mg/kg significantly increased urine output, and this may be due to prevention of stone formation or their direct diuretic effect which reduced super saturation of urine with precipitating substances and thereby stone formation.

The increase in urine output by SKP might be *via* activation of muscarinic receptor in the bladder muscles along with other unrevealed mechanisms. On the 10th day of post implantation, there was a significant increase in the urine calcium observed in disc implanted animals [11]. Urinary calcium is a factor that favours the process of nucleation and precipitation of calcium oxalate or apatite (calcium phosphate) from urine and subsequent crystal growth. Treatments with Cystone significantly reduced the increased calcium output. Similarly type SKP also reduced such increased calcium output in dose dependent manner. Treatment with SKP was found to inhibit the formation of calculi which are mainly composed of magnesium ammonium phosphate. Treatment with Cystone (500mg/kg) also has similar effects. Cystone has already been proved by Mitra et al to possess Antiurolithiatic action; in our study we found that SKP has potent Antiurolithiatic action at comparatively very low dose range as compared to Cystone.

The formation of calculus in urinary bladder was also confirmed by X-ray (radiological) investigation. Drugs treatment shows only zinc disc in radiographic studies. Digital X-ray radiography provides a means to easily monitor the crystal growth. As evident in this study, within 10 days after implantation, depositions could be visualized around the implants. Hence, use of this technique can help the investigator to determine the time at which study is to be terminated. Thus our data indicates that while evaluating an Antiurolithiatic drug by zinc disc implantation model, X-ray radiography was used to monitor the growth of deposit around the implants and as soon as sufficient deposition was revealed in control groups, the study was terminated so as to minimize undue stress to the animals. Recently, instead of zinc disc other foreign bodies which can be easily processed for evaluation have been suggested to be implanted in the bladder.

From the results of the present investigation it was concluded that the administration of SKP at both the dose level showed significant Anti-urolithiatic activity as indicated by increased urine output and related parameters. The exact mechanism of action is not established but attributed that SKP might act through activation of muscarinic receptor in the bladder muscles. Future studies needs to be carried out in order to explore the exact mechanism of action of SKP.

Various chemical constituents interacting toward synergism. The possible mechanism underlying this effect is mediated collectively through diuretic,

antioxidant and anti-inflammatory effects of the drug. Further chemical analysis is required to establish the exact mechanism of action.

Acknowledgments

I wish to acknowledge and thank the The Tamilnadu Dr.M.G.R Medical university, Chennai, The National Institute of Siddha, Chennai, KM College of Pharmacy Madurai for their technical support for this research work.

References

1. Hadjzadeh MA, Khoei A, Hadjzadeh Z, Parizady M. Ethanolic extract of *Nigella sativa* L seeds on ethylene glycol-induced kidney calculi in rats. *Urol J.* 2007; 4:86–90.
2. Begun FP, Knoll CE, Gottlieb M, Lawson RK. Chronic effects of focused electrohydraulic shock waves on renal function and hypertension. *J Urol.* 1991; 145:635–9.
3. Basavaraj DR, Biyani CS, Browning AJ, Cartledge JJ. The role of urinary kidney stone inhibitors and promoters in the pathogenesis of calcium containing renal stones. *EAU-EBU Update Ser.* 2007; 5:126–36.
4. Prasad KV, Sujatha D, Bharathi K. Herbal drugs in urolithiasis – A review. *Pharmacogn Rev.* 2007; 1:175–9.
5. Warriar PK, Nambiar VP, Ramankutty C. Chennai, India: Orient Longman Publishers; 1994. *Indian Medicinal Plants – A Compendium of 500 Species*; pp. 271–3.
6. Kirtikar KR, Basu BD. Dehradun, India: International Book Distributor; 2005. *Indian Medicinal Plants*; pp. 440–1.
7. Worcester E.M., Coe F.L. Nephrolithiasis. *Prim Care.* 2008; 35:369–391.
- 8.26. Worcester E.M., Coe F.L. Clinical practice. Calcium kidney stones. *N Engl J Med.* 2010; 363:954–963.
9. Selvam R., Kalaiselvi P., Govindaraj A., BalaMurugan V., Sathish Kumar A.S. Effect of *A. lanata* leaf extract and vediuppu chunnam on the urinary risk factors of calcium oxalate urolithiasis during experimental hyperoxaluria. *Pharmacol Res.* 2001; 43:89–93.
10. Huang H.S., Ma M.C., Chen J., Chen C.F. Changes in the oxidant-antioxidant balance in the kidney of rats with nephrolithiasis induced by ethylene glycol. *J Urol.* 2002; 167:2584–2593.

11. Atmani F., Slimani Y., Mimouni M., Hacht B. Prophylaxis of calcium oxalate stones by *Herniariahirsuta* on experimentally induced nephrolithiasis in rats. *BJU Int.* 2003; 92:137–140.
12. Divakar K., Pawar A.T., Chandrasekhar S.B., Dighe S.B., Divakar G. Protective effect of the hydro-alcoholic extract of *Rubia cordifolia* roots against ethylene glycol induced urolithiasis in rats. *Food Chem Toxicol.* 2010; 48:1013–1018.
13. Saha S., Verma R.J. Antinephrolithiatic and Antioxidative efficacy of *Dolichos biflorus* seeds in a lithiasic rat model. *Pharm Biol.* 2015; 53:16–30.
14. Butterweck V., Khan S.R. Herbal medicines in the management of urolithiasis: alternative or complementary? *Planta Med.* 2009; 75:1095–1103.
15. Vermeulen CW, Grove WJ, Goetz R, Ragins HD. Experimental urolithiasis. I. Development of calculi upon foreign bodies surgically introduced into bladders of rats,” *The Journal of Urology.* 1950; 64:541–548.
16. Araujo Viel T, Diogo Domingos C, Da Silva Monteiro. Evaluation of the Antiurolithiatic activity of the extract of *Costus spiralis* Roscoe in rats. *Journal of Ethnopharmacology.* 1999; 66: 193–198.
17. Malini MM, Lenin M, Varalakshmi P. Protective effect of triterpenes on calcium oxalate crystal-induced peroxidative changes in experimental urolithiasis. *Pharmacological Research.* 2000; 41: 413–418.
18. Mitra SK, Gopumadhavan S, Venkataranganna MV. Effect of Cystone, a herbal formulation on glycollic acid induced urolithiasis in rats. *Phytotherapy Research.* 1998; 12: 372–374.
19. Vargas R, Perez RM, Perez S. Antirolithiatic activity of *Raphanussativus* aqueous extract on rats. *Journal of Ethnopharmacology.* 1999; 68:335–338.
20. Hwisa NT, Assaleh FH, Gindi S, Melad FE, Chandu BR, Katakam P. A study. A study on Antirolithiatic activity of *Melia azadirachta* L. aqueous extract in rats. *Am J Pharmacol Sci.* 2014; 2:27–31.
21. Khan SR. Animal models of kidney stone formation: An analysis. *World J Urol.* 1997; 15:236–43.
22. Yamaguchi S, Wiessner JH, Hasegawa AT, Hung LY, Mandel GS, Mandel NS. Study of Study of a rat model for calcium oxalate crystal formation without severe renal damage in selected conditions. *Int J Urol.* 2005; 12:290–8.
23. Fleisch H. Inhibitors and promoters of stone formation. *Kidney International.* 1978; 13: 361–371.
24. Vyas N, Argal A. Antirolithiatic activity of extract and oleanolic acid isolated from the roots of *Lantana camara* on zinc disc implantation induced urolithiasis. *ISRN Pharmacol* 2013; 95:91–95.
25. Lemann J, Worcester EM, Gray RW. Hypercalciuria and stones. *American Journal of Kidney Diseases.* 1991; 17:386–391.

Access this Article in Online	
	Website: www.ijarbs.com
	Subject: Medicinal Plants
Quick Response Code	
DOI: 10.22192/ijarbs.2016.03.12.002	

How to cite this article:

A. Mariappan, G.Ganapathy, V.Banumathi. (2016). Anti-Urolithiatic Evaluation of Siddha formulation *Seenakara Parpam* against Zinc Disc Implantation induced Urolithiasis in Wistar Albino Rats. *Int. J. Adv. Res. Biol. Sci.* 3(12): 7-13.

DOI: <http://dx.doi.org/10.22192/ijarbs.2016.03.12.002>