



Hepato therapeutic Efficacy of Native Curcumim and Nano –curcumin : A Novel Therapy Against Hyperthyroidism Induced Liver Oxidative and Inflammatory Damage in Rats

Widad M. Al-Bishri

Department of Biochemistry, Faculty of Science, Al Faisaliah, King Abdulaziz University, Saudi Arabia.

Corresponding author: **Widad M. Al-Bishri**

E-mail: walbishry@kau.edu.sa

Abstract

Recent works have indicated the beneficial efficacy of using nanocurcumin in addressing poor bioavailability commonly associated with native curcumin. Curcumin has been shown to alleviate hyperthyroidism induced liver dysfunction. Here we carried out a comparative study using both native curcumin and nanocurcumin to verify the superior effects of encapsulation of curcumin in nanomaterials in blunting liver dysfunction in L-thyroxine induced hyperthyroid rats. Native curcumin (NC) and poly (lactide-co-glycolic acid (PLGA) encapsulated curcumin (PNC) significantly increased liver catalase activity and reduced glutathione (GSH) levels and significantly declined malondialdehyde (MDA) levels in hyperthyroid rats. However, rats treated with PNC had significantly better ameliorative effects on these parameters than rats treated with NC. Similarly, PNC showed significantly improved effects in lowering inflammatory mediators including TNF-a, IL-6, VEGF, CRP and caspase protein levels compared to NC in hyperthyroid rats. Serum T3, T4, and TSH levels and liver functional markers including albumin, ALT, ASP and AST were better controlled in PNC treated rats than in NC treated hyperthyroid rats. DNA fragmentation as estimated by comet assay was significantly lower in PNC treated rats than in NC treated rats. Likewise, significantly fewer histopathological and ultrastructural changes were observed in liver tissue in PNC treated hyperthyroid rats. Conclusion: Our work illustrates the capability of PNC to resolve hyperthyroidism induced liver dysfunction and substantiate the findings that beneficial effects of curcumin may be maximized by improving its stability and bioavailability by its encapsulation in nanoparticles.

Keywords: Curcumin , nanocurcumin, hyperthyroid, inflammatory mediators, liver

Introduction

Curcumin is known to humans for centuries for its multiple health benefits. Curcumin longa, commonly referred as turmeric, is used widespread as an essential spice in food preparations mainly due to its medicinal properties. Curcumin exhibits a number of medicinal properties including anti-diabetic [1], anti-arthritic [2], anti-oxidant [3], anti-inflammatory [4], anti-microbial [5], anti-neurodegenerative [6] and anti-cancer [7]. Despite the widespread applications,

the beneficial effects of curcumin are hampered by its poor bioavailability which results from its high metabolic and excretion rates, poor absorption and minimal water insolubility [8]. To circumvent these obstacles, some studies have focused attention on the utilization of nanomaterials to encapsulate curcumin to enhance its bioavailability. For example, nanocurcumin has been shown to be superior to curcumin in preventing degenerative changes in

experimental cerebral malaria[9]. Nanocurcumin was found to be more effective in its antiproliferative properties compared to native curcumin in MDA breast cancer cell lines[10]. Likewise, compared to native curcumin, curcumin nanoparticles exhibited stronger inhibitory properties against cell proliferation in lung A549, liver HepG2 and skin A431 cells[11]. PLGA nanoparticles encapsulating curcumin and amyloid-beta generating inhibitor attenuated memory deficit and neuropathology in a mice model[6].

Hyperthyroidism is characterized by overproduction of thyroxine hormone. Thyroid and liver are functionally related and any perturbations in either of the organs affects the other. Accordingly, liver dysfunction is a common consequence of hyperthyroidism[12]. Previous studies have shown the favourable effects of curcumin on liver function. Curcumin has been shown to augment antioxidant enzymes in liver of L-thyroxine induced hyperthyroid rats[13]. Curcumin also alleviated oxidative injury in liver mitochondria of hyperthyroidism rats [14]. However, a comparison study examining the relative efficacy of native curcumin and nanoparticle encapsulated curcumin on hyperthyroidism caused liver dysfunction has not been carried out. In this study, we employed PLGA encapsulated curcumin to understand its attenuating effects on oxidative stress, inflammation, DNA damage and liver function

Materials and Methods

Preparation of Nanocurcumin

The preparation of curcumin-loaded nanoparticles was carried out using solid-in-oil-in-water (s/o/w) emulsion technique. Briefly, 45 mg of PLGA was dissolved in dichloromethane for six hours resulting in a uniform PLGA solution. In order to obtain the solid-in-oil primary emulsion, normal curcumin was added to PLGA solution followed by sonication for 1 minute at 55W. Twenty ml of polyvinyl alcohol (1% w/v) was mixed with the primary emulsion and further sonicated for 2 minutes at 55W resulting into final solid-in-oil-in-water emulsion. The nano-scaled particles in emulsion were evaporated and centrifuged at 15000g to remove the solvent. The Nano-particles were washed with deionized water and then dried utilizing a lyophilizer and kept at 4 °C. Particle size of nanoparticles were determined by transmission electron microscope at a magnification of 80 Kv.

Animals

Forty male Wister rats each weighing 180-200g, were bought from the Animal house at Experimental Animal Care Center, King Fahad Medical Research Center, King Abdulaziz University, Jeddah, Saudi Arabia. The animals were maintained in ambient conditions and had access to free diet and water. The handling of the rats was done following with the guidelines provided by the Experimental Animal Laboratory with the approval from the Animal Care and Use Committee of the King Abdulaziz University, Faculty of Science. Rats were classified into 4 groups (ten rats each), namely control (C), hyperthyroid (HT), native curcumin (NC) and PLGA-nanocurcumin (PNC) groups.

Induction of Hyperthyroidism and treatments

Hyperthyroidism (HT) in the rats was promoted by subcutaneous injection of L-thyroxine 4 (LT4, 0.3 mg/kg body weight) for 12 consecutive days. From day 13, rats in NC groups were ingested orally native curcumin (100 mg/kg body weight) for 21 days along with LT4 (0.3 mg/kg body weight), whereas rats in PNC group were treated with nano-curcumin (100 mg/kg body weight) for 21 days along with TL4. Rats in HT group continuously received 0.3 mg dose of TL4 for 21 days. Rats in C group were not subjected to any treatments.

After 21 days all the rats were starved overnight and the blood specimens were gathered. Rats were anaesthetized by pentobarbital, sacrificed and then Liver specimens were removed. Parts of liver specimens were fixed in 10% formalin for histopathological observation and in 3% buffered glutaraldehyde for ultrastructural studies, while immediately frozen for biochemical analysis.

Thyroid and liver functional markers

The thyroid functional markers including T3 and T4 and TSH and the liver functional markers including aspartate aminotransferase (AST), alanine aminotransferase (ALT), and alkaline phosphatase (ALP) and albumin were estimated using automated biochemical analyzer (ci16200, Abbott, USA).

Serum Inflammatory mediators

The C-reactive protein (CRP) was estimated utilizing latex-enhanced immunonephelometry placed on Behring BN II Nephelometer (Dade Behring). Cytokines including IL-6 and TNF- concentrations were estimated by ELISA assays following the instructions provided by Manufacturer.

Determination of liver oxidative stress and antioxidant biomarkers:

The malondialdehyde (MDA) was measured based on the thiobarbituric acid reactive substances (TBARS) formation as previously described[15], whereas GSH will be estimated by the method of[16]. Catalase activity will be determined by the procedure described by[17] involving the decomposition of hydrogen peroxide.

Determination of liver Oxidative DNA Damage by Comet Assay:

Comet assay was carried out as detailed by[18], Briefly, 15 μ L tissue suspension was mixed with 90 μ L of low melting point agarose (0.5%) and layered on frosted plain glass slide, precoated with normal agarose (1%) followed by another 100 μ L layer of agarose of low melting point. Solidified slides were immersed in lysis solution (10 mM Tris, 100 mM Na₂EDTA, 2.5 M NaCl, pH 10, with 1% Triton X-100 and 10% dimethyl sulfoxide) for 14 h at 4°C. Alkaline electrophoresis buffer (1 mM Na₂EDTA, 300 mM NaOH and 0.2% dimethylsulfoxide, pH 13.5) was added to the slides placed in horizontal gel electrophoresis unit and left for 30 minutes at 4°C for DNA to unwind and for conversion of alkali-labile sites to single strand breaks. Electrophoresis was carried out in the same solution at 4°C for 25 minutes. Slides were neutralized in 0.4 M Tris buffer (pH 7.5) and stained in 20 μ g/mL of ethidium bromide solution. Slides were analyzed by fluorescence based image analyzer (DMLB, Leica)

The DNA damage was assessed by quantitating the percent tail DNA (% tail DNA = 100% head DNA) and olive tail movement using the software.

Histopathological and Ultrastructural Studies

Liver sections measuring 4–5 μ m cut and stained with eosin and hematoxylin stains, and examined under

light microscope for histological changes. Ultrastructural changes in the liver tissue were measured by Transmission Electron Microscope (TEM). Liver tissue specimens were postfixed in 1 % osmium tetroxide (OsO₄) and dehydrated by ascending grades of ethanol.

Impregnation and embedding of specimen were done in pure resin. Ultrathin sections of 60–70 nm were cut on an ultramicrotome with a diamond knife and stained with uranyl acetate and lead citrate. Stained sections were visualized under TEM (JEOLJEM-1011)

Statistical Analysis:

Values were statistically analyzed utilizing SPSS software. Results were calculated as mean \pm SE. Significance variations between values were carried out utilizing one-way analysis of variance (ANOVA) followed by Bonferroni's test post-ANOVA.

Results

Effects of NC and PNC on liver oxidative stress markers

To check the comparative abilities of NC and PNC to suppress hyperthyroidism induced oxidative stress, catalase activity, MDA and GSH levels were measured. The data on the levels of these markers are illustrated in Figure 1. In relation with control, hyperthyroid animals showed significantly reduced catalase activity and GSH levels and significantly increased MDA levels. On the other hand hyperthyroid rats treated with NC and PNC demonstrated a significant increment in catalase and GSH with a depletion in MDA levels compared to those in untreated hyperthyroid rats. Importantly, the catalase activity and GSH levels were markedly higher and MDA levels were markedly lower in PNC ingested hyperthyroid rats than in NC treated hyperthyroid rats demonstrating an improved ability of PNC over NC in suppressing oxidative stress.

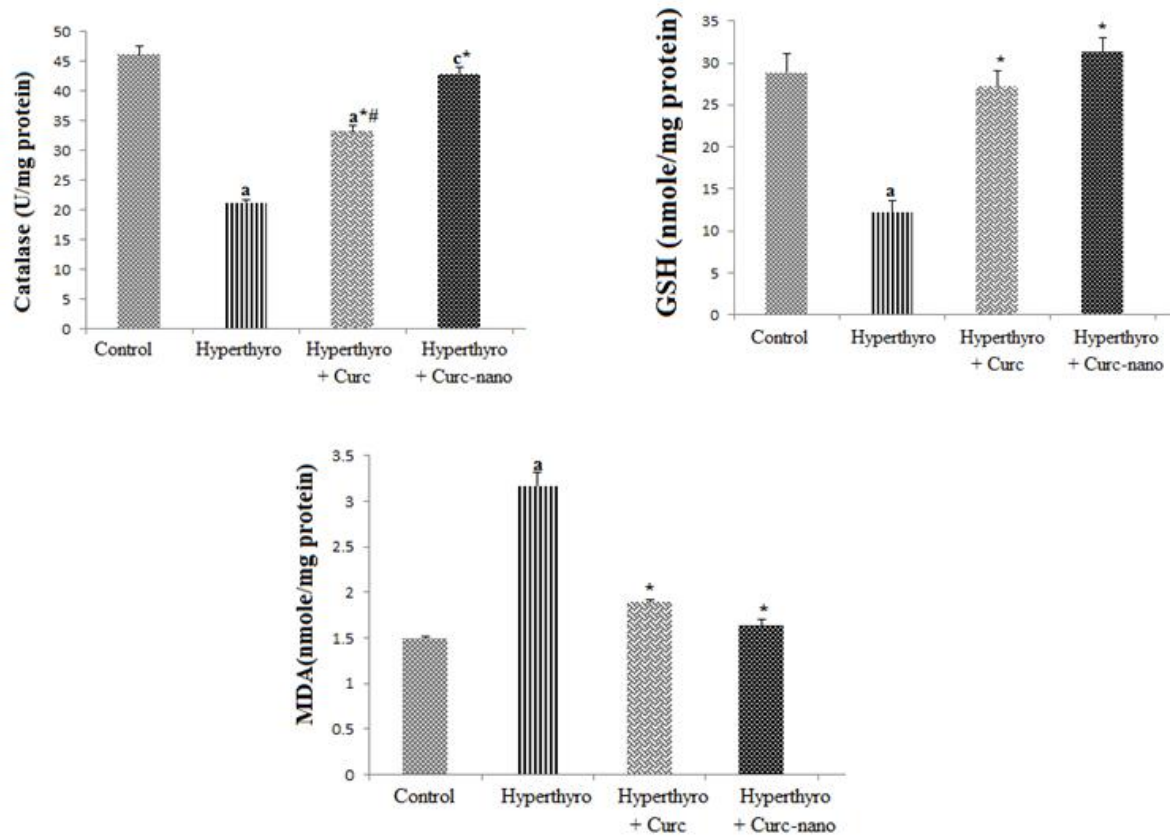


Fig 1: Effect of curcumin (Curc) and nano-curcumin (Curc-nano) on liver antioxidant markers (catalase and GSH) and oxidative stress marker (MDA) in hyperthyroidism (Hyperthyro) rat groups. Data are expressed as mean \pm S.E. from 10 rats, ^a $P < 0.001$, ^c $P < 0.05$ compared with the control group, ^{*} $P < 0.001$ compared with hyperthyroidism group, [#] $P < 0.01$ versus nano-curcumin group.

Effects of NC and PNC on serum inflammatory markers

Effects of NC and PNC on inflammatory indices, CRP, IL-6 and TNF- α , were determined to compare the anti-inflammatory potentials between NC and PNC against hyperthyroidism induced inflammation. The data on levels of CRP, IL-6 and TNF- α in hyperthyroid, PNC and NC treated rats are provided in

Figure 2. Hyperthyroid rats exhibited a significant increase in CRP, IL-6 and TNF- α levels as compared to normal control. Treatment of hyperthyroid rats with NC and PNC resulted in significant depletion in these inflammatory markers. Antiinflammatory potential of PNC was found to be higher than that of NC as shown by significant depletion in inflammatory markers in PNC treated rats than in NC treated rats.

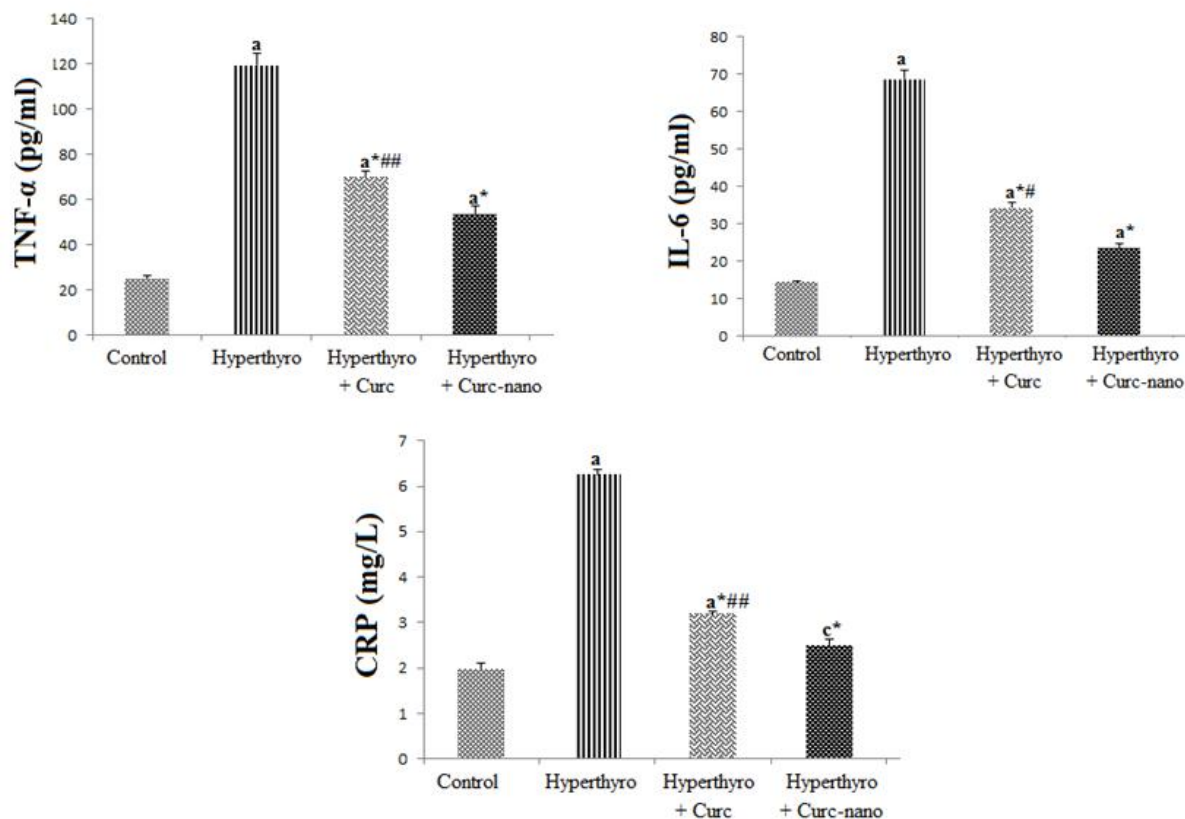


Fig 2 : Effect of Curcumin (Curc) and nano-curcumin (Curc-nano) on serum inflammatory markers (TNF- α , IL-6 and CRP) in hyperthyroidism (Hyperthyro) rat groups. Data are expressed as mean \pm S.E. from 10 rats, ^a $P < 0.001$, ^c $P \leq 0.05$ compared with control group, ^{*} $P \leq 0.001$ compared with hyperthyroidism group, [#] $P \leq 0.01$, ^{##} $P \leq 0.05$ versus nano-curcumin group.

Effects of NC and PNC on DNA damage

To assess the relative effects of NC and PNC in attenuating the hyperthyroidism caused DNA fragmentation, DNA was analyzed utilizing comet assay. The DNA tail formation and olive tail moments in hyperthyroidism, NC and PNC treated rats are presented in Table 1 and Figure 3. The data on the range of the DNA fragmentation was evaluated by estimating the percentage of DNA tail and olive tail moment. Percent DNA tail and olive tail moment were recorded. Hyperthyroidism significantly induced DNA damage as evident from the increased DNA tail percentage and olive tail moment. In contrast treatment with NC and PNC attenuated DNA damage

in hyperthyroid rats as there were significant decreases in percent of DNA tails and olive tail moments. Caspase 3 is a member of caspase family of proteins and its expression is correlated with the DNA damage. In the current demonstration, there was a significant elevation in caspase 3 in hyperthyroid rats signaling increased DNA damage (Figure 4). The treatment with NC and PNC markedly decreased caspase-3 levels in the hyperthyroid rats. The DNA tail percentage, olive tail moments and caspase-3 levels were found to be significantly truncated in hyperthyroid rats that were treated with PNC compared to those in NC treated hyperthyroid rats suggesting the increased protection against DNA damage with PNC than with NC.

Table 1. Effects of curcumin and nanocurcumin on liver DNA damage of hyperthyroid rats

Parameters	C	HT	NC	PNC
DNA tail %	0.54±0.003	26.66±1.32 ^a	10.78±0.66 ^{a*#}	4.85±.31 ^{a*}
Olive tail moment	0.25±0.02	10.70±0.66 ^a	4.97±0.24 ^{a*#}	1.53±.12 ^{a*}

C, control; HT, hyperthyroid; NC, native curcumin; PNC, nanocurcumin. Data are expressed as mean ± S.E. from 10 rats, ^a*P* ≤ 0.001 compared with the C group, ^{*}*P* ≤ 0.001 compared with HT group, [#]*P* 0.01 versus PNC group.

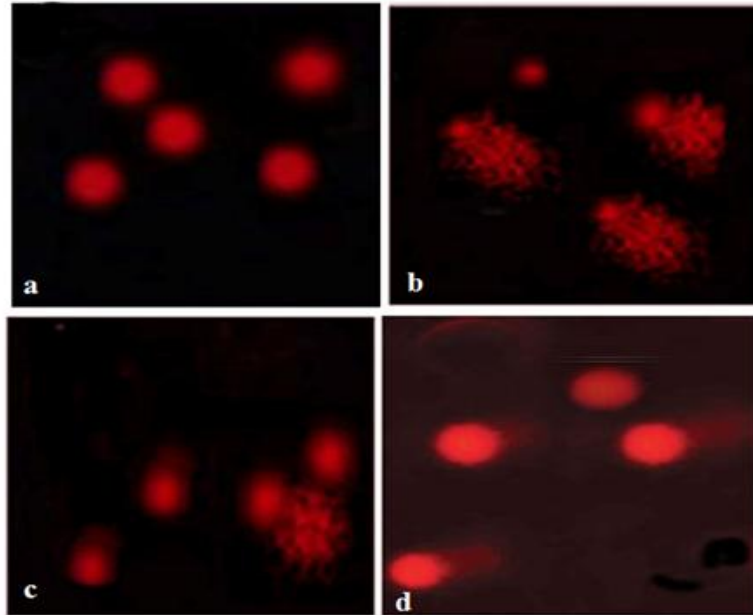


Fig 3: Effect of curcumin (Curc) and nano-curcumin (Curc-nano) on liver DNA damage in hyperthyroidism rat groups. Comet assay showing the degree of liver DNA damage. (a) control, (b) hyperthyroidism, (c) hyperthyroidism + curcumin and (d) hyperthyroidism + curcumin –nano.

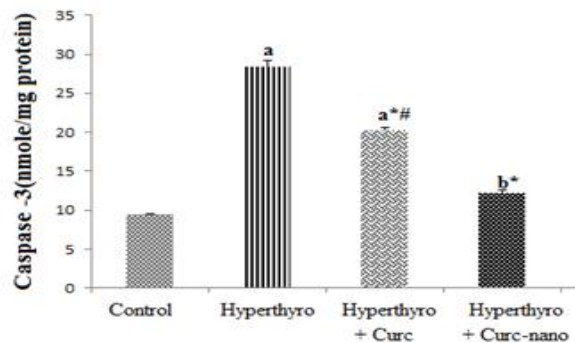


Fig 4 : Effect of curcumin (Curc) and nano-curcumin (Curc-nano) on liver caspase -3 in hyperthyroidism (Hyperthyro) rats. Data are expressed as mean ± S.E. from 10 rats, ^a*P* ≤ 0.001, ^b*P* ≤ 0.01 compared with the control group, ^{*}*P* ≤ 0.001 compared with hyperthyroidism group, [#]*P* ≤ 0.01 versus nano-curcumin group.

Effects of NC and PNC on tissue histopathology

Histopathological changes in liver tissue of hyperthyroid, NC and PNC treated rats are presented in Figure 5. Sections in liver of hyperthyroid rats displayed degenerated hepatocytes with cytoplasmic vacuolization and fatty changes, apoptotic cells with

pyknotic nuclei and inflammatory cell infiltration as compared to normal histology found in control rats. In contrast, hyperthyroid rats treated with NC and PNC showed normal histological appearance of the liver tissue; regular hepatic cords, central vein and hepatocytes.

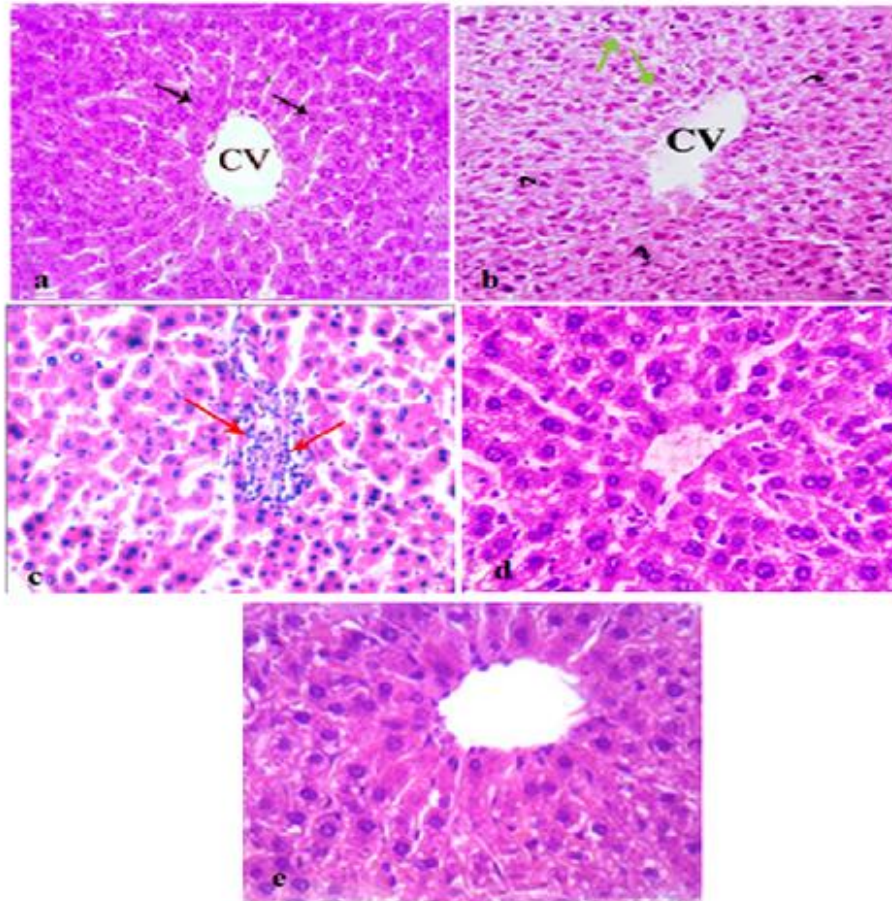


Fig 5 : Photomicrograph of a liver section of different experimental hyperthyroidism rat groups: (a) Section in liver of control rat, showing normal appearance of the hepatocytes (arrows) and central vein(CV).(b&c) Sections in liver of hyperthyroidism rat group, (b) showing degenerated hepatocytes with cytoplasmic vacuolization and fatty changes(green arrows) as well as apoptotic cells with pyknotic nuclei (curved arrows) and (c) showing, inflammatory cells infiltration (red arrows). (d) Section in liver of hyperthyroidism rat group treated with curcumin, showing normal structure and no histopathological alterations. (e) Section in liver of hyperthyroidism rat group treated with curcumin-nano, showing normal histological appearance of the liver tissue; regular hepatic cords , central vein and hepatocytes (H&E x 400).

Effects of NC and PNC on ultrastructural changes in liver

Ultrastructural changes in the liver tissues of hyperthyroid, NC and PNC rats were documented using TEM (Figure 6). Liver sections of control rats displayed normal ultrastructural changes including nucleus, nucleolus nuclear envelop, Golgi bodies, mitochondria and rough endoplasmic reticulum with few fat droplets and well-distributed cytoplasm. Whereas, liver sections of hyperthyroid rat exhibited nucleus with irregular nuclear membrane, dilated

mitochondria, increased fat droplets and vacuoles in the cytoplasm, shrunken nucleus and condensed chromatin. In the liver sections of hyperthyroid rats treated with NC, euchromatic nucleus with regular outline, many mitochondria separated by rER, two electron lucent vacuoles (V) of variable sizes with the smaller one near the cell surface **were observed while** liver sections of hyperthyroid rats treated with PNC showed normal hepatocyte with euchromatic nucleus, prominent nuclear membrane, rough endoplasmic reticulum (rER) and mitochondria (M) having normal cristae.

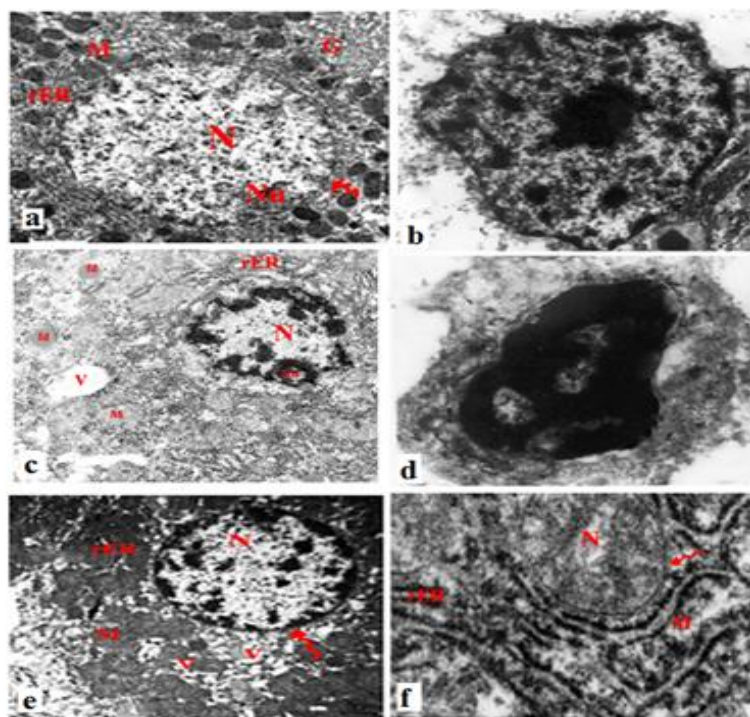


Fig 6 : Transmission electron micrograph of the liver of hyperthyroidism rat groups, (a&b) liver section of control rats, (a) showing nucleus (N), nucleolus (NU), nuclear envelop (zigzag arrow), Golgi (G), mitochondria(M) and rough endoplasmic reticulum (rER) with few fat droplets and well-distributed cytoplasm. The nucleus was normal with other organelles (TEM mag. $\times 8000$), (b) showing normal nuclei and cytoplasm of hepatocytes (TEM mag. = 15,000 \times). (c &d) Liver sections in hyperthyroidism rats, (c) showing the nucleus (N) with irregular nuclear membrane, dilated mitochondria (M), some fat droplets (fd) and many vacuoles (v) appeared in the cytoplasm, (d) showing hepatocyte with shrunken nucleus and condensed chromatin under going apoptosis (TEM mag. $\times 8000$). (e) Liver section of hyperthyroidism rat treated with curcumin, showing hepatocyte exhibited euchromatic nucleus with regular outline (N), many mitochondria (M) separated by rER, two electron lucent vacuoles (V) of variable sizes with the smaller one near the cell surface (TEM mag. = 8000 \times). (f) Liver section of hyperthyroidism rat treated with curcumin-nano, showing normal hepatocyte with euchromatic nucleus (N), prominent nuclear membrane (zigzag arrow), rough endoplasmic reticulum (rER) and many mitochondria (M) having normal cristae (TEM mag. = 8000 \times).

Effects of NC and PNC on liver functional markers

The levels of functional markers including albumin, AST, ALT and ALP in liver tissue are presented in Table 2. Compared to normal control rats hyperthyroid rats had significantly elevated ALP, AST and ALT

and significantly decreased albumin levels. Treatment of hyperthyroid animals with NC, caused a significant reversal in the studied markers, while the levels of ALP, AST and ALT were further decreased and that of albumin were further increased significantly in rats treated with PNC.

Table 2: Effects of curcumin and nanocurcumin on liver functional markers in hyperthyroid rats.

Parameters	C	HT	NC	PNC
Albumin (g/dl)	4.75±0.20	2.45±0.12 ^a	3.82±0.5 ^{c*#}	5.00±0.147*
ALP (U/L)	55.5±1.55	135.7±.85 ^a	61.5±1.55 ^{c*#}	56.6±2.05 *
AST(U/L)	34.75 ± .85	189.25±2.8 ^a	51.5±1.2 ^{a*#}	32.75±.48*
ALT(U/L)	23.5±0.64	81.5±2.21 ^a	34.00±1.68 ^{a*#}	24.5±1.19*

C, control; HT, hyperthyroid; NC, native curcumin; PNC, nanocurcumin, ALP, alkaline phosphatase; AST, aspartate aminotransferase; ALT, alanine aminotransferase. Data are expressed as mean ± S.E. from 10 rats, ^a*P* ≤ 0.001, ^c*P* ≤ 0.05 compared with the C group, * *P* ≤ 0.001 compared with HT group, # *p* 0.01, ## *p* 0.05 versus PNC group, using ANOVA and Bonferroni as a post-ANOVA test

Effects of NC and PNC on liver Thyroid markers

To confirm the onset of hyperthyroidism in the rats treated with L-thyroxine 4 and to assess the effect of NC and PNC on thyroid function , the thyroid markers including T3, T4 and TSH were measured in the serum (Table 3) . As expected, hyperthyroid

animals displayed a pronounced elevation in T3 and T4 levels and a marked decrease in TSH levels. Both the NC and PNC were able to significantly reverse the effects of hyperthyroidism, however, the PNC was significantly more pronounced in reversing the effects of hyperthyroidism as compared to NC.

Table 3: Effect of curcumin, and nano-curcumin on the serum levels of thyroid hormones in hyperthyroid rats

Parameters	Control	HT	NC	PNC
TSH (ng/ml)	1.52±.007	0.53±0 .02 ^a	1.42±0.08*	1.6±0.07*
T4 (µg/dl)	4.37±.15	27.74±0.84 ^a	5.96±0.36 ^{c*##}	3.9±0.28*
T3 (ng/ml)	0.44±.01	1.6±.045 ^a	0.73±.03 ^{a*}	0.66±.03 ^{a*}

C, control; HT, hyperthyroid; NC, native curcumin; PNC, nanocurcumin. Data are expressed as mean ± S.E. from 10 rats, ^a*P* ≤ 0.001, ^c*P* ≤ 0.05 compared with the control group, * *P* ≤ 0.001 compared with HT group, # *p* 0.01, ## *p* 0.05 versus HT+PNC group, using ANOVA and Bonferroni as a post-ANOVA test

Discussion

Curcumin has been in use for centuries to treat various human ailments [19]. Curcumin is hydrophobic compound and accordingly is insoluble in water at acidic and neutral pH. Moreover beneficial effects of curcumin are hampered by its high metabolic rate, low solubility, poor absorption and faster excretion all of which make reduced bioavailability of curcumin and limits its therapeutic effects [20, 21]. To overcome these inherent limitations a number of studies have proposed the utilization of nanoformulations to deliver the curcumin because of size, stability and biocompatibility of nanomaterials. In this study we tested the nanoparticle encapsulated curcumin for its ability to blunt the hyperthyroidism induced liver dysfunction and verified the relative potentials of PNC and NC in alleviating the negative effects of hyperthyroidism on liver function and structure. We found that both NC and PNC were able to restore the functional as well as structural changes brought about by hyperthyroidism. Importantly, the effect of PNC was found to be more pronounced than that of NC in attenuating the negative effects of hyperthyroidism. Increased T3, T4 and decreased TSH levels confirms hyperthyroidism in LT4 treated rats. Besides, hyperthyroidism induced oxidative stress, inflammation and genotoxicity in rats as evident from increased levels of oxidative stress and inflammatory markers and DNA damage. Significant decreases in liver functional markers including AST, ALP and ALT levels in hyperthyroid rats after treatment with NC and PNC demonstrate their hepatoprotective effects. Importantly, the levels of these functional markers were found to be significantly and favorably different between the hyperthyroid rats treated with NC and those treated with PNC clearly indicating the enhanced beneficial effects of PNC in improving liver function in hyperthyroid rats. Further, significant decreases in oxidative stress and inflammatory markers as well as significant increases in antioxidant levels in NC and PNC treated hyperthyroid rats demonstrate the mechanism of action of both these agents. PNC displayed significantly augmented effects in lowering these markers compared to NC. As evident from comet assay data, PNC was significantly more effective than NC in reversing the DNA damage induced by hyperthyroidism in rats. Treatment with PNC significantly restored the hyperthyroidism induced histopathological as well as ultrastructural changes in the liver pointing to antioxidant potential of PNC. Collectively, the findings in this study clearly indicate that therapeutic properties of curcumin can be

maximized by its encapsulation in nanoparticles. Downregulation of oxidative stress, inflammation and DNA damage by PNC suggest its multi-level beneficial effects. Our findings are consistent with a number of studies where encapsulation of curcumin in various nanoformulations has been shown to improve its effects on different cellular parameters in animal and cell based systems by enhancing stability and bioavailability. For example, oral feeding of PLGA encapsulated curcumin exhibited increased bioavailability through enhanced retention in the brain and prevented the breakdown of blood-brain barrier [9]. Importantly, the improved performance of nanocurcumin is suggested to be mediated by decreased inflammatory cytokines, chemokine receptor and increased anti-inflammatory cytokines [9]. Similarly, enhanced antiangiogenic effects of curcumin including inhibition of HUVEC proliferation, migration, invasion, and tube formation were noticed in human liver cancer SMMC 7721 cells treated with curcumin encapsulated in pH-sensitive polymeric nanoparticles [22]. Curcumin encapsulated hyaluronic acid-poly lactide nanoparticles significantly reduced serum aspartate transaminase and alanine transaminase, attenuated tissue collagen production and cell proliferation and ameliorated thioacetamide-induced murine hepatic fibrosis [23]. In line, vesicular and nanoparticulate delivery of curcumin was able to attenuate inflammation, oxidative stress and protect carbon tetrachloride induced hepatocellular damage in a rat model [24]. It is evident from different published data that the unique properties of nanoparticle formulations appear to enhance curcumin stability, solubility, absorption and targeted delivery. For example, methoxy poly (ethylene glycol) poly (-caprolactane) nanoparticles have been shown to effectively deliver the curcumin with heightened oral bioavailability [25]. The PLGA and PEG coated curcumin was found to show higher efficiency and faster cellular uptake than the NC [26]. Likewise, encapsulation of curcumin with solid lipid nanoparticles resulted in an enhanced stability and biocompatibility [27]. Folate conjugated curcumin-loaded human serum albumin nanoparticles are reported to impart sustained curcumin release at desired sites and prolonged retention time in vivo [28]. Curcumin encapsulation in a cationic liposome containing PEI-PEG as a carrier exhibited enhanced anti-tumor effects with increased anti-proliferative effects due to rapid penetration of encapsulated curcumin into the cells [29]. In line curcumin loaded lipid nanoparticles inhibited cellular proliferation,

migration, incursion, cell cycle progression and contributed to higher percentage of apoptosis in glioma cells demonstrating superiority of nanoparticle encapsulated curcumin in aqueous solubility, cellular uptake, controlled release and dissolution rates [30]. Collectively, these data are consistent with our findings of improved properties of curcumin encapsulated in PLGA to blunt the oxidative stress, inflammation, DNA damage and prevent liver damage. This is the first comparative study to demonstrate the favorable effects of nanoformulation of curcumin in reversing the liver dysfunction induced by hyperthyroidism in vivo.

References

- Jin, T., et al., Curcumin and other dietary polyphenols: potential mechanisms of metabolic actions and therapy for diabetes and obesity. *Am J Physiol Endocrinol Metab*, 2017: p. ajpendo 00285 2017.
- Shang, W., et al., Curcumin inhibits osteoclastogenic potential in PBMCs from rheumatoid arthritis patients via the suppression of MAPK/RANK/c-Fos/NFATc1 signaling pathways. *Mol Med Rep*, 2016. **14**(4): p. 3620-6.
- Sevastre-Berghian, A.C., et al., Curcumin Reverses the Diazepam-Induced Cognitive Impairment by Modulation of Oxidative Stress and ERK 1/2/NF-kappaB Pathway in Brain. *Oxid Med Cell Longev*, 2017. **2017**: p. 3037876.
- Cai, J., et al., Curcumin mitigates cerebral vasospasm and early brain injury following subarachnoid hemorrhage via inhibiting cerebral inflammation. *Brain Behav*, 2017. **7**(9): p. e00790.
- Trigo Gutierrez, J.K., et al., Encapsulation of curcumin in polymeric nanoparticles for antimicrobial Photodynamic Therapy. *PLoS One*, 2017. **12**(11): p. e0187418.
- Huang, N., et al., PLGA nanoparticles modified with a BBB-penetrating peptide co-delivering Abeta generation inhibitor and curcumin attenuate memory deficits and neuropathology in Alzheimer's disease mice. *Oncotarget*, 2017. **8**(46): p. 81001-81013.
- Liu, J.L., et al., Curcumin inhibits MCF-7 cells by modulating the NF-kappaB signaling pathway. *Oncol Lett*, 2017. **14**(5): p. 5581-5584.
- Hussain, Z., et al., Exploring recent developments to improve antioxidant, anti-inflammatory and antimicrobial efficacy of curcumin: A review of new trends and future perspectives. *Mater Sci Eng C Mater Biol Appl*, 2017. **77**: p. 1316-1326.
- Dende, C., et al., Nanocurcumin is superior to native curcumin in preventing degenerative changes in Experimental Cerebral Malaria. *Sci Rep*, 2017. **7**(1): p. 10062.
- Khosropanah, M.H., et al., Analysis of the Antiproliferative Effects of Curcumin and Nanocurcumin in MDA-MB231 as a Breast Cancer Cell Line. *Iran J Pharm Res*, 2016. **15**(1): p. 231-9.
- Basniwal, R.K., R. Khosla, and N. Jain, Improving the anticancer activity of curcumin using nanocurcumin dispersion in water. *Nutr Cancer*, 2014. **66**(6): p. 1015-22.
- Khemichian, S. and T.L. Fong, Hepatic dysfunction in hyperthyroidism. *Gastroenterol Hepatol (N Y)*, 2011. **7**(5): p. 337-9.
- Subudhi, U. and G.B. Chainy, Expression of hepatic antioxidant genes in l-thyroxine-induced hyperthyroid rats: regulation by vitamin E and curcumin. *Chem Biol Interact*, 2010. **183**(2): p. 304-16.
- Subudhi, U., et al., Alleviation of enhanced oxidative stress and oxygen consumption of L-thyroxine induced hyperthyroid rat liver mitochondria by vitamin E and curcumin. *Chem Biol Interact*, 2008. **173**(2): p. 105-14.
- Buege, J.A. and S.D. Aust, Microsomal lipid peroxidation. *Methods Enzymol*, 1978. **52**: p. 302-10.
- Beutler, E., O. Duron, and B.M. Kelly, Improved method for the determination of blood glutathione. *J Lab Clin Med*, 1963. **61**: p. 882-8.
- Aebi, H., Catalase in vitro. *Methods Enzymol*, 1984. **105**: p. 121-6.
- Singh, N.P., et al., A simple technique for quantitation of low levels of DNA damage in individual cells. *Exp Cell Res*, 1988. **175**(1): p. 184-91.
- Gera, M., et al., Nanoformulations of curcumin: an emerging paradigm for improved remedial application. *Oncotarget*, 2017. **8**(39): p. 66680-66698.
- Shehzad, A., F. Wahid, and Y.S. Lee, Curcumin in cancer chemoprevention: molecular targets, pharmacokinetics, bioavailability, and clinical trials. *Arch Pharm (Weinheim)*, 2010. **343**(9): p. 489-99.
- Wahlstrom, B. and G. Blennow, A study on the fate of curcumin in the rat. *Acta Pharmacol Toxicol (Copenh)*, 1978. **43**(2): p. 86-92.
- Zhang, J., et al., pH-sensitive polymeric nanoparticles for co-delivery of doxorubicin and curcumin to treat cancer via enhanced pro-

- apoptotic and anti-angiogenic activities. Acta Biomater, 2017. **58**: p. 349-364.
23. Chen, Y.N., et al., Ameliorative Effect of Curcumin-Encapsulated Hyaluronic Acid-PLA Nanoparticles on Thioacetamide-Induced Murine Hepatic Fibrosis. Int J Environ Res Public Health, 2016. **14**(1).
24. Choudhury, S.T., et al., Vesicular (liposomal and nanoparticulated) delivery of curcumin: a comparative study on carbon tetrachloride-mediated oxidative hepatocellular damage in rat model. Int J Nanomedicine, 2016. **11**: p. 2179-93.
25. Sasaki, H., et al., Innovative preparation of curcumin for improved oral bioavailability. Biol Pharm Bull, 2011. **34**(5): p. 660-5.
26. Baek, J.S. and C.W. Cho, Surface modification of solid lipid nanoparticles for oral delivery of curcumin: Improvement of bioavailability through enhanced cellular uptake, and lymphatic uptake. Eur J Pharm Biopharm, 2017. **117**: p. 132-140.
27. Jourghanian, P., et al., Sustained release Curcumin loaded Solid Lipid Nanoparticles. Adv Pharm Bull, 2016. **6**(1): p. 17-21.
28. Song, Z., et al., Novel curcumin-loaded human serum albumin nanoparticles surface functionalized with folate: characterization and in vitro/vivo evaluation. Drug Des Devel Ther, 2016. **10**: p. 2643-9.
29. Sun, M., et al., Enhancement of transport of curcumin to brain in mice by poly(n-butylcyanoacrylate) nanoparticle. Journal of Nanoparticle Research, 2010. **12**(8): p. 3111-3122.
30. Kundu, P., C. Mohanty, and S.K. Sahoo, Antiglioma activity of curcumin-loaded lipid nanoparticles and its enhanced bioavailability in brain tissue for effective glioblastoma therapy. Acta Biomater, 2012. **8**(7): p. 2670-87.

Access this Article in Online	
	Website: www.ijarbs.com
	Subject: Biochemistry
Quick Response Code	
DOI: 10.22192/ijarbs.2017.04.12.009	

How to cite this article:

Widad M. Al-Bishri. (2017). Hepato therapeutic Efficacy of Native Curcumim and Nano -curcumin: A Novel Therapy Against Hyperthyroidism Induced Liver Oxidative and Inflammatory Damage in Rats . Int. J. Adv. Res. Biol. Sci. 4(12): 86-97.

DOI: <http://dx.doi.org/10.22192/ijarbs.2017.04.12.009>