



Histopathological effect of Pyrethroid insecticide, Lambda-Cyhalothrin on intestine of fish, *Etroplus suratensis*

V.Vidhya¹ and C.Radhakrishnan Nair²

¹Department of Zoology, Sree Ayyappa College for Women, Chunkankadai- 629 003, Kanyakumari District, TamilNadu, India.

²PG and Research Centre, Department of Zoology, South Travancore Hindu College, Nagercoil-629 002, Kanyakumari District, TamilNadu, India.

*Corresponding author: vidhyavkrishna@yahoo.com¹; rknairsthc@gmail.com²

Abstract

Freshwater and brackishwater fish, *E. suratensis* was exposed to different sub-lethal concentration of a pyrethroid insecticide, lambda-cyhalothrin for a period of 60 days. The histopathological changes observed in the intestine due to lambda-cyhalothrin treatment, rupture of cells, degeneration changes in tips of villi, condensed musculosa, curved villi, haemorrhage, necrosis, long and short ruptured villi, numerous vacuoles, dilation in the blood vessels, completely damaged villi and loss of architecture.

Keywords: Completely damaged, *E. suratensis*, Intestine, Lambda-cyhalothrin, Pyrethroid insecticide.

Introduction

Lambda-cyhalothrin (trade name Karate) is a pyrethroid insecticide. Lambda-cyhalothrin was first approved for use in the UK in 1988 (Advisory Committee on Pesticides, 1988). Frequency and intensity of tissue lesions depend on the concentrations of insecticides and the length of the period fish are exposed to toxins. Nevertheless, many insecticides cause specific or non-specific histopathological damage (Fanta *et al.*, 2003). Histopathological alterations after the exposure to pesticides in various fish species are described by several authors. Anees (1976) reported the sub-lethal concentrations of diazinon causing serious damage to gut wall in a freshwater teleost, *Channa punctatus*. Virk *et al.* (1987) investigated the histopathological and biochemical changes induced by endrin and carbaryl in the stomach, intestine, liver of *Mystus tengara*. Hall and Bellwood (1995) reported the histological effects of cyanide, stress and starvation on the intestinal mucosa of *Pomacentrus coelestis*, a marine aquarium

fish species. Histopathological techniques are rapid, sensitive, reliable and comparatively inexpensive tools for the assessment of stress-response to pollutants. Hence the different sub-lethal effects of lambda-cyhalothrin on morphology of intestine tissues from *E. suratensis* were studied.

Materials and Methods

A group of 10 fishes without sex determination were exposed to 0.005 ppm, 0.006, 0.008, 0.013 and 0.026 ppm (1/20, 1/16, 1/12, 1/8 and 1/4 sub-lethal concentration of LC₅₀ value) for observing the histopathological changes. The test solution and the pesticide free medium in which fishes were maintained, were renewed daily. After 60 days of pesticide (lambda-cyhalothrin) exposure, the intestine of control and pesticide treated *E. suratensis* were taken out and a histological study was carried out by Culling (1974) method.

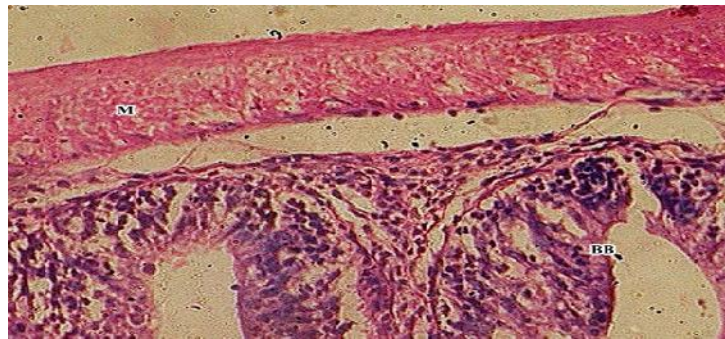
Results

Normally in fish, the wall of the intestine consists of three layers viz., the inner mucosa, the middle submucosa and outer muscularis layer. The mucosal layer had brush-like projections called microvilli. Series of villi arranged in around the lumen. The mucous lining is composed of columnar epithelial cells which are arranged in a single layer. These cells are rectangular with a broad free end and a narrow base. The nuclei are elliptical with dense chromatin. These cells have terminal bars and striated border. The epithelial cells are interspersed with goblet cells which secrete mucous and have a characteristic vacuole filled with mucous (Plate 1).

In fishes exposed to 0.005 ppm of lambda-cyhalothrin for 60 days caused shortening in villi with inflammation

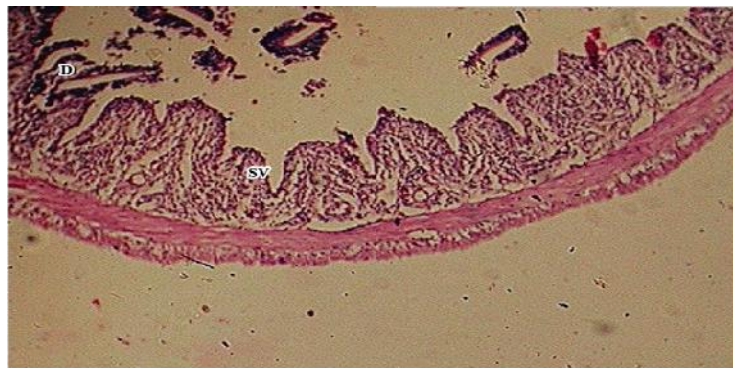
response and degeneration of submucosa (Plate 2). Fishes exposed to 0.006 ppm of lambda-cyhalothrin highly branched and fused villi, rupture of cells, degeneration changes in tips of villi, condensed musculosa and curved villi were observed (Plate 3). In *E. suratensis* exposed to 0.008 ppm of lambda-cyhalothrin, haemorrhage, necrosis, long and short ruptured villi and numerous vacuole were noticed (Plate 4). The intestine of *E. suratensis* exposed to sub-lethal concentration of lambda-cyhalothrin (0.013 ppm) showed dilation in the blood vessels, completely damaged villi, loss of architecture and degeneration of serosa were identified (Plate 5). The pathological findings in the higher concentration (0.026 ppm) of *E. suratensis* included dilation of blood vessels, ruptured villi, necrosis, decreased micro villi and lumen were noticed (Plate 6).

Plate 1: Section showing the intestine of control *E. suratensis* (400X)



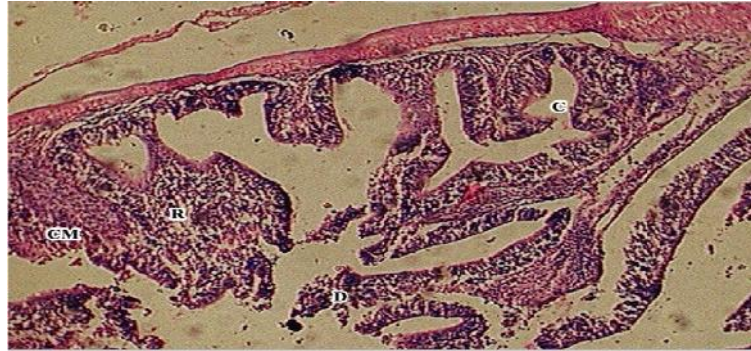M-Muscular region BB-Brush border

Plate 2: Section showing the intestine of *E. suratensis* exposed to 0.005 ppm concentration of lambda-cyhalothrin (400X)



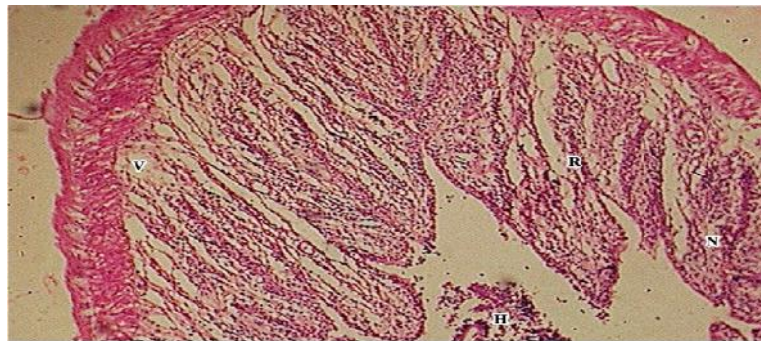
SV-Shortening in villi with inflammation;
D-Degeneration of mucosa and sub mucosa layer

Plate 3: Section showing the intestine of *E.suratensis* exposed to 0.006 ppm concentration of lambda-cyhalothrin (400X)



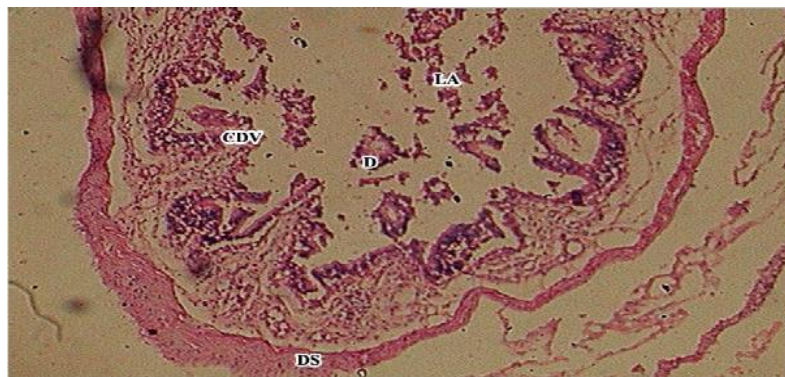
R-Rupture of cells
D-Degeneration changes in tips of villi
CM-Condensed musculosa C-Curved villi

Plate 4: Section showing the intestine of *E.suratensis* exposed to 0.008 ppm concentration of lambda-cyhalothrin (400X)



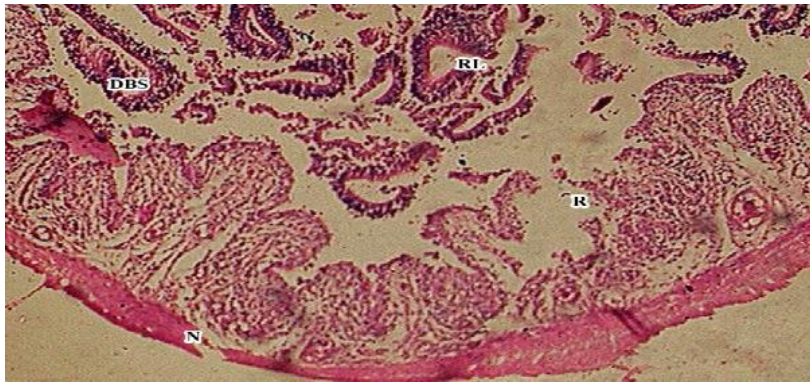
H-Haemorrhage N-Necrosis
R-Ruptured villi V-Vacuole

Plate 5: Section showing the intestine of *E.suratensis* exposed to 0.013 ppm concentration of lambda-cyhalothrin (400X)



D-Dilation in the blood vessels CDV-Completely damaged villi
LA-Loss of architecture DS-Degeneration of serosa

Plate 6: Section showing the intestine of *E.suratensis* exposed to 0.026 ppm concentration of lambda-cyhalothrin (400X)



DBS-Dilation in the blood vessels R-Ruptured villi
N-Necrosis RL-Reduced lumen

Discussion

Intestine is an important organ of absorption and naturally the harmful effects of the constituents of the pollutant may be expected to manifest themselves in the structure and functioning of the intestine (Murugesan, 1988). Changes observed in the intestine due to lambda-cyhalothrin treatment, rupture of cells, degeneration changes in tips of villi, condensed musculosa, curved villi, haemorrhage, necrosis, long and short ruptured villi, numerous vacuoles, dilation in the blood vessels, completely damaged villi and loss of architecture. Earlier workers have also reported similar results. *Tunica muscularis* exposure to atrazine showed nuclear depolarization, cytoplasmic vacuolation and desquamation of gastric mucosa (Walsh and Ribelin, 1975). Sastry and Malik (1979) have observed that dimecron caused vacuolation in cytoplasm, ruptured stomach mucosa and mucus secreting goblet cells showed hypertrophy and the intestinal lumen was also filled with mucus. Vacuolation and necrosis of the oesophagus in *Coho salmon* were caused by acrolein exposure (Hendricks, 1979).

Reports on degenerative changes and rupture in tip of villi, loss of structural integrity of mucosal folds, degeneration and necrosis of submucosa in the intestine of *Channa punctatus* after the exposure to carbofuran are found in literature (Muley *et al.*, 1996). The pathological alterations in the intestine of the studied fish are in agreement with those observed by many investigators about the effects of different toxicants on fish intestine (Hanna *et al.*, 2005; Cengiz, 2006). Singh (1983) reported the rupture and detachment of columnar epithelium and lesion formation in the intestinal villi of *Colisa fesciata*

treated with copper solution. Crespo *et al.* (1986) noticed increased mucous cell activity and disruption of brush borders in the intestine of trout by a diet containing cadmium and lead. Anderson *et al.* (1974) reported that naphthalene, a component of many petroleum mixtures, has been shown to induce extensive necrosis of the gut mucosa in marine fishes. Under the light of this study suggests that, lambda-cyhalothrin contamination is dangerous to aquatic ecosystems and this fact should be taken into consideration when this insecticide is used in agricultural and other fields.

References

- Advisory committee on pesticides, 1988.** Evaluation number 20: LC.London: *Min. Agric. Fish. Food.*
- Anderson, J.W, J.M. Neef, B.A. Cox, H.E. Tatem and G.M. Hightower, 1974.** Characteristics of dispersions and water soluble extracts of crude and refined oils and their toxicity to esturine crustaceans and fish. *Marine Biology.*, **27**: 75-88.
- Anees, M.A., 1976.** Intestinal pathology in freshwater teleost, *Channa punctatus* (Bloch) exposed to sub-lethal and chronic levels of three organophosphorus insecticides. *Acta Physiol. Lat. Am.*, **26**: 63-67.
- Cengiz, E.I., 2006.** Gill and kidney histopathology in the freshwater fish *Cyprinus carpio* after acute exposure to deltamethrin. *Environmental Toxicology and Pharmacology.*, **22**: 200-204.
- Crespo, S., G. Nonnotte, D.A. Colin, C. Leray, L. Nonnotte and A. Aubree, 1986.** Morphological and functional alteration induced in trout intestine by dietary cadmium and lead. *J. Fish. Biol.*, **28**: 69-80.

- Culling, C.F.A., 1974.** Handbook of histopathological and histochemical techniques, 3rd edition.
- Fanta, E., Sant'Anna Rios, F. Romao, S. Vianna and S. Freiburger, 2003.** Histopathology of the fish *Corydoras paleatus* contaminated with sub-lethal levels of organophosphorus in water and food. *Ecotoxicology and Environmental Safety.*, **54**: 119–130.
- Hall, K.C. and D.R. Bellwood, 1995.** Histological effects of cyanide, stress and starvation on the intestinal mucosa of *Pomacentrus coelestis*, a marine aquarium fish species. *Journal of Fish Biology.*, **47**(3): 438-454.
- Hanna, M., I. Shaheed and N. Elias, 2005.** A contribution on chromium and lead toxicity in cultured *Oreochromis niloticus*. *Egypt. J. Aquat. Biol. Fish.*, **9**: 177-209.
- Hendricks, J.D., 1979.** Appendix II . Effect of various herbicides on histology of yearling *Coho salmon*. In: Effects of selected herbicides on molting of *Coho salmon*. H.W. Lorz, S.W. Glenn, R.H. Williams, C.M. Kunkel, L.A.
- Muley, D.V., G.B. Kamble and P.T. Gaikwad, 1996.** Endosulfan toxicity in the freshwater fish *Tilapia mossambica*. *Proc. Acad. Environ. Biol.*, **5**(1): 49-55.
- Murugesan, A.G., 1988.** Toxicity of textile, mill effluent to an air breathing fish. Ph.D. Thesis. Madurai Kamaraj University. 207.
- Sastry, K.V. and P.V. Malik, 1979.** Studies on the effect of dimecron on the digestive system of a freshwater fish, *Channa punctatus*. *Arch. Environ. Contam. Toxicol.*, **20** : 674-677.
- Virk, S., K.K. Deep and K. Satinderpal, 1987.** Histopathological and biochemical changes influenced by endrin and carbaryl in the stomach, intestine and liver of *Mystus tengara*. *Indian journal of Ecology.*, **24**(1): 14-20.
- Walsh, A.H. and W.E. Ribelin, 1975.** The pathology of pesticide poisoning In: Gopalakrishnan K.S., 1990: Studies on the effects of some pesticides on the fish *Etroplus maculatus* (Bloch), Ph.D Thesis, Cochin University of Science and Technology, Kerala, India., 124-125.
- Walsh, A.H. and W.E. Ribelin, 1975.** The pathology of pesticide poisoning In: The pathology of Fishes. W.E. Ribelin, and G. Migaki (eds.). University of Wisconsin Press; Madison, Wisconsin. PP. 515-558.

Access this Article in Online	
	Website: www.ijarbs.com
	Subject: Histopathology
Quick Response Code	

How to cite this article:

V.Vidhya and C.Radhakrishnan Nair. (2016). Histopathological effect of Pyrethroid insecticide, Lambda-Cyhalothrin on intestine of fish, *Etroplus suratensis*. Int. J. Adv. Res. Biol. Sci. 3(2): 43-47.