



Pseudotumor cerebri - Clinical presentation, Surgical management and outcome

Dr. Ibrahim Yassin Hussein F.I.C.M. M.B.CH.B.

Neurosurgeon, Iraq

Corresponding author: almashhadani_ibrahim@yahoo.com

Abstract

Pseudotumor cerebri is disorder characterized by increased intracranial pressure without deformity or obstruction of ventricular system, there is predilection to occur in obese women in child bearing age, the pathogenesis of disease is still uncertain but may be due to imbalance between production and absorption of cerebrospinal fluid, papilledema is the hallmark of disease found in every patient, treatment could be medical or surgical depending on patient response.

Objective

To evaluate clinical presentation, possible causes, treatment and incidence of pseudotumor cerebri in patients attending neurosurgical department in GHAZI AL HARRERI teaching hospital for surgical specialties

Patients and Methods

Retrospective study in analysis of 30 patients in neurosurgical department in period between November 2011 and December 2013

Results

30 patient diagnosed with pseudotumor cerebri two males and twenty eight females, 70% obese, papilledema present in all patients, one patient get benefit from medical treatment, 29 patient undergone surgical intervention only 5 patients needs revision.

Conclusion

Pseudotumor cerebri is disease of unknown etiology in most of patients, the diagnostic methodology of IHH must include LP, MRI and brain venography, CSF diversion is the surgery of choice in patients if there is no benefit from medical treatment.

Keywords: Headache, pseudotumor cerebri, Lumboperitoneal shunt, Optic nerve sheath fenestration, Papilledema, Venous sinus thrombosis, intracranial pressure

Introduction

Definition

The syndrome known as pseudotumor cerebri (PTC) is generally thought as a condition characterized by increased intracranial pressure (ICP) without evidence of dilated ventricles or a mass lesion by imaging, normal cerebrospinal fluid (CSF) content, and papilledema, occurring in most cases in young, obese women without any clear explanation. [1]

Historical view

The terminology used to describe this condition has changed dramatically over time and continues to change as new issues regarding its etiology are raised.

Heinrich Quincke, an early pioneer in the use of lumbar puncture, reported the first recorded cases of intracranial hypertension of unknown cause in what he

described as “meningitis serosa” in 1893; at that time, he posited that inadequate CSF resorption was responsible for the syndrome, a theory that is still entertained by some researchers.{2}

The term pseudotumor cerebri appears to have first been used in 1914{1}.

Subsequently, Foley 1955 suggested calling the condition “benign intracranial hypertension” because it appeared to have a much more benign neurological prognosis than increased ICP caused by a central nervous system mass lesion or infection, Because significant visual morbidity may result from PTC, use of the adjective “benign” is no longer considered appropriate terminology.{1}

In the late 1980's, Corbett et al (1982) altered the name to idiopathic intracranial hypertension, since the syndrome was not benign as once thought{1} .

Most physicians use the term idiopathic intracranial hypertension (IIH) for cases of PTC that occur in young, obese patients and the term secondary pseudotumor cerebri for the rare cases in which a cause (e.g., drug induced) is identified.{3}

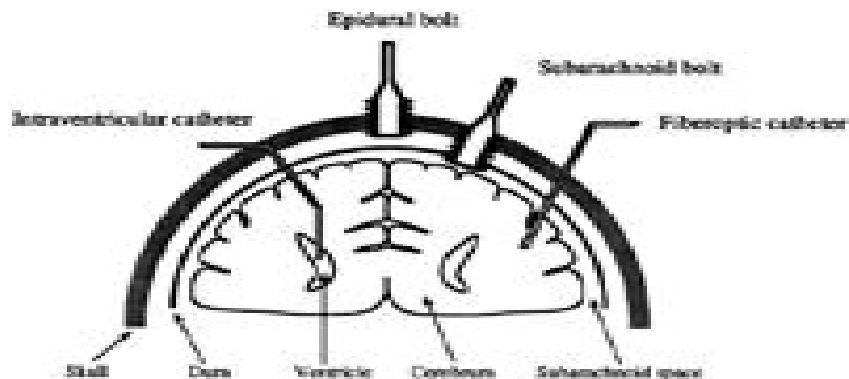
It should also be emphasized that some authors use the term pseudotumor syndrome for patients with increased ICP unassociated with ventricular dilation, evidence of cerebral edema, or an intracranial mass lesion but with abnormal CSF content. This condition occurs in some patients with aseptic, carcinomatous, or lymphomatous meningitis.{4}

Intracranial pressure

Intracranial pressure (ICP) the pressure of the cerebrospinal fluid in the subarachnoid space(the space between the skull and the brain) the normal range is approximately 7 to 13 mm Hg.{5}

Approaches of measuring I.C.P.

1. Non invasive
 - a. Clinical examination
 - b. Fundoscopic examination
 - c. Imaging
2. Invasive
 - a. External ventricular drain placement
 - b. Intraparenchymal fibro optic catheter placement
 - c. Epidural sensor
 - d. Sub arachnoid bolt



Picture (1) illustrating intraventricular catheters, epidural bolts, subarachnoid bolts, and fiberoptic catheters for ICP measurement.{ 19}

Etiology

Idiopathic intracranial hypertension (IIH) is a disorder of unknown etiology that predominantly affects obese women of childbearing age. {1}

The primary problem is chronically elevated intracranial pressure (ICP), and the most important

neurologic manifestation is papilledema, which may lead to progressive optic atrophy and blindness.{1}

Many theories have been advanced to explain the pathogenesis of IIH. According to the Monro-Kellie rule anything added to the blood, CSF, or brain volume or anything impeding CSF or venous egress would be expected to increase I.C.P.{12}

IIH is a diagnosis of exclusion that occurs primarily in young obese women and, occasionally, in obese men with no evidence of any underlying disease{4}.

In about 10% of cases of PTC are associated with a number of different conditions. Suspicion of a secondary cause of PTC is heightened in prepubertal children, men, nonobese women, and otherwise typical patients with rapidly progressive visual loss that does not respond to treatment.{5}

Secondary causes of PTC include:{4}

- (1) impairment or obstruction of cerebral venous sinus drainage by intrinsic or extrinsic lesions.
- (2) endocrine and metabolic dysfunction,.
- (3) exposure to exogenous drugs and other substances.
- (4) withdrawal of certain drugs,.
- (5) systemic illnesses.

Symptoms and signs

Primary PTC (i.e., IIH) and secondary PTC produce identical symptoms and signs.{20}

Occasionally, the condition is asymptomatic and discovered during a routine ophthalmic examination when papilledema is found.{20}

The most common symptom ; headache , transient visual loss and diplopia
Papilledema is the diagnostic hallmark of PTC and is present in almost all patients, the papilledema of PTC is identical with that in patients with other causes of increased ICP. {3}

Diagnosis

The diagnosis of both IIH and secondary PTC requires that there be no intracranial or spinal mass, no evidence of hydrocephalus, documented increased ICP, and normal CSF contents.

Thus, the diagnosis cannot and should not be made without neuroimaging and a lumbar puncture (LP).{23}

Treatment

- a. Medical therapy
 1. Medication to lower ICP
 2. Headache prophylaxis
 3. Corticosteroids
 4. Repeated L P

B. Surgical treatment

1. Lumboperitoneal shunt
2. Optic nerve sheath fenestration
3. Venous sinus stenting.

Patients and Methods

This is a study of thirty patient whose ages range between (19-46) years old, present to neurosurgical department in Ghazi Al- Harriery teaching hospital for surgical speciality in period between November 2011- December 2013 as typical cases of I.I.H. presented with headache, visual disturbance, papilledema....etc.

The radiological investigation has failed to demonstrate intracranial pathology responsible for the raised I.C.P. except in three cases were venous sinus thrombosis.

Twenty eight were female (93.3%) and two were males (6.66%).

C.S.F. pressure was measured through lumber puncture at L4-L5 level in left lateral position with horizontal plane of the body and head to reduce errors as possible.

Visual acuity and visual field was assessed in twenty patients in our hospital by ophthalmologist using Nilson chart and Goldsmann visual field.

Neuroradiological evaluation as computer tomography (C.T.) and M.R.I. was done for all patients.

Ten patients wasdiagnosied in Neuromedicine department in Baghdad teaching hospital and referred to neurosurgical department after failure of medical management and repeated LP to resolve papilledema.

The period of time between diagnosis and surgical intervention range between 6 months and one year.

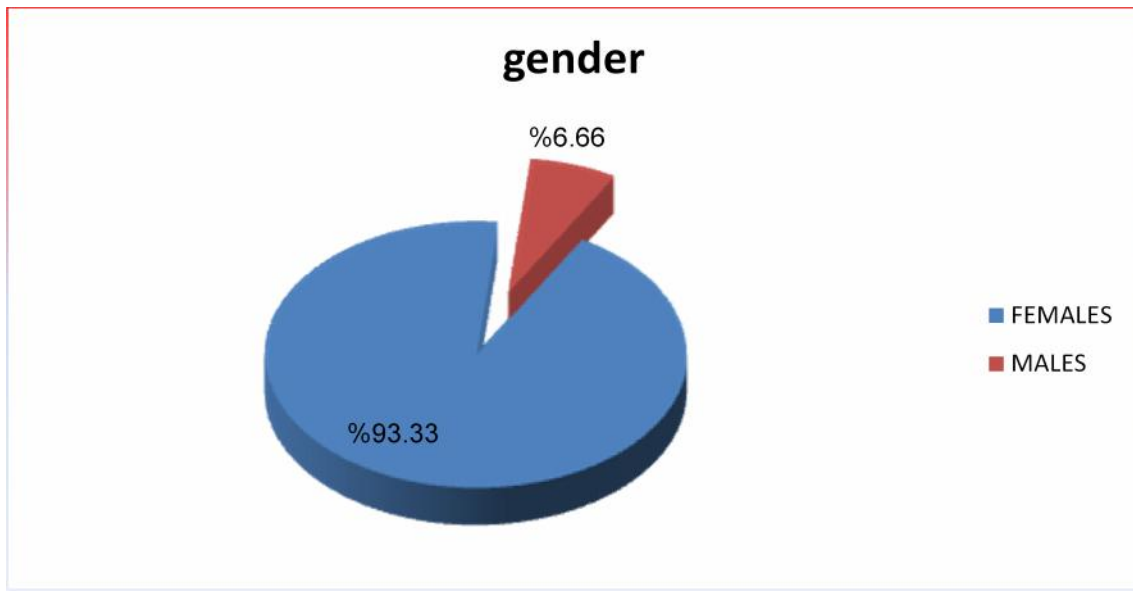
Twenty nine of our patient treated surgically after receiving medical treatment, and only one female patient undergo repeated LPs and surgical intervention without medical treatment.

The Results

All of our patient have elevated I.C.P. greater than 20 cm H₂O consistent with the diagnosis of pseudotumor cerebri

The gender of patient

The majority of our patient were females (28 female and 2 males) 93.33% females and 6.6% males.



The age distribution

The range of age distribution is between (18 and 46 years) with the mean of 28 years old .

The majority of our patient ages where in the age group between (20-29 years) and (30-39 years)

equally 10 patients in each age group which form 33.3% age from the total percentage, and six patients in the age group below 20 years old 20% and four cases above 40 years old 13.4%, as shown in the following table and figure:

Table (1) showing age distribution

Age	Below 20	20-29	30-39	Above 40	Total
Number of cases	6	10	10	4	30
percentage	20%	33.3%	33.3%	13.4%	100%

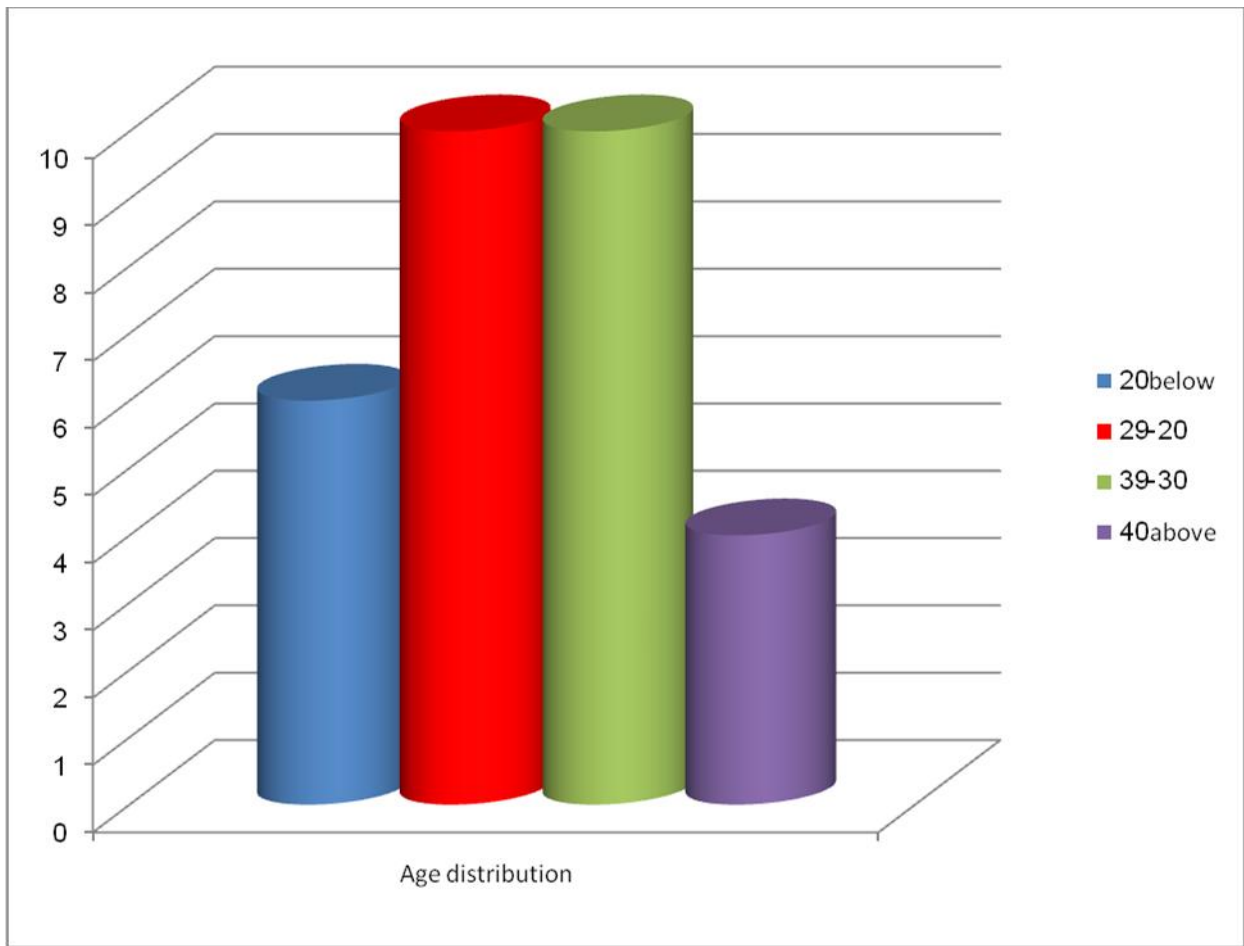


Figure (1) showing age distribution of the study

Associated factors

Obesity is one of the main associated factors in pseudotumor cerebri was present in 21 patient .

Two patient was found to have history of oral contraceptive pills intake in time of diagnosis 6.66% , no history of tetracycline intake or hypervitaminosis A , no pregnancy nor miscarriage, No Addison’s disease as shown in the following tables and figures:

Table (2) showing the associated factors of pseudotumor cerebri

The associated factor	Number of cases	Percentage
obesity	21	70%
Menstrual irregularity	9 (28 female patients)	32.14%
History of oral contraceptive pills	2(28 female patients)	7.14%
pregnancy	0	0%
miscarriage	0	0%
No Addison’s disease	0	0%

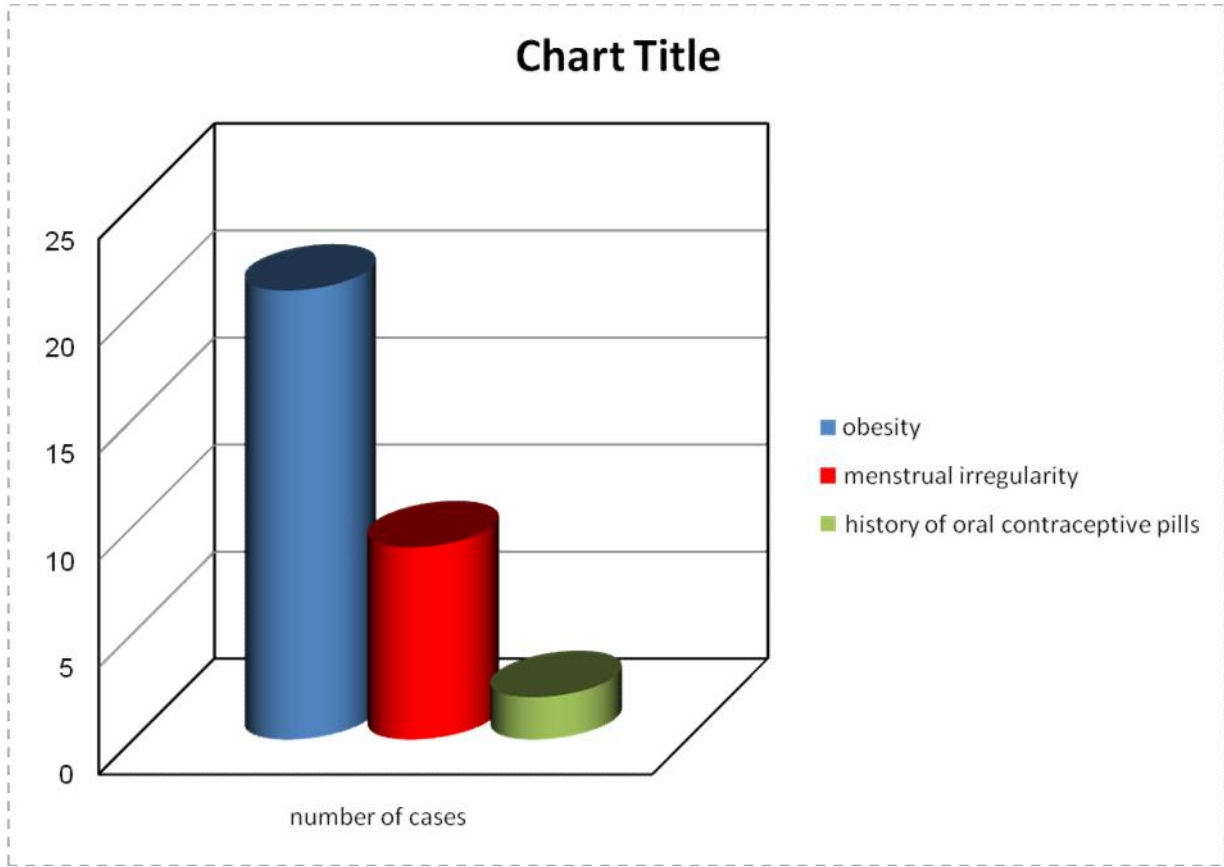


Figure (2) showing associated factors with pseudotumor cerebri

Presenting symptoms

The commonest presenting feature is headache which was present in 26 patients from thirty patients (86.6%), the second presenting symptom in our study is visual disturbance which was found in nineteen

patient(70%), in the form of decrease visual acuity, blurring of vision, transient visual obscuration (T.V.O.), the other compliance was vomiting which was found in seven patients (23.3%), dizziness was found in four patients (13.3%), as shown in the following table and figure:

Table (3) showing presenting symptoms presented in our study

Symptom	Number of cases	Percentage
headache	26	86.6%
Visual disturbance	19	63.3%
vomiting	7	23.3%
dizziness	4	13.3%
Menstrual disturbance	9	32.15%
Cognitive disturbance	0	0%

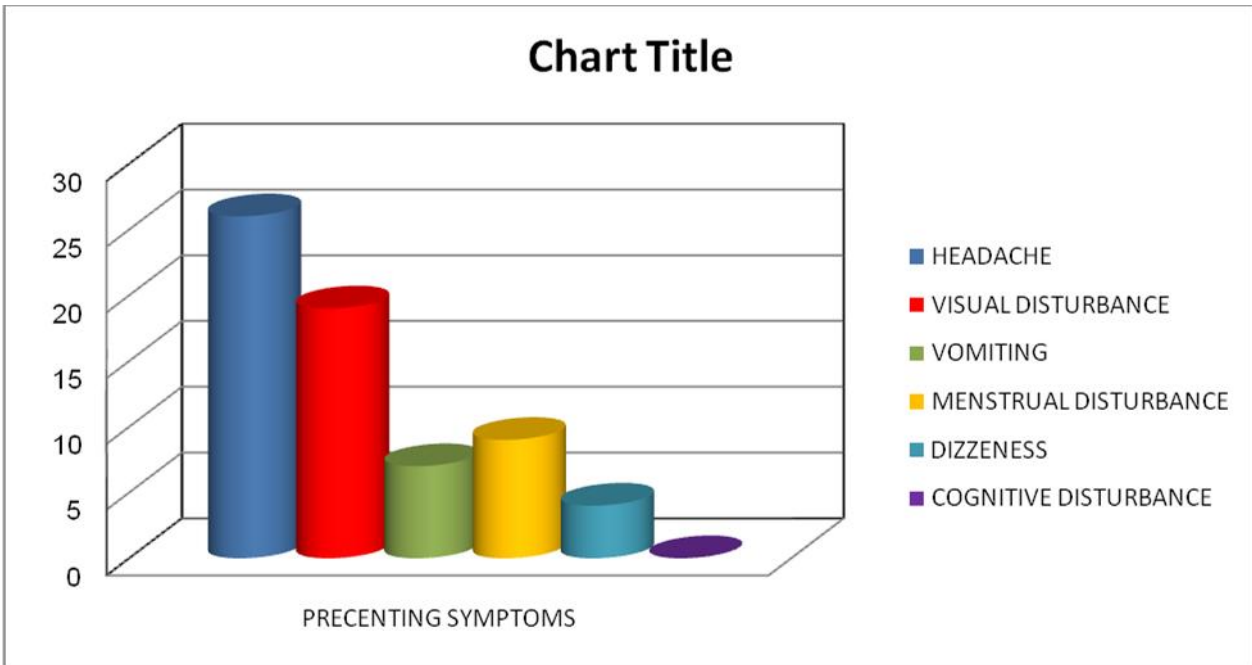


Figure (3) showing presenting symptoms presented in our study

Presenting signs

In our study the most neurological finding is papilledema which was found in all the patients (100%), followed by obesity in 21 patient , decrease

visual acuity in five patients (16.66%) ,enlarge blind spot in 3 patients 10% abducent nerve palsy was observed only in one case (3.3%) same as central scotomas

Table (4) showing the signs founded in our study

signs	Number of cases	Percentage
papilledema	30	100%
Decrease visual acuity and field	5	16.66%
obesity	21	70%
6 th nerve palsy	1	3.3%
Enlargement of blind spot	3	10%
Central scotoma	1	3.3%

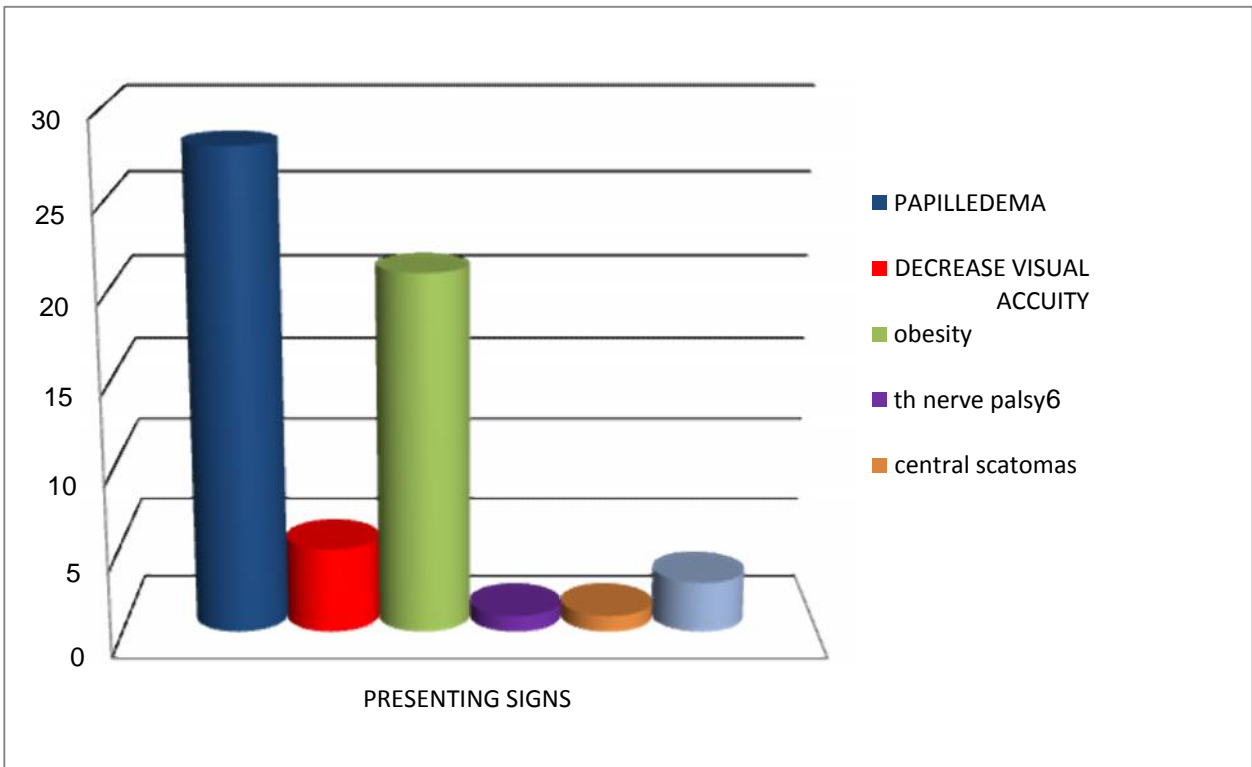


Figure (4) showing signs founded in our study

Neuro- Ophthalmological findings in our study was papilledema at least in one eye in all our cases(100%) with enlarge blind spot in three cases(10%) ,decrease

visual acuity in five patients (16.66%),central scotomas in one patient only 3.3% , as shown in the following table and figure

Table (5) showing ophthalmological findings in our study

Neuro-ophthalmological finding	Number of cases	percentage
papilledema	30	100%
Enlarge blind spot	3	10%
Decrease visual acuity	5	16.66%
Central scotomas	1	3.3%
6 th nerve palsy	1	3.3%

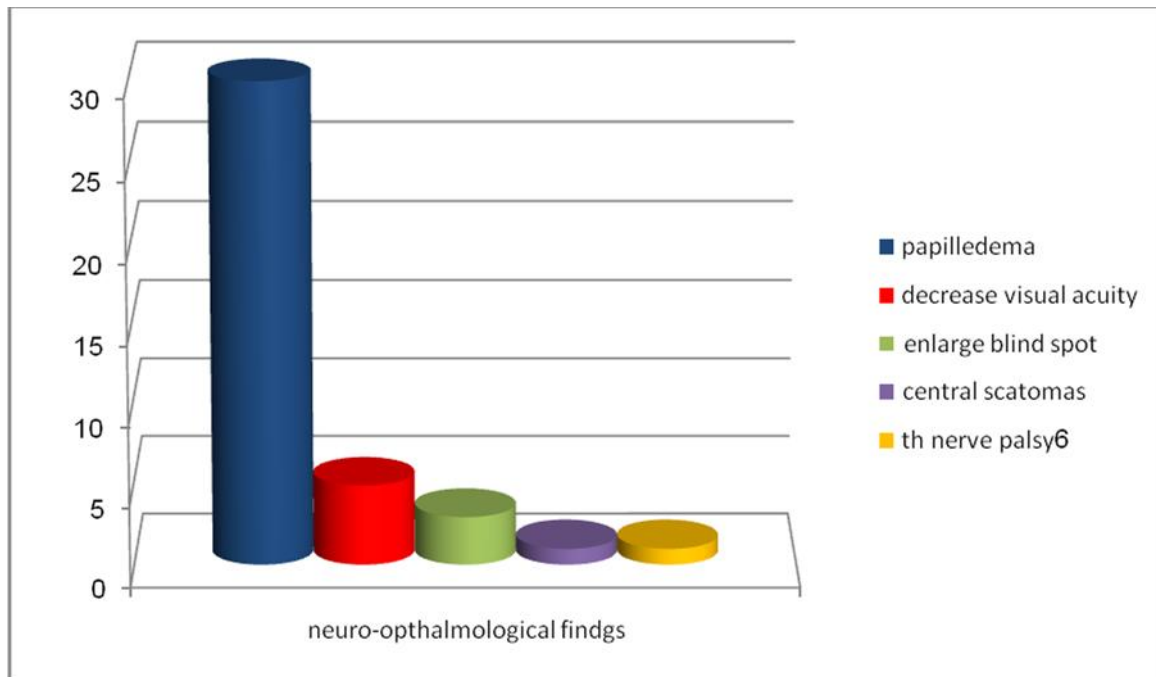


Figure (5) showing neuro ophthalmological findings

All the patient in our study were under gone lumber puncture for diagnostic and therapeutic purposes either in our department or neuromedical department in Baghdad teaching hospital except five patients one

patient referred to our department who already diagnosed as venous sinus thrombosis and the other four Refuse the procedure of lumber puncture.

CSF Finding of 29 patients in our study

Table (6) shows C.S.F. findings in our patients

Patient no.	appearance	Pressure cm H ₂ O	Protein mg/dl	Sugar mg/dl	Cell count
1	clear	25.5	17	64	1-2
2	clear	26	23	58	3-5
3	clear	27	40	70	0-3
4	clear	27,5	35	45	-
5	clear	28	25	62	1-4
6	clear	28	39	46	5
7	clear	290	20	55	2-4
8	clear	29.5	40	57	0
9	clear	31	33	36	1-4

10	clear	33	20	61	-
11	clear	33	33	77	2-3
12	clear	33.5	20	59	3-5
13	clear	33.5	18	48	3-4
14	clear	340	36	83	1-3
15	clear	34.5	38	60	-
16	clear	35	28	66	-
17	clear	36	39	50	1-4
18	clear	36.5	27	72	2-3
19	clear	36,5	17	37	3-5
20	clear	38	-	-	-
21	clear	39	48	48	1-3
22*	clear	40	28	48	0
23	clear	43	40	52	0-2
24	clear	44	33	39	0
25	clear	54	37	47	0-4

(* patient treated medically)(- test not performed or technical error)

All our patients under gone medical treatment by receiving corticosteroid (dexamethasone) diuretics (furosemide and acetazolamide) and repeated lumber puncture , low molecular weight heparin was giving to three patient in which venous sinous thrombosis was the diagnosis.

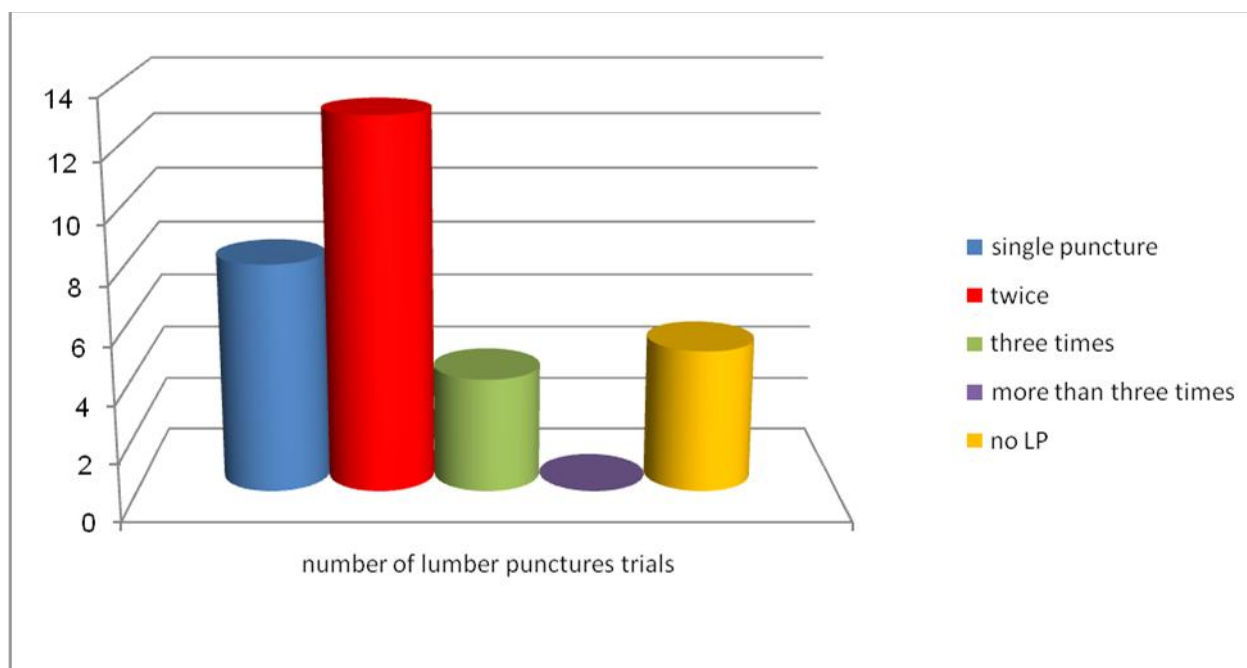
Diamox (acetazolamide)250 mg X 3 alone was given to six patients 20%, Lasix (furosemide) 40 mg X 2 was given to two patients 6.6 %, corticosteroid never been gave alone , while combination of two diuretics was given to nine patients 30% ,combination of two

diuretics and corticosteroid in dose of 8mg X 3 was given to 3 patients 10% , combination of acetazolamide and dexamethasone was given to ten patients33.3%

Twenty nine of our patients performed repeated lumber puncture for diagnostic and therapeutic purposes , five patients did not performed it (16.66%), eight patients done the lumber puncture once (26.66%),thirteen patient performed it twice (43.3%) ,four patient performed it three times(13.33%) as shown in the following figure and table

Table (7) showing the number of cases who performed lumber puncture in our study

Lumber puncture trials	No. of cases	Percentage
No L.P.	5	16.6%
Performed once	8	26.66%
Performed twice	13	43.3%
Performed three times	4	13.33%



Figure(6) showing the number of cases who performed lumber punctures

The outcome of our patients

Only one female patient get benefit from the medical treatment and lumber puncture and there was no need for further surgical intervention and the papilledema and headache resolve after five to seven days of medical treatment and two lumber puncture sessions.

The other twenty nine patients undergone surgical intervention in the form of lumber peritoneal shunt and show improvement in their vision and headache, except two patient did not improve because both diagnosis was so delay so they were present to our department with only slight light perception.

Five patients developed complication of surgery in the form of include spontaneous obstruction of the distal end and immigration of the distal end of the catheter from the peritoneal cavity, three cases shows spontaneous obstruction (10.34%), two patient (6.89%) showed migration of distal end and required shunt revision .

None of our patient developed infection as complication , perforation of abdominal viscus nor ascites.

Three patient required revision due to obstruction of the peritoneal end of the catheter ,and two patient required two revision surgeries due to migration of distal end from peritoneal cavity as shown in the following table and figure.

Table (8) showing the complication and number of cases that develop the complication

Complication	Number of cases	Percentage
Revision	5	17.25%
Obstruction of distal end	3	10.34%
Migration of distal end	2	6.89%
Infection	0	0%
Viscus perforation	0	0%
Ascites	0	0%
Death	0	0%

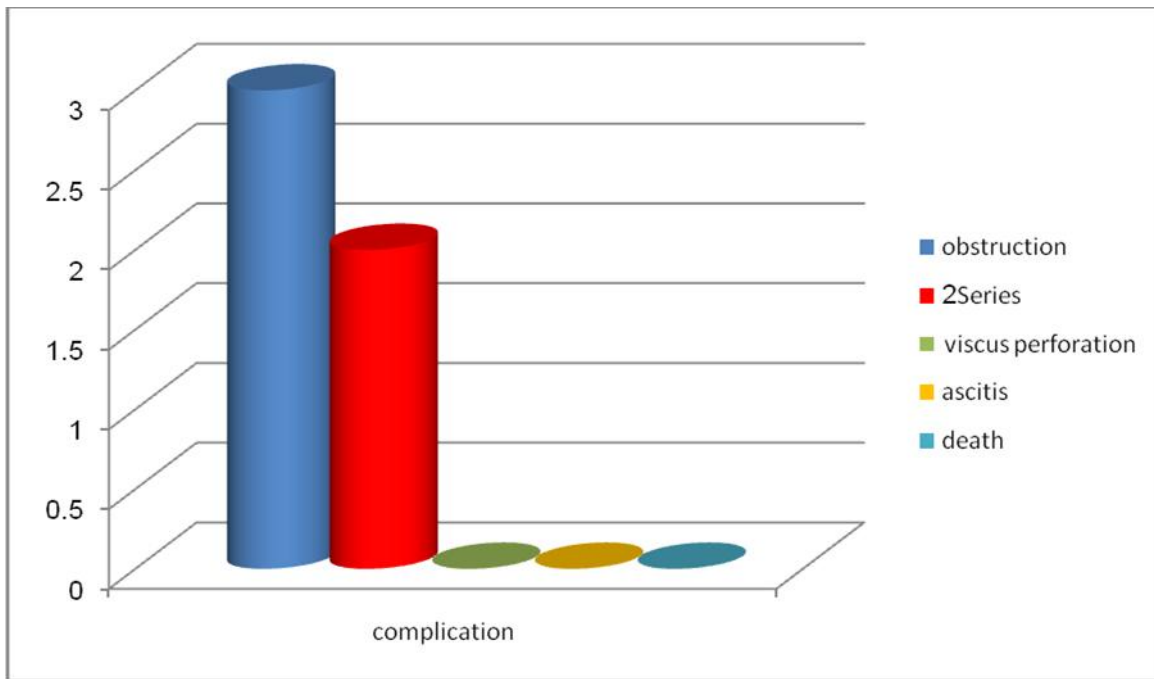


Figure (7) showing the complication of surgery in our study

Discussion

Pseudotumor cerebri is an idiopathic disorder defined by the modified Dandy criteria as the following: {28}

- 1) Signs and symptoms of raised ICP (headache, nausea, vomiting, transient obscuration of vision, and papilledema) .
- 2) Normal neurological examination, except for a sixth nerve palsy.
- 3) Elevated CSF pressure (>25cm H₂O) with normal constituents.

4) Modern neuroimaging, CT with and without contrast, or MRI demonstrating normal to small symmetrical ventricles and excluding a mass lesion or other cause of raised ICP.

It may be associated with menstrual irregularity or amenorrhoea and variously been reported as complication of Addisons disease with improvement after replacement therapy and as being more likely to occur when steroid dosage is reduced and relative adrenal insufficiency is present. {65}

The results as shown in our study that patient are usually females(28 from 30) 93.33%, similar results found in a study made by (Vincent Giuseffi, MD, Michael Wall, MD, Paul Z. Siegel, MD and Patricio B. Rojas, PhD) in which (90 %) 45 of 50 patients study was female.{53}

Only Johnston and Paterson in 1974 shows both genders are equally affected{54}.

The peak of age in our study was found to be in the second and 3rd decade of life, ten female patient was in the age between (20-29yrs) 33.3% from the total number and percentage of our study, and nine females and one male between the (30-39) years old 33.3% from the total number and percentage of our cases, compared to the study made by Brian in 1985 which shows that the peak incidence was found in the 4th decade of age.{55}

Also in our study we found 21 patient were complaining from obesity (70%), the same result found by Rowe FJ, Sarkies were 70.5% twenty four patient from thirty four patients were obese.{56}

Also Contreras-Martin Y, Bueno-Perdomo JH found similar result in a study of sixty one patient 72.13% of the patients were obese. {57}

Two female patients from twenty eight in our study(7.14%) was found using oral contraceptive pills which is important predisposing factor in pseudotumor cerebri in study of five cases by Horst A.& Rutten were receiving low dose contraceptive pills lead to aseptic dural sinus thrombosis.{58}

In our study the major complain was headache, found in 26 patients (86.6%),while González-Hernández A, Fabre-Pio Headache was present in 85.4% of their study of fifty five patient{59}

Also in retrospective study of twenty patient done by (Merle H, Smadja D, Ayeboua L, Cabre P, Gerard M, Alliot E, Rapoport P, Jallot-Sainte-Rose N, Richer R, Poman G.) sixteen patient 80% were complaining of headache as main presenting feature of pseudotumor cerebri.{60}

The second major complain in our study was visual disturbance which include decrease in visual acuity, blurring of vision, transient visual obscuration (T.V.O), These complains affected 19 (63.3%) patients in our study comparing in study performed by (Wall M, George D), in which 50 consecutive newly

diagnosed patients complain of transient visual obscurations affecting 36 patient (72%).{61}

Also in another retrospective study of 20 patient done by (Merle H, Smadja D, Ayeboua L, Cabre P, Gerard M, Alliot E, Rapoport P, Jallot-Sainte-Rose N, Richer R, Poman G.) fifteen patient show a loss of visual acuity (75%) and five patient shows transient visual loss (25%).{60}

Vomiting and dizziness were the third complain found in our patients (23%) and (13%) respectively, these symptoms are not specific and its related to elevated intracranial pressure.

CSF pressure via lumbar puncture was the investigation of choice for the diagnosis, and it shows that CSF pressure was elevated above 22cm H₂O, and this explains the papilledema formation and severity of the complains, papilloedema either directly or indirectly is the cause of visual loss in pseudotumor cerebri, the higher the grade of the papilledema, the worse the visual loss.

Papilledema due to increased intracranial pressure, is the cardinal sign of pseudotumor cerebri and found in all the patients in our study, similar results were found in prospective study of fifty patients done by Friedman DI, Jacobson DM. {3}

Two patients present to our department with severe visual disturbance only slight perception to light at time of presentation and one of the patient was male referred to our department already diagnosed with cerebral sinus thrombosis and both did not improve even after surgical intervention.

Computerized tomography scan(CT scan) was found to be very useful in defining the extent of brain normality and excluding any pathological abnormality, although small size ventricles was a common feature among our patients.

Computerized tomography scan(CT scan) and magnetic resonant image(MRI) was done for all the patient in our study to exclude space occupying lesions, three of our patients was further diagnosed by the use of magnetic resonant venogram (MRV) and magnetic resonance angiography (MRA) found to have venous sinus thrombosis..

Three patients in our study (10%) was found to have venous sinus thrombosis which undergo medical treatment with low molecular weight heparin and LP shunt, several case reports done by Gary Y. Shaw and

Stephanie K. Million notice that patients with venous sinus thrombosis present with headache and papilledema with normal (CT scan) findings but (MRV) shows venous sinus thrombosis an extensive work out shows these patient has Factor V Leiden mutation. {64}

The empirical therapy of elevated ICP due to pseudotumour cerebri include acetazolamide (Diamox), loop diuretics (furosemide), corticosteroids, repeated lumbar punctures, and lumboperitoneal shunting, which has the advantage of being completely extracranial surgical management, minimizing the intracranial complications, but in our study only one patient shows improvement in severity of headache and gradual disappearance of papilledema without the need of surgical intervention by lumboperitoneal shunt. {20}

Only one patient in our study improve using medical treatment (acetazolamide and furosemide corticosteroids and two repeated lumbar punctures and papilledema resolve in period between two days to one week.

Twenty nine patients in our study performed lumbar peritoneal shunt , twenty four patients had shown dramatic response in improving headache and visual outcome, five patients showed complications which is higher than expected from medical management, these complications include spontaneous obstruction of the distal end and immigration of the distal end of the catheter from the peritoneal cavity, in our study three cases shows spontaneous obstruction 10% compaired with other study done by (Waleed F. El-Saadany, Ahmed Farhoud, Ihab Zidan) in study of twenty two patient six of them (27%) developed shunt obstruction and required shunt revision. {62}

In other study performed by Eggenberger ER, Miller NR, Vitale Sa retrospective study of 27 patients with pseudotumor cerebri (PTC) treated with at least one lumboperitoneal shunt (LPS) Twelve patients (44%) required no revisions. The number of revisions among the 15 patients (56%) who required revisions due to failure of the shunt. {63}

The most important postoperative complain is headache, that is found to occur upon mobilization , this type of headache is a low pressure headache (over shunting) and was related to the fall of CSF pressure after shunting which is attributed to continued leakage of CSF through the catheter to the peritoneum.

The severity of headache reduced by tilting the patient's head down to the supine posture , thereby reducing CSF hydrostatic pressure in the subarachnoid space and thus reducing amount of CSF leakage to the peritoneum.

The use of intravenous fluid in the form of normal saline 9% was tried in some patients and show no significant difference in the headache after shunting.

Conclusion

Idiopathic intracranial hypertension is a disease with complex pathophysiological structure, which until now has not been fully clarified.

The plurality of possible etiologies is the reason why many different treatments have been developed with a variety of response from patient to patient. The diagnostic methodology of IIH must include LP, MRI and brain venography.

Treatment always begins with instructions to the patient for exercise, life style modification and weight loss especially for obese people.

Treatment by medication to reduce intracranial pressure with or without repeated lumbar puncture is of benefit in some patients .

CSF diversion is the surgery of choice in patients with refractory headache with or without papilledema and when vision is threatened optic nerve sheath fenestration must be performed.

while stent placement in venous sinuses should be the last resort when all previous treatment options for patients with radiologic and manometric confirmation of venous sinus stenosis have failed.

Recommendations

Potential agents that might cause or worsen P.T.C. (eg, tetracycline derivatives) should be discontinued, and treatment provided for comorbid diseases such as anemia if present.

We recommend counseling and/or treatment for weight loss in all obese patients with P.T.C.

We suggest the use of acetazolamide as the initial treatment of patients with P.T.C. due to documented CSF-pressure lowering effect, and little serious toxicity in patients, Furosemide or other diuretics may

provide an additional benefit to acetazolamide in patients who experience continuing symptoms on acetazolamide.

We recommend against prolonged corticosteroid treatment for treatment of IIH (we also suggest not using serial lumbar punctures for more than three attempts as a primary treatment modality for P.T.C. However, both short-term use of corticosteroids and serial lumbar punctures have been successfully used as short term temporizing measures in patients with rapidly progressive symptoms who are waiting more definitive surgical therapy.

For patients with progressing visual loss, we recommend surgical intervention with CSF shunting procedure and/or optic nerve sheath fenestration (ONSF). The choice of surgical procedure is individualized based upon available expertise and patient preference. We prefer CSF shunting procedure rather than optic nerve sheath fenestration for most patients because of better documentation of efficacy and a lower rate of severe side effects. However, headache response may be superior with shunting.

Patients require regular follow-up visits with serial examinations including visual acuity, formal visual field testing and a fundoscopic examination.

References

- 1) Ball AK, Clarke CE. Idiopathic intracranial hypertension. *Lancet Neurology*. 2006 page 5:433-442.
- 2) Foley J: Benign forms of intracranial hypertension: "toxic" and "otitic hydrocephalus.". *Brain* 1955 78:1-41
- 3) Friedman DI, Jacobson DM: Idiopathic intracranial hypertension: prospective study of 50 . *J Neuroophthalmology* 2004 24:138-145.
- 4) Johnston I, Hawke S, Halmagyi M, Teo C The pseudotumor syndrome. Disorders of cerebrospinal fluid circulation causing intracranial hypertension without ventriculomegaly *Arch Neurol*. 1991 Jul [pubmed] .
- 5) Bratton SL. Guidelines for the management of severe traumatic brain injury. Intracranial pressure thresholds. *J Neurotrauma*. 2007 {medscape.com}
- 6) Chapman PH, Cosman ER, Arnold MA. The relationship between ventricular fluid pressure and body position in normal subjects and subjects with shunts: a telemetric study. *Neurosurgery*. Feb 1990 [Medline].
- 7) Suarez J. *Critical Care Neurology and Neurosurgery*. 1. Humana Press; 2004 {medline}
- 8) Hedges TR. papilledema, its recognition and relation to increase I.C.P. *Survophthalmology* 2009 (medline)
- 9) Spelle, Boulin A, Tainturier C, Visot A, Graveleau P, Pierot L, neuroimaging features of spontaneous intracranial hypotension 2001 (medline)
- 10) Friedman DI, Jacobson DM, diagnostic criteria for I.I.H. 2002 PAGE 1492
- 11) Geeraerts T, Newcombe VF, Coles JP, et al. Use of T2-weighted magnetic resonance imaging of the optic nerve sheath to detect raised intracranial pressure. *Crit Care*. 2008 {medscape}
- 12) Mokri B: The Monro-Kellie hypothesis: Applications in CSF volume depletion. *Neurology* 56:1746-1748, 2001
- 13) Donaldson JO: Pathogenesis of pseudotumor cerebri syndromes. *Neurology* 31:877-880, 1981
- 14) Sorensen PS, Thomsen C, Gjerris F, Schmidt J, Kjaer L, Henriksen O: Increased brain water content in pseudotumour cerebri measured by magnetic resonance imaging of brain water self diffusion. *Neurol Res* 11:160-164, 1989
- 15) Karahalios DG, ReKate HL, Khayata MH, Apostolides PJ: Elevated intracranial venous pressure as a universal mechanism in pseudotumor cerebri of varying etiologies. *Neurology* 46:198-202, 1996
- 16) Fraser JA, Bruce BB, Rucker J, Fraser LA, Atkins EJ, Newman NJ, et al. Risk factors for idiopathic intracranial hypertension in men: a case-control study. *J Neurology Science*. Mar 15 2010 {medscape}
- 17) Radhakrishnan K, Thacker AK, Bohlaga NH, Maloo JC, Gerryo SE. Epidemiology of idiopathic intracranial hypertension: a prospective and case-control study. *J Neurology Science*. May 1993;116(1):18-28. [Medline].
- 18) Bateman GA, Stevens SA, Stimpson J. A mathematical model of idiopathic intracranial hypertension incorporating increased arterial inflow and variable venous outflow collapsibility. *Journal of Neurosurgery* . Mar 2009;110(3):446-56. [Medline].
- 19) Doyle DJ, Mark PWS: Analysis of intracranial pressure. *J Clinical Monitoring* 8:81, 2008
- 20) Wall M, George D: Idiopathic intracranial hypertension: a prospective study of 50 patients. *Brain* 1991
- 21) Wall M. Idiopathic intracranial hypertension (pseudotumor cerebri). *Current Neurological Neuroscience Rep*. Mar 2008;8(2):87-93. [Medline]

- 22) Digre K: Idiopathic intracranial hypertension headache. *Current Pain Headache Report* 2002; 6:217-225.
- 23) Panagiotis kerezoudis, Evangelos anagnostou, Evangelia kararizou: idiopathic intracranial hypertension: update on the pathogenesis, clinical features and therapy 2013
- 24) Rowe FJ: Ocular motility disturbances in benign intracranial hypertension. *Br Orthop J* 1996; 53:22-24
- 25) Felton WL, Sismanis A: Otolgic aspects of idiopathic intracranial hypertension in patients with and without papilledema. *Neuroophthalmology* 1996; 16(suppl):279.1996
- 26) Corbett JJ: Problems in the diagnosis and treatment of pseudotumor cerebri. *Can J Neurol Sci* 1983
- 27) From Frisé L. Swelling of the optic nerve head: a staging scheme. *J Neurology Neurosurgery Psychiatry*. 1982;45:13-18.
- 28) Digre KB, Corbett JJ: Idiopathic intracranial hypertension (pseudotumor cerebri): A reappraisal. *Neurology* 7:2-67, 2001.
- 29) Levine DN. Ventricular size in pseudotumor cerebri and the theory of impaired CSF absorption. *J Neurological Scociety* 2000;177:85-94
- 30) Stone MB. Ultrasound diagnosis of papilledema and increased intracranial pressure in pseudotumor cerebri. *Am J Emerg Med*. Mar 2009;27(3):376.e1-376.e2. [Medline].
- 31) Agid R, Farb RI, Willinsky RA, Mikulis DJ, Tomlinson G. Idiopathic intracranial hypertension: the validity of cross-sectional neuroimaging signs. *Neuroradiology*. Aug 2006;48(8):521-7. [Medline].
- 32) Maralani PJ, Hassanlou M, Torres C, Chakraborty S, Kingstone M, Patel V, et al. Accuracy of brain imaging in the diagnosis of idiopathic intracranial hypertension. *Clin Radiol*. Jul 2012;67(7):656-63. [Medline].
- 33) Degnan AJ, Levy LM. Pseudotumor cerebri: brief review of clinical syndrome and imaging findings *AJNR Am J Neuroradiol*. 2011 Dec
- 34) Çelebisoy N, Gökçay F, Sirin H, et al: Treatment of idiopathic intracranial hypertension: topiramate vs acetazolamide, an open-label study. *Acta Neurol Scand* 2007; 116:322-327. treatment of pseudotumor cerebri Youmans neurosurgery 6th edition page 1707
- 35) Devin K. Binder, Jonathan C. Horton, Michael T. Lawton, Michael W. McDermott, Idiopathic intracranial hypertension literature review April 11, 2003.
- 36) Baker RS, Baumann RJ, Buncie JR. Diagnosis and management of benign intracranial hypertension 1998 {MEDLINE}
- 37) Nampooray MR, Johnny KV, Gupta RK, Constandi JN, Nair MP, al-Muzeiri I. Treatable intracranial hypertension in patients with lupus nephritis 1997;6(7):597-602. [Medline].
- 38) Leker RR, Steiner I. Anticardiolipin antibodies are frequently present in patients with idiopathic intracranial hypertension. *Arch Neurol*. Jun 1998;55(6):817-20. [Medline].
- 39) Sussman J, Leach M, Greaves M, Malia R, Davies-Jones GA. Potentially prothrombotic abnormalities of coagulation in benign intracranial hypertension. *J Neurology Neurosurgery Psychiatry*. Mar 1997;62(3):229-33. [Medline]
- 40) Mark S Gans, Robert A Egan, MD, Robert A Egan Idiopathic Intracranial Hypertension Workup Apr 1, 2013 [Medscape]
- 41) D Soler, T Cox, P Bullock, D M Calver, R O Robinson Diagnosis and management of benign intracranial hypertension 1998 updated on January 5, 2014 [british medical journal(BMJ)]
- 42) Yadav YR, Parihar V, Agarwal M, Bhatele PR, Saxena N. Lumbar peritoneal shunt in idiopathic intracranial hypertension. *Turk Neurosurg*. 2012;22(1):21-6. [Medline].
- 43) Brazis PW. Clinical review: the surgical treatment of idiopathic pseudotumour cerebri (idiopathic intracranial hypertension). *Cephalalgia*. Dec 2008;28(12):1361-73. [Medline].
- 44) Burgett RA, Purvin VA, Kawasaki A. Lumboperitoneal shunting for pseudotumor cerebri. *Neurology*. Sep 1997;49(3):734-9. [Medline].
- 45) Sinclair AJ, Kuruvath S, Sen D, Nightingale PG, Burdon MA, Flint G. Is cerebrospinal fluid shunting in idiopathic intracranial hypertension worthwhile? A 10-year review. *Cephalalgia*. Dec 2011. [Medline].
- 46) Goh KY, Schatz NJ, Glaser JS. Optic nerve sheath fenestration for pseudotumor cerebri. *J Neuroophthalmology* . Jun 1997;17(2):86-91. [Medline].

- 47) Agarwal MR, Yoo JH: Optic nerve sheath fenestration for vision preservation in idiopathic intracranial hypertension. *Neurosurg Focus Neurosurg Focus* 2007; 23(5):E7
- 48) Nithyanandam S, Manayath GJ, Battu RR. Optic nerve sheath decompression for visual loss in intracranial hypertension: report from a tertiary care center in South India. *Indian J Ophthalmol.* Mar-Apr 2008;56(2):115-20. [Medline]
- 49) Schmidek and Sweet Operative Neurosurgical Techniques: Indications, Methods, and Results 6th edition, by Alfredo Quiñones-Hinojosa
- 50) Bussière M, Falero R, Nicolle D, et al. Unilateral transverse sinus stenting in patients with idiopathic intracranial hypertension. [AJNR 2010]
- 51) Farb RI, Vanek I, Scott JN, et al: Idiopathic intracranial hypertension. The prevalence and morphology of sinovenous stenosis. *Neurology* 2003
- 52) Sorensen PS, Thomsen C, Gjerris F, Schmidt J, Kjaer L, Henriksen O: Increased brain water content in pseudotumor cerebri measured by magnetic resonance imaging of brain water self diffusion. *Neurological Res* 11:160–164, 1989.)[medline]
- 53) Vincent Giuseffi, MD, Michael Wall, MD, Paul Z. Siegel, MD and Patricio B. Rojas, PhD) [official journal of American academy of neurology feb 1991
- 54) Johnston I and Paterson A, benign intracranial hypertension diagnosis and prognosis. *Brain* (1974) , june 1997[pubmed]
- 55) Brain K Owler (benign intracranial hypertension ,disease of nervous system 9th edition London walter oxford medical publication Brain page 363 1985
- 56) The relationship between obesity and idiopathic intracranial hypertension. Rowe FJ, Sarkies NJ 1999 Jan;23.[PUBMED]
- 57) Idiopathic intracranial hypertension: Descriptive analysis of 61 patients done by Contreras-Martin Y, Bueno-Perdomo JH performed 2013 Dec 11[pubmed]
- 58) horst and ruttner (aseptic cerebral sinus thrombosis),schweiz-wochenschr:1991(english abstract) page 1991.
- 59) González-Hernández A, Fabre-Pi O, Díaz-Nicolás S, López-Fernández JC, López-Veloso C, Jiménez-Mateos A.(Headache in idiopathic intracranial hypertension) 2009 Jul 1-15[Pubmed]
- 60) Merle H, Smadja D, Ayeboua L, Cabre P, Gerard M, Alliot E, Rapoport P, Jallot-Sainte-Rose N, Richer R, Poman G. benign intracranial hypertension retrospective study of 20 patient 1998 Jan;21[pubmed]
- 61) Wall M, George D.: Idiopathic intracranial hypertension. A prospective study of 50 patients. 1991 Feb
- 62) Waleed F. El-Saadany, Ahmed Farhoud, Ihab Zidan (Lumboperitoneal shunt for idiopathic intracranial hypertension: patients' selection and outcome) *Neurosurgical Review* April 2012 [springer link] {IVSL}
- 63) Eggenberger ER, Miller NR, Vitale S : Lumboperitoneal shunt for the treatment of pseudotumor cerebri.. *Neurology.* 1996 June [pubmed]
- 64) Gary Y. Shaw and Stephanie K. Million :Case Report Benign Intracranial Hypertension: A Diagnostic Dilemma 12 July 2012[pubmed]
- 65) Leggio MG, Cappa A, Molinari M, Corsello SM, Gainotti G: Pseudotumor cerebri as presenting syndrome of Addisonian crisis. *Ital J Neurol Sci* 1995, 16(6):387-389.
- 66) Exogenous Substances Whose Exposure, Ingestion, or Withdrawal Has Been Associated with Pseudotumor Cerebri table 150-4 chapter 150 youman's 6th edition page 1707
- 67) Systemic Illnesses Associated with Pseudotumor Cerebri table 150-5 chapter 150 youman's 6th edition page 1707
- 68) Endocrine and Metabolic Disturbances Associated with Pseudotumor Cerebri table 150-3 chapter 150 youman's 6th edition page 1706
- 69) Causes of Obstruction/Impairment of Cerebral Venous Drainage Associated with Secondary Pseudotumor Cerebri table 150-2 chapter 150 youman's 6th edition page 1706
- 70) Panagiotis kerezoudis, Evangelos anagnostou, Evangelia kararizou: idiopathic intracranial hypertension: update on the pathogenesis, clinical features and therapy 2013
- 71) Papilledema Grading System (Frisén Scale) TABLE 150-1 chapter 150 youman's 6th edition page 1702
- 72) Stages of papilledema according to the Frisén grading scale FIGURE 150-3 chapter 150 youman's 6th edition page 1703

73) PRACTICAL NEUROLOGY Idiopathic
intracranial hypertension C. J. Lueck and G. G.
McIlwaine PAGE 264 OCTOBER 2002

Access this Article in Online	
	Website: www.ijarbs.com
	Subject: Medical Sciences
Quick Response Code	
DOI: 10.22192/ijarbs.2017.04.09.011	

How to cite this article:

Ibrahim Yassin Hussein. (2017). Pseudotumor cerebri - Clinical presentation, Surgical management and outcome. Int. J. Adv. Res. Biol. Sci. 4(9): 83-100.

DOI: <http://dx.doi.org/10.22192/ijarbs.2017.04.09.011>