



Gross and Histopathological Observations of Commercial Broiler Chicks Experimentally Infected with Pure *Eimeria tenella*, *E. acervulina* and Mixed isolated *Eimeria* spp

Samrawit Melkamu¹, Mersha Chanie² and Mulat Asrat³

¹School of Veterinary Medicine, Samara University, ETHIOPIA

²Faculty of Veterinary Medicine, University of Gondar, Ethiopia

³School of Veterinary medicine, Wollo University, Ethiopia

Corresponding author: M Samrawit: Email: amarech05@gmail.com

Abstract

An experimental study was conducted at University of Gondar from November 2015 to April 2016. The objective of this study was to evaluate the pathogenicity, gross and histopathological lesion of coccidiosis in broiler chickens. One hundred commercial one day old broiler chicks, unvaccinated against coccidiosis, was used during this experiment. At day 14, chickens of G1 (n=25), G2 (n=25) and G3 (n=25) were infected with 2×10^4 sporulated oocysts of *E. tenella*, *E. acervulina* and mixed *Eimeria* spp. respectively; G4 (n=25) served as the uninfected control group. Fifteen birds were sacrificed in each group with seven days after infection. The prepatent period for *E. tenella* (G1) and mixed *Eimeria* spp (G3) was five days, however, *E. acervulina* (G2) had prepatent period of four days. The observed pathological lesion score ranged from +1 to +4 were recorded in infected chickens. Chickens infected in *E. tenella* showed sever lesion score when compared to other infected groups. The histopathological findings infected chickens were showed different stages of parasite, villous atrophy, severe inflammation, mononuclear inflammatory cell infiltrated, sever haemorrhagic areas.

Keywords: Broilers, Coccidiosis, *Eimeria*, Pathogenicity

Introduction

Coccidiosis is essential disease of poultry under intensive management condition caused by a protozoan parasite known as *Eimeria*. A mild coccidian infection due to non-pathogenic or low dose of pathogenic *Eimeria* oocysts is not harmful and creates flock immunity against coccidiosis. A severe attack of coccidiosis can however cause weight losses, morbidity and mortality (Sharma *et al.*, 2013). Coccidiosis in chickens is one of the most costly diseases affecting the poultry industry worldwide. It is an intestinal parasitic disease caused by intracellular

protozoan parasites of the genus *Eimeria* (Nematollahi *et al.*, 2009). The infection inflict severe economic loss due to extensive destruction of the enteric epithelium resulting in reduction of feed conversion, body weight gain and egg production (Morris & Gasser, 2006).

The disease is endemic in most of the tropical and subtropical regions where ecological and management conditions favour an all-year round development and propagation of the causal agent (Obasi *et al.*,

2006). This disease is caused by *Eimeria* parasites, which infect epithelial cells of the intestines of birds. Clinically, coccidiosis is manifested by bloody diarrhoea and listlessness; economic losses are primarily due to impaired feed conversion, depressed growth, loss of pigmentation, downgrading at processing, and mortality. In this study, the gross and histopathological observations of pre *E. tenella*, *E. acervulina*, and mixed *Eimeria* spp were evaluated in experimentally infected commercial broiler chicks (Ali tipu *et al.*, 2002).

The characteristics of post-mortem lesions of coccidia infected chicken are based on location of the intestinal tract, appearance and severity, the nature of intestinal contents and other associated gross changes which can be useful in establishing a diagnosis (Conway and McKenzie, 2007). Lesions of the intestinal mucosa and loss of pigmentation may also become apparent during the latter stages of infection (Amer *et al.*, 2010). The purpose of this study was to study the pathogenicity, gross and histopathological lesion of coccidiosis in broiler chickens infected with *Eimeria* spp.

Materials and Methods

Study area

The experimental study was conducted in the Faculty of Veterinary Medicine at the premises of Tewodrose Campus, University of Gondar. The area is found in Amhara National Regional State, located in the north-western part of Ethiopia, (12.3° to 13.38° north latitudes and 35.5° to 38.3° east longitudes) (NMA, 2011). The research was conducted from November 2015 to April 2016.

Experimental animals and grouping

One hundred day-old Ross broiler breed chickens were purchased for this experiment from Alema, a private commercial broiler farm, Debre Zeit, Ethiopia. Unsexed day old chickens were randomly and equally allocated into four groups. All groups were maintained at the same management system. The chickens were reared for eight weeks in separate room under strict biosecurity measures and no vaccine was used during the study period. On the start of the experiment the birds were tagged with identification numbers on their wing and leg in each group.

Housing and management of experimental chickens

In this study, day-old chickens were kept with floor housing system. The house, feeder, water utensils were thoroughly cleaned, disinfected prior to stocking of chickens. The utensils were also cleaned daily to avoid reinfection and contamination. Thus, the chickens were reared under strict coccidia free conditions through repeated cleaning and disinfection. Chickens were fed ad libitum on a commercial broiler starter, grower and finisher diet based on their ages throughout the period of the experiment. Continuous heating program with 120 watt bulbs were suspended at head height of the birds. The amount of temperature present in the house was measured and recorded by thermometer and the heat released from brooder was adjusted based on the age of chickens from suspended height. The temperature was maintained at 29-31°C for the first week and was reduced by 1-3°C on weekly basis. Bio-safety of chickens was maintained in study area through fenced farm, protected against wild animals and using footbath. The experimental house had gate and there were special store for feed, disinfectant, personal protective equipment's and closing for the researchers and assistance. The current experiment was conducted with the approval of university of Gondar ethical review board. The experiment was conducted based on the international guidelines of animal experimentation and handling where they were fed ad libitum. The board approved the protocol to be done.

Experimental design and inoculation of sporulated oocysts

The experimental design used for this research was completely randomized design. The experimental animals (n=100) were randomly allocated into four equal groups: group one (G-I), group two (G-II), group three (G-III) and group four (G-IV) with 25 chickens in each group. The G-I, G-II, and G-III were treatment groups challenged by different *Eimeria* sporulated oocysts, while G-IV served as the control group. All chickens were maintained until the 10th day of age the experiment with a ration containing anticoccidial additives following the recommended producer. After the 10th days of age, the chickens were fed on a ration without anticoccidial additives until the end of experiment. Ad libitum provision of feed and water were maintained. Faecal material from each group was examined at 10th and 21th days of age before the infection, to ensure that the chickens were free from coccidia or other parasitic diseases. Additionally,

blood examination was conducted for the detection of pathogenic bacterial agents. One bird from each group was sacrificed and examined to confirm the absence of any parasitic stage of *Eimeria* species and other pathological lesions at 21th day of age.

The treatment groups of chickens (G-I, G-II, G-III) were infected artificially infected with sporulated *Eimeria* oocysts at the age of three weeks as described by You (2014). They were infected orally with infective dose of 2×10^4 sporulated oocysts of *E. tenella*, *E. acervulina* and field isolated mixed *Eimeria* oocysts. The G-I chickens were infected with *E. tenella*, G-II with *E. acervulina* and G-III with mixed *Eimeria* spp. (*E. acervulina*, *E. tenella*, *E. necatrix* and *E. maxima*). G-IV was remained as uninfected control groups.

Preparation of infective *Eimeria* species for the experiment

Pure culture *E. tenella*, *E. acervulina* and mixed identified *Eimeria* species were used for this experiment. The pure cultures of *E. tenella* and *E. acervulina* were acquired from India. The mixed *Eimeria* species were identified from the naturally infected chickens. For identification of these mixed species, oocysts were collected from a total of 22 local and koeykoey breed chickens of different sex and ages of clinically coccidiosis suspected chickens were purchased from Gondar town and donated from Kombolcha poultry research and multiplication centre. The chickens were sacrificed in the laboratory at post-mortem room by cervical dislocation using the technique described by Zander (1999). The gastrointestinal tract was grossly examined carefully. Intestinal contents from the respective sections of intestine with lesions were collected. The floatation technique using sodium chloride solution was applied to harvest oocysts (Bowman, 2003).

The harvested *Eimeria* oocysts were identified by a combination of oocyst size, location in the gut and appearance of the lesions (McDougald and Fitz-Coy, 2008). The different species of *Eimeria* were identified according to the length, width and shape index of the individual oocyst after measuring 50 oocysts in each positive sample using a calibrated ocular microscope (McDougald, 2003).

The identified *Eimeria* spp oocysts were spread out in shallow Petri dish containing 2.5% potassium dichromate ($K_2Cr_2O_7$) solution and incubated with a

temperature 29°C, with adequate oxygen and humidity to allowed sporulation as describe by Conway and McKenzie (2007). The sporulation of the oocyst was confirmed by taking a drop of the mixture starting from the second day of incubation and examined for the presence of sporocysts under the microscope. The sporulated oocysts were collected and preserved in 2.5% $K_2Cr_2O_7$ and stored at 4°C. The sporulated oocysts were counted using the McMaster method (Holdsworth *et al.*, 2004).

Gross lesion examination and lesion scores

Randomly selected 10 chickens from each group were sacrificed through cervical dislocation. On the 7 DPI, post-mortem examination was conducted on the sacrificed birds for the presence of gross lesions consistent with coccidiosis. The intestinal tract was thoroughly examined for gross pathological changes as described by (Lobago *et al.*, 2005; Gari *et al.*, 2008). The observed lesions were assigned lesion scores from 0 to +4. The lesion score zero represents absence of lesion and lesion score +4 is for very severe intestinal/cecal mucosa lesion due to coccidia infection (Duffy *et al.*, 2005).

Histopathological examination

Intestinal and cecal segments were thoroughly examined and the segment which revealed lesion tissue samples were taken and fixed in 10% buffered formalin solution and processed for histopathological evaluation. The tissues were trimmed and processed by automatic tissue processor dehydrated in different chambers containing different alcohol concentrations. The processed tissues were cleared in xylene and embedded in paraffin for preparation into fine blocks. Finally blocks with a 5 µm size, transverse and longitudinal tissues section were made and stained with H and E stain (Talukder, 2007).

Results

An experimental trial for *Eimeria* spp. infection in chickens was conducted to evaluate the gross and histopathological changes and its gross lesion score.

Post mortem lesion and its score

Gross pathological examination of infected groups showed different lesions in different intestinal segments depending on the type of inoculated sporulated *Eimeria* spp. On 7 DPI extremely

ballooned and petechial haemorrhages were easily seen on the serosal surface of intestine. Any pathological changes were not observed in the intestines and caecum contents of all non-infected control chickens. *E. acervulina*, *E. tenella* and mixed *Eimeria* spp. caused different lesion in the duodenum, caecum, duodenum and mid gut respectively. The observed pathological lesion score ranged from +1 to +4 were recorded in infected chickens. Among the three experimentally infected chickens G-I showed sever lesion score when compared to their infected groups. The gross lesion and lesion score of chickens during the experimental period were illustrated in (figures 1).

The post mortem lesion in *E. tenella* infected chickens revealed extremely ballooned intestine, and petechial haemorrhages easily seen while looking grossly without opening the gut. However, discrete haemorrhagic spots were also observed on the mucous membrane of caecum when opened. Caecum was often found, thickened, showing necrosis and sloughing of epithelium, enlargement of caecum with clotted blood, haemorrhagic corrugated mucosa, dilation of caecum with consolidation of caecal contents were observed. Lesion score ranged from + 1 to + 4 on 7DPI.

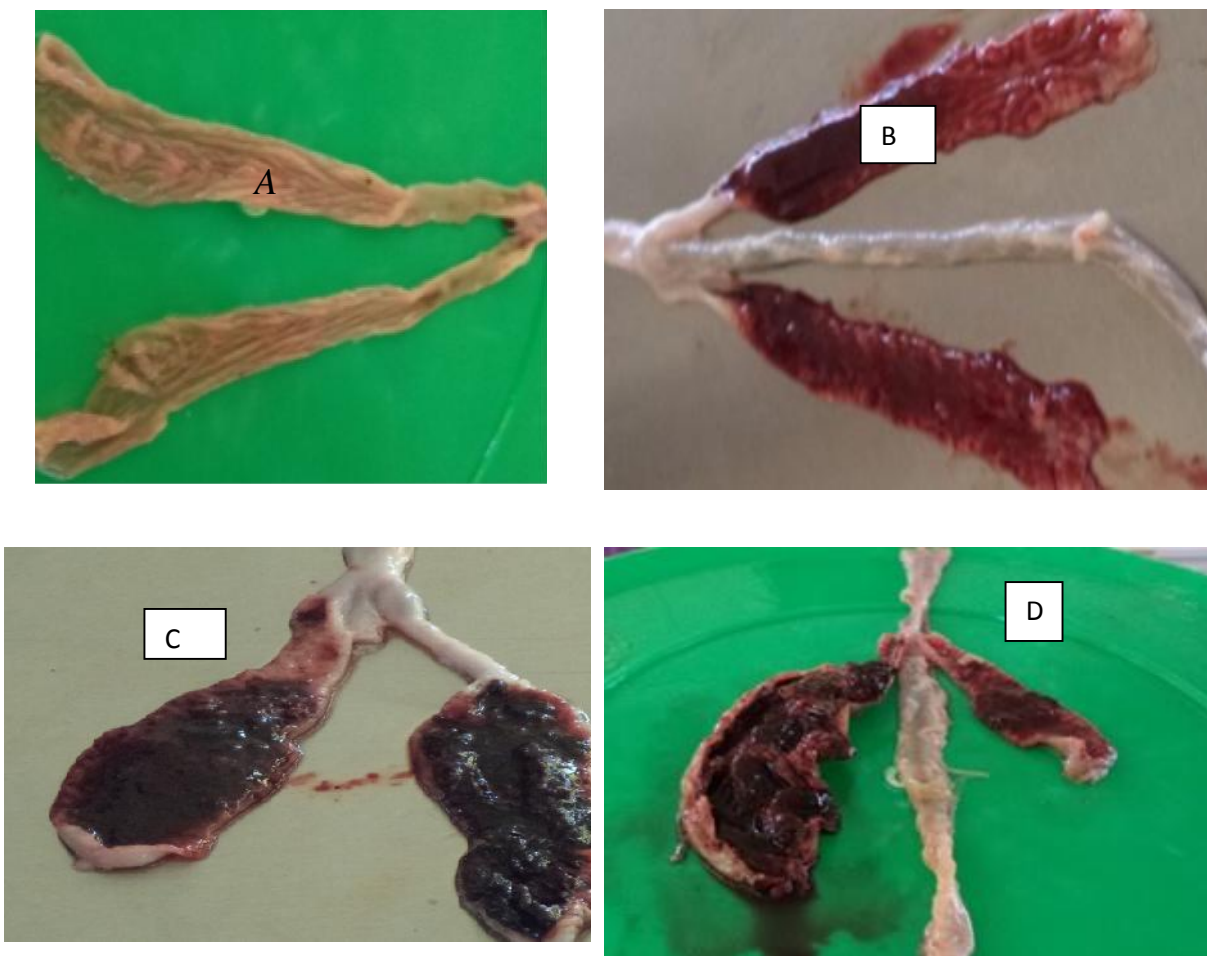


Figure 1. Gross pathological lesions of caecum in *E.tenella* infected chickens showing different lesions and lesion score. Normal caecum, lesion score 0(A), Haemorrhagic and thickened wall of caecum with grooves, lesion score +1(star) (B), Thickened caecal wall with blood, lesion score +3 (star) (C), Club-shaped, distended lumen filled with clotted blood, lesion score +4 (star) (D).

The gross lesion in *E. acervulina* infected chickens (G-II) showed, ballooning and hyperemic duodenum, creamy contents in the lumen, pin point necrotic foci, whitish transverse streak (ladder like lesion) in the mucosa and serosa, thickened and bright red mucosal

wall, lumen filled with blood were seen. The lesion score ranged from + 1 to +4 based on the severity of the lesion on 7 DPI but the majority of the lesion scored under lesion score +2.

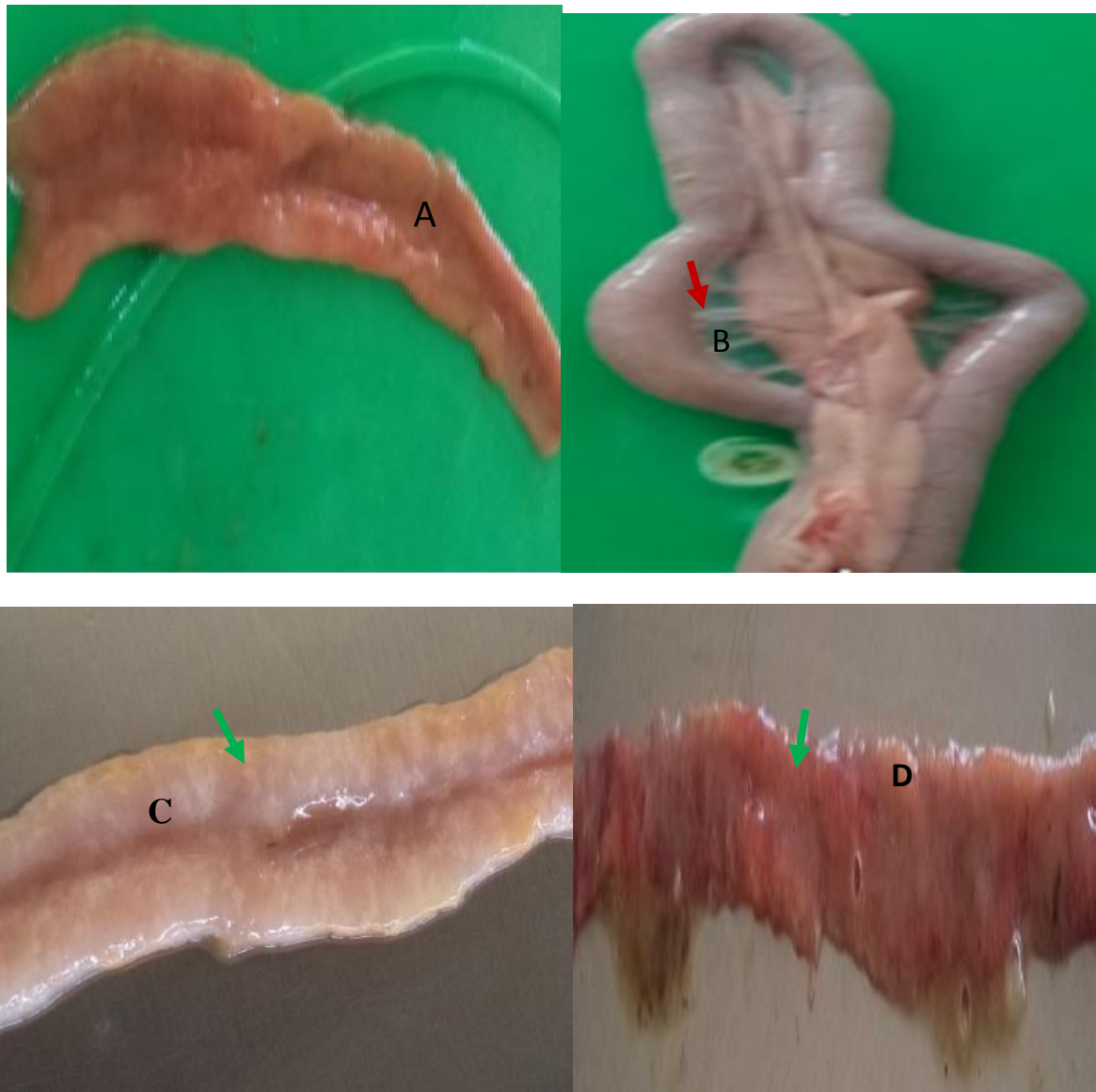

Figure 1. Gross pathological lesion of *E. acervulina* infected in chickens showing different lesions and its lesion score. Control chicken duodenum (lesion score 0) (A), extrim ballooned duodenal loops (arrow) (B), white pinpoint ladder like mucosal lesion, lesion score +3 (arrow) (C), haemorrhagic enteritis, bloody exudate, necrotized duodenal lumen, lesion score +4 (arrow) (D).

The gross lesion in mixed *Eimeria* species infected group on 7 DPI post mortem revealed petechial haemorrhagic mucosa in the mild gut, discrete haemorrhagic spots on the jejunum mucosa, ballooned with orange like mucus mixed fluid in the mid gut and distended duodenum with blood. Distended caecum with bloody faeces and mucoid debris along with

haemorrhages on the mucosa, blood field caecal lumen and thick caecal mucosa was observed. The lesion score in mixed infection were mild compared with other infected groups, it ranged from +1 to +3. G-IV, in this study no gross lesion were seen on 7 DPI post mortem.

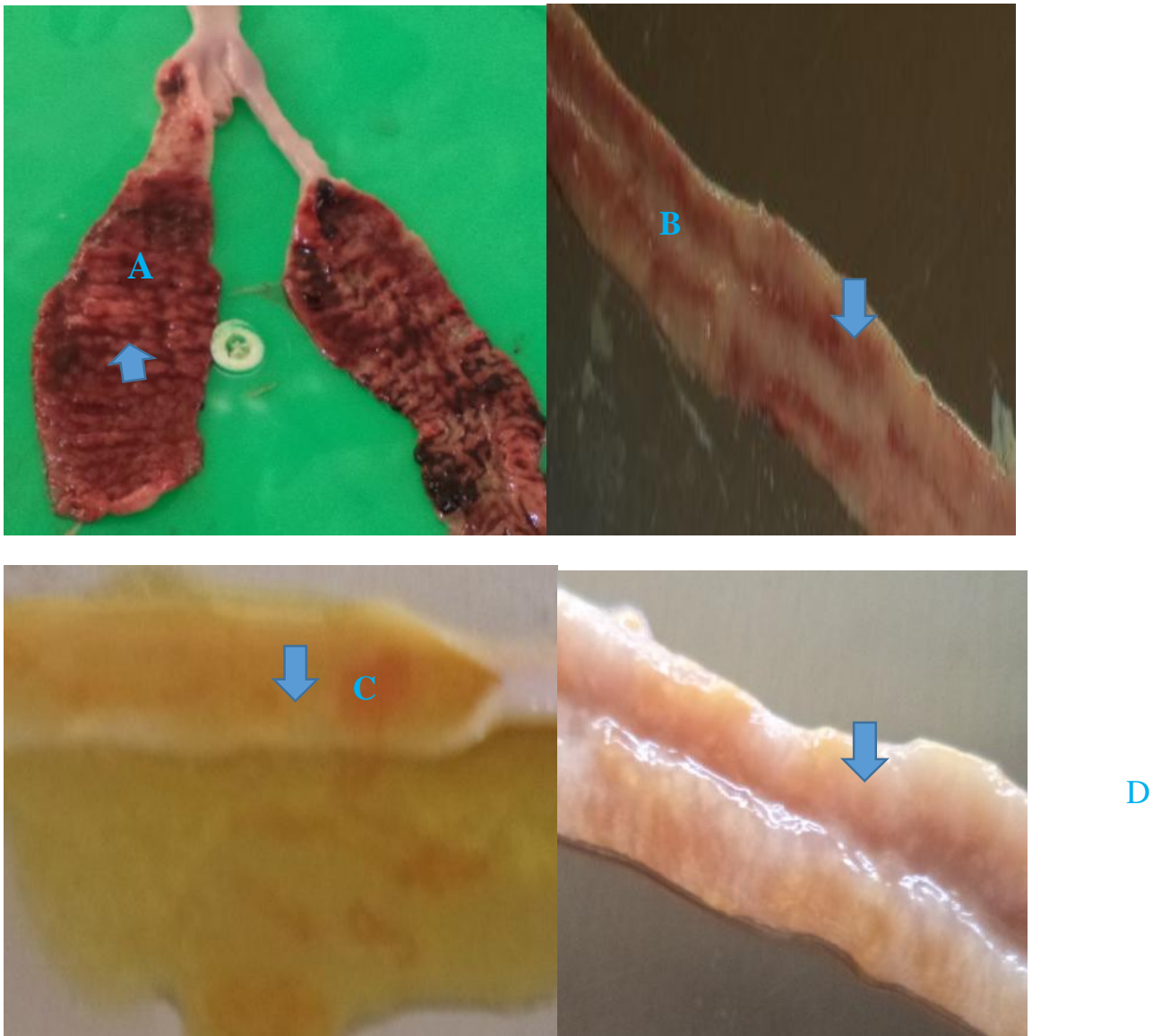


Figure 2. Gross pathological lesions of small intestine in infected with mixed *Eimeria* Spp. showed different lesions with its lesion score. Corrugated, thickened and haemorrhagic cecal mucosa and its lesion score +3 (arrow) (A), ecchymotic haemorrhagic jejunum mucosa, lesion score +2 (arrow) (B), petechial haemorrhage, orange like fluid in the lumen and thickened ileum mucosa (arrow) (C), Very thickened and pi point white lesion in duodenal mucosa (D).

Table 1. Gross lesion score in G-I, G-II, G-III and G-IV chickens sacrificed on 7 DPI

Group	No	Species	Lesion score				
			0	+1	+2	+3	+4
G-I	10	<i>E. tenella</i>	0	1	2	4	3
G-II	10	<i>E. acervulina</i>	0	2	4	2	2
G-III	10	Mixed <i>Eimeria</i> spp	0	4	3	3	0
G-IV	10	Control	10	0	0	0	0

Histo
patho
logic
al

Histopathological examination

examination of tissue sections on 7 DPI in G-I, G-II and G-III experimentally infected with different

Eimeria spp. which revealed the developmental stages of *Eimeria* spp. in cecum, duodenum, jejunum and ileum, respectively. Histopathological lesions of all experimental infected chickens were examined on the 7DPI. The major

parasite, villous atrophy, severe inflammation, mononuclear inflammatory cell infiltrated, marked proliferation of epithelial cells of intestinal crypts, dilation, necrosis of submucosal glands, multifocal areas of severe haemorrhagic areas, plenty of oocysts and schizonts in lamina propria and desquamation of epithelium, thickened mucosa and sub mucosal layer with slightly congestion of blood vessel which indicated disruption followed by leakage of blood, severe muscular oedema.

tabulated histopathological findings in G-I (*E.tenella*) infected chickens were showed different stages of

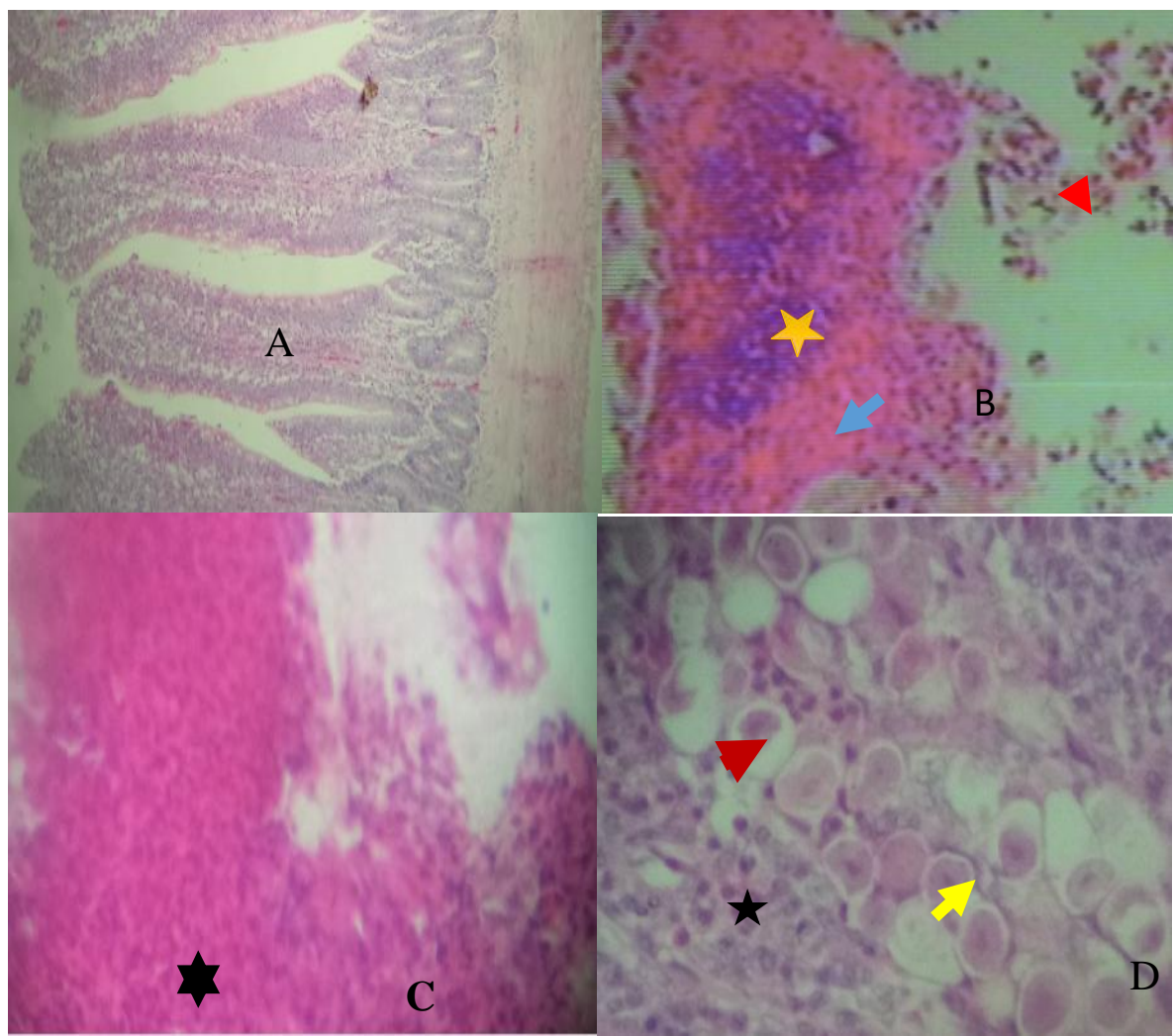


Figure 3. Histopathological observations on 7 DPI in *E. tenella* infection chickens. Control group caecum (A), inflammatory cells aggregation (yellow star), severe haemorrhage (arrow) and disintegrated villi (arrow head) (B). Severe haemorrhagic area in mucosa on 7 DPI (star) (C), Great number of oocysts (red arrow head) and schizonts (yellow arrow) and aggregated inflammatory cell (star) on 7 DPI (D) (H-E 100x).

Microscopically, lesions induced by *E. acervulina* (G-II) were principally characterized by hyperplastic epithelial mucosa with dilation of goblet cells, epithelial desquamation, infiltrated inflammatory cells in lamina propria, moderate villous atrophy and

fusion, discrete haemorrhage, foci of concentrated mononuclear infiltrate at the submucosa layer, discrete oedema at the submucosa muscularies associated with various intralesional forms of the parasite within epithelial cells (figure 5).

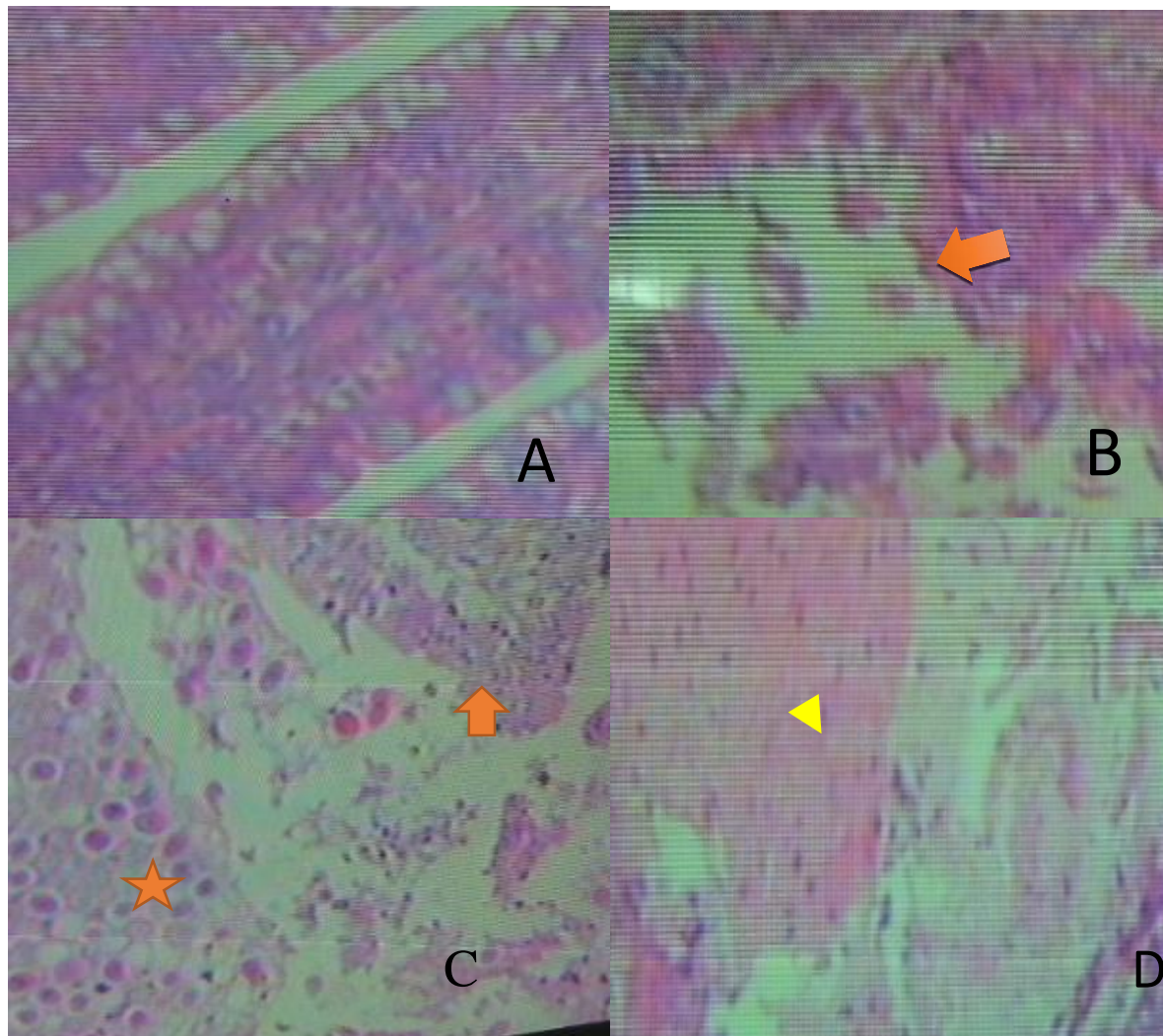


Figure 4. Histopathological observations on 7 DPI with *E. acervulina* infection in chickens. Control chicken duodenum (A). Disintegrated of villi (arrow) (B), atrophied villi (red arrow) and plenty of schizonts and oocysts with disintegrated villi (star) (C), necrosis of tissue in mucosal layer (arrow head) (D). (H-E 100x).

Microscopic lesion of mixed infection were discrete villous atrophy, proliferation of epithelial cells, focal haemorrhagic areas, presence of parasite at the villi, congestion in the blood veins, infiltration of

mononuclear cells and dilation of mucosal glands associated with parasite in various stages of development in the intestine (duodenum, jejunum and cecum).

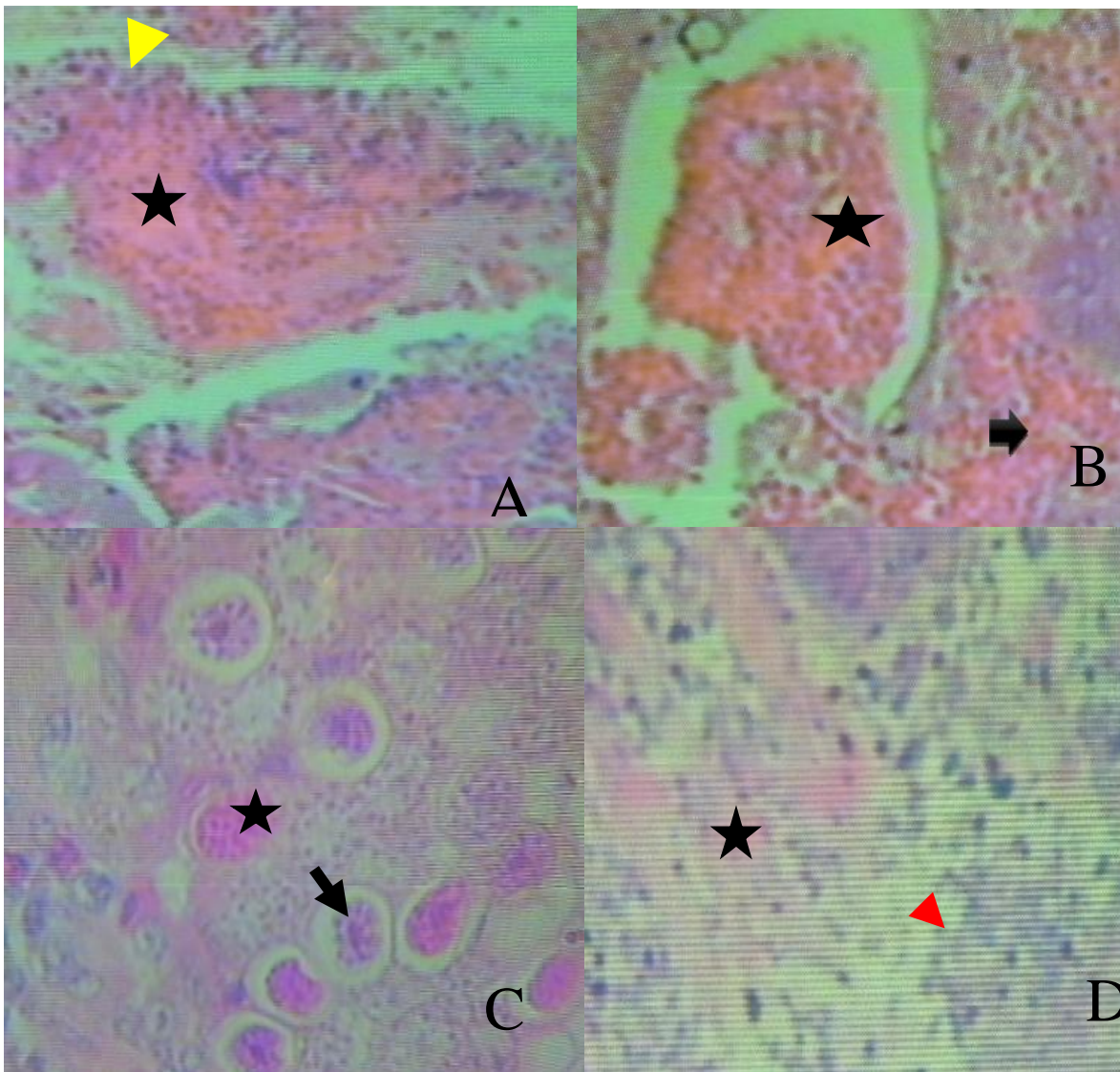


Figure 5. Histopathological lesion in small intestine in mixed *Eimeria* spp infected chickens at sacrificed on 7 DPI. Haemorrhage (star) and infiltration of inflammatory cells (arrow head) in the sub mucosa (A) Congestion (star) and focal haemorrhage (arrow) in the muscularis (B). Several number of oocyst (arrow) and schizonts (star) in the mucosa of ileum (C) (400x), Necrosis (star) and oedema (arrow head) in the sub mucosal layer of ileum (D) (H-E 100x).

Discussion

In the present study, the most common post mortem lesions of *E. tenella* infection were manifested by petechial to severe haemorrhage in the cecal wall, ballooning and thickened caecal loops of mucosa, enlargement of caecum with clotted blood, caecum filled with blood, complete ballooning with blood cores formation, haemorrhagic corrugated mucosa. This characteristic feature of *E. tenella* infection is in agreement to the report of Patra *et al.* (2010) and Chapman (2014) who stated that in case of caecal coccidiosis, enlarged and distended caeca filled with

blood and petechial haemorrhages were observed in *E. tenella* infected chickens.

Gross post mortem lesions caused by *E. acervulina* were ballooned and hyperemic duodenum, creamy contents in the lumen, bloody exudate in the lumen, pin point necrotic foci, whitish transverse streak (ladder like lesion) in the mucosa and serosa, thickened and bright red mucosal wall and lumen filled with blood. This finding is supported by Chapman (2014) and Shohreh *et al.* (2014) who stated that *E. acervulina* affected duodenum characterized by white transversely oriented mucosal streaks, petechiation and thickening of the mucosa and watery content.

The most common post mortem lesions in mixed infection were manifested by enlarged and distended caeca filled with blood and petechial haemorrhages in the whole length of intestine and caecum of challenged group. Similar observation is record by Jenkins *et al.* (2009) and Chapman (2014) who reported that *E. maxima*, *E. tenella* and *E. necatrix* infected birds which have been characterized by petechiae on the jejunum serosa, mucosal hyperaemia, orange coloured intestinal content, intestinal wall thickening and distention.

The categories of lesion score in infected groups were depend on the infected *Eimeria* spp. *E. tenella* infected groups revealed the highest lesion score (lesion score +3, n= 4 and lesion score +4, n=3) followed by *E. acervulina* (lesion score +3, n=2 and lesion score +4, n=2) and mixed *Eimeria* spp. (lesion score +3, n=3 and lesion score +2, n=4). Similar findings are report by Conway and Mckenzie (2007) who stated that *E. tenella* infection showed very severe lesions, those induced by *E. acervulina* were moderate, while *E. maxima* lesions were discrete. Also this results is in accordance with Duffy *et al.* (2005) and Hussain (2010). The present observation disagreement with Zulpo *et al.* (2007) who described as equal challenges of 2×10^4 sporulated oocysts (*E. tenella*, *E. acervulina* and *E. maxima* were used) in experimental groups, this concentration was not sufficient to promote lesions above 2.

In the current study, histopathological lesions were more extensive lesion (*E. tenella*), extensive (*E. acervulina*) and medium (mixed *Eimeria* spp) on 7 DPI. Similar findings are reports by Karim and Trees (2003) identified *Eimeria* species based on a lesion examinations of naturally infected birds, and similar lesions seen in experimentally infected chickens. The difference histological lesions observed could be due to destruction of the epithelial lining of the infected intestine by different *Eimeria* spp. which results in reduced ability for the digestion and absorption of nutrient by chickens.

E. tenella infected group revealed loss of epithelial tissue, congestion of blood vessels which indicated disruption followed by leakage of blood, necrosis of submucosa, loss of villi, disruption of caecal mucosa, cluster of oocysts, schizonts and marked haemorrhage, necrosis of caecal mucosa considerable numbers of oocyst in lamina propria of caecum, presence of different developmental stages of parasite, villous atrophy, severe inflammation and mononuclear inflammatory cell infiltrate, sever haemorrhage and

desquamation of epithelium. Similar findings were reported by Soomro *et al.* (2001), McDougald and Fitz-Coy (2008) and Meskerem *et al.* (2013). Histopathological findings showed more extensive lesions with inflammatory cells in *E. tenella* infection than *E. maxima*. This is in agreement with the work of You (2014) who identified histological lesions in *E. tenella*, *E. maxima* and *E. necatrix* naturally infected chickens. The histopathological lesion occurrence of affected caeca in the present study could be due to the most pathogenic stage of *E. tenella* as the second generation schizonts, which caused excessive tissue damage, bleeding, disruption of the caecal glands and destruction of the mucosa and muscularis layer.

The histopathological changes in *E. acervulina* infected group revealed, presence of oocysts and schizonts with characteristic inflammatory cells in duodenal part of intestine, focal to sever haemorrhage. Similar occurrence have been reported by Asaduzzaman *et al.* (2011) who stated that *E. acervulina* showed presence of oocyst and schizonts with the characteristic of inflammatory cells in duodenal part of intestine.

Histopathological lesions in mixed *Eimeria* spp. infected group on 7 DPI showed discrete villous atrophy, proliferation of epithelial cells, focal haemorrhagic areas, presence of parasite at the villi, infiltration of mononuclear cells and dilation of mucosal glands associated with parasite in various stages of development in the intestine (duodenum, jejunum and cecum) mild villous atrophy, epithelial cell proliferation, and mild haemorrhage in various stages of parasite development, congestion in the muscularis layer. The result is in agreement with Zulpo (2007) who reported that mild histopathological lesions observed in chickens induced 2×10^4 sporulated oocysts of *E. tenella*, *E. acervulina* and *E. maxima* at 7 DPI.

References

- Asaduzzaman, M.N., Miah, M. S., Siddika, A.T., Popy, N. and Hossain, M. M. (2011): Experimental production of necrotic enteritis in broiler chickens. *Bangle Journal of veterinary medicine*, 9(1):33-41.
- Bowman, D. (2003): Parasitology for veterinarians. 8th ed. U.S.A. Saunders. Broiler chicks *Gallus domesticus* in Riyadh city, Saudi Arabia. *Journal of King Saud*, 9(1):12-19.

- Chapman, H.D. (2014): Milestones in avian coccidiosis research: A review. *Poultry Science*, **93**:501-511.
- Conway, D.P. and McKenzie, M.E. (2007): Poultry coccidiosis, diagnostic and testing procedures. 3rd ed. Ames, Iowa. Blackwell publishing, IA, USA. Pp.37-40.
- Duffy, C.F., Mathis, G.F. and Power, R.F. (2005): Effects of natustat supplementation on performance, feed efficiency and intestinal lesion scores in broiler chickens challenged with *E.acervulina*, *E. maxima* and *E.tenella*. *Veterinary Parasitology*, **130**:185-190.
- Gari, G., Tilahun, G. and Dorchie, P. (2008): Study on Poultry coccidiosis in Tiyo District, Arsi Zone, Ethiopia. *International Journal of Poultry Science*, **7**:251-256.
- Holdsworth, P.A., Conway, D.P., McKenzie, M.E., Dayton, A.D., Chapman, H.D., Mathis, G.F., Skinner, J.T., Mundt, H.C. and Williams, R.B.(2004): World association for advancement of veterinary parasitology guidelines for evaluating the efficacy of anticoccidial drugs in chickens and turkeys. *Veterinary Parasitology*, **121**:189-212.
- Lobago, F., Worku, N. and Wossene, A. (2005): Study on coccidiosis in Kombolcha Poultry Farm, Ethiopia. *Tropicassl Animal Health and Production*, **37**:245-251.
- McDougald, L.R. (2003): Coccidiosis. In: Saif, M. (ed). Diseases of poultry. Iowa State Press, Blackwell Publishing Company, USA, 11th ed. Pp.974-991.
- McDougald, L.R. and Fitz-Coy, S.H. (2008): Protozoal infection, In: Saif, Y.M. (ed.). Disease of poultry. 12th ed. Blackwell Publishing. Ames, IA, USA. Pp.1068-1080.
- Meskerem, A., Chaiwat, B., Nirat, G. and Montakan, V.(2013): Haematological, biochemical and histopathological changes caused by coccidiosis in chickens. *Kasetsart Journal (Nat. Sci.)*, **47**:238-246
- Morris, G.M. and Gasser, R.B. (2006): Biotechnological advances in the diagnosis of avian coccidiosis and the analysis of genetic variation in *Eimeria*. *Advance biotechnology*, **24**:590-603.
- Nematollahi, A., Moghaddam, G. and Pourabad, R. (2009): Prevalence of *Eimeria* species among broiler chicks in Tabriz (Northwest of Iran). *Munis Entomology & Zoology Journal*, **4**:53-58.
- NMA (2011): Annual climatically bulletin for the year 2011. National Metrological Agency of Ethiopia.
- Patra, G., Ayoub, M., Chanu, K., Jonathan, L., Joy, L., Pravo, M., Das, G. and Dvel, K. (2010): Diagnosis of *E. tenella* infection in broiler chicken. *International Journal of Poultry Science*, **9**(8):813-818.
- Shohreh, A., Jabrani, J., Googoosh, R., Omidyar, W. and Rosie, M. (2014): Predominance of *Eimeria* species in searching local chickens of Shiraz, Iran. *International Journal of Biosecurity and Bioterrorism*, **1**(3):059-061.
- Soomro, N.M., Rind, R.A., Arijo, A. G. and Soomro, S.A. (2001): Clinical, Gross and Histopathological Studies of coccidia infection in Chicken. *International journal of Agriculture and Biology*, **3**(4):426-427.
- Talukder, S. (2007): Histopathology techniques:Tissueprocessingand staining. www.talukderb.com.
- You, M.J. (2014): The comparative analysis of infection pattern and oocyst output in young broiler chicken, *E.tenella*, *E.maxima* and *E. acervulina*. *Veterinary World*, **7**(7):542-547.
- Zander, D.V. (1999): Principles of disease prevention, diagnosis and Control. In: Hofstad, M.S., Calnek, B. W., Helmboldt, C. F., Reid, W. M. and Yoder, J.H. (ed.). Diseases of poultry, 7th ed. USA, Iowa State University Press/Ames, Iowa, Pp.3-48.
- Zulpo, D., Dauton, L., Jaidson, P., Leandro, M., Elaine, L., Marcos, R.O., Ivens, G.G., Selwyn, A.H., Jose da Silva, G.J. and Joao, L.G. (2007): Pathogenicity and histopathological observations of commercial broiler chicks experimentally infected with isolates of *E.tenella*, *E.acervulina* and *E. maxima*. *Londrina, Semina: ciencias Agrarias*, **28**(1):97-104.

Access this Article in Online

	Website: www.ijarbs.com
	Subject: Veterinary Medicine
DOI: 10.22192/ijarbs.2019.06.01.010	

How to cite this article:

Samrawit Melkamu, Mersha Chanie and Mulat Asrat. (2019). Gross and Histopathological Observations of Commercial Broiler Chicks Experimentally Infected with Pure *Eimeria tenella*, *E. acervulina* and Mixed isolated *Eimeria* spp. *Int. J. Adv. Res. Biol. Sci.* 6(1): 84-94.
DOI: <http://dx.doi.org/10.22192/ijarbs.2019.06.01.010>