



Therapeutic Management of contagious Ecthyma (Orf) in sheep

Bharath Kumar Reddy C^{1*}, Amaravathi M² and Jyosthna S³

Veterinary Dispensary, Kadapa, Andhra Pradesh, India.

¹Ph.D Scholar, Department of Veterinary Medicine, C.V.Sc, Tirupati

²Ph.D Scholar, Department of Veterinary Pathology, C.V.Sc, Tirupati.

³Veterinary Assistant Surgeon, Kadapa district.

*Corresponding author: bharath.vet4@gmail.com

Abstract

Contagious ecthyma was diagnosed in two sheep based on history and clinical signs viz. dullness, depression and anorexia. Clinical examination revealed extensive lesions around mouth, lips, gums and tongue. Fissure formation over the lower lip was also observed in one animal. Both the cases were treated with Enrofloxacin at the rate of 3 mg/ Kg body wt. and Meloxicam at the rate of 0.5 mg/ Kg body wt. intramuscularly for 5 days. The lesions were also washed with potassium permanganate solution and then dressed with boroglycerine ointment topically.

Keywords: Contagious ecthyma, Sheep, Enrofloxacin, Boroglycerine ointment.

Introduction

Orf also known as scabby mouth, sore mouth, contagious ecthyma and contagious pustular dermatitis is a viral disease caused by *Parapoxvirus* (Orf virus) that affects sheep, goats, camels and other species including humans (Lovatt et al., 2012). It affects the skin around mouth and is prevalent worldwide where sheep and goats are raised (Nandi et al., 2011). The disease is common in young animals in 3 – 6 months of age, but mature animals may also be affected (Ndikuwera et al., 1992).

Contagious ecthyma outbreaks occur more frequently during the period of extreme temperature. The disease initially presents itself as erythema which later develops into papules. These papules progress to develop into scabs (Housawi, 1993) or pustules before encrusting. They can spread around the outside and

inside of the mouth, lips and tongue. The infection spreads by the direct and indirect contact from infected animals or by contact with infected materials. The present study deals with therapeutic management of contagious ecthyma in 2 sheep.

Clinical history and Observations

Two sheep were presented to the Veterinary Dispensary, Kadapa district with the history of dullness, depression and anorexia since 3 days. Clinical examination revealed elevated temperatures which reached 104.5°F. The lesions were severe, but were confined to the skin around the mouth (Fig. 1), gums, lips and on the tongue. The lesions had an offensive odour. In one case fissures formation was observed on the lower lip (Fig. 2).

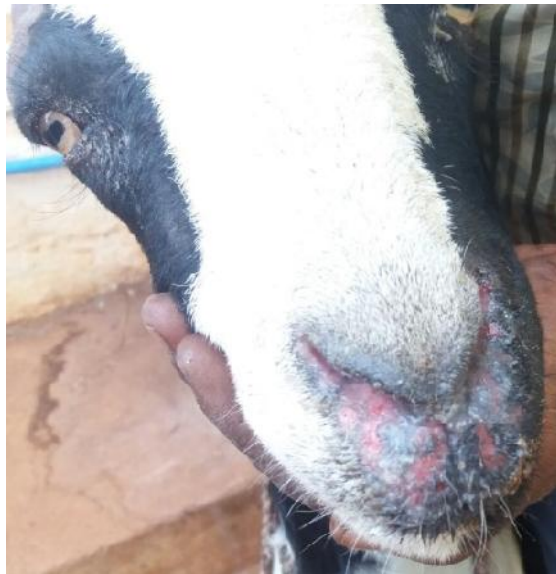


Fig. 1 Photograph of a sheep showing severe proliferative orf lesions around the mouth and nostrils.

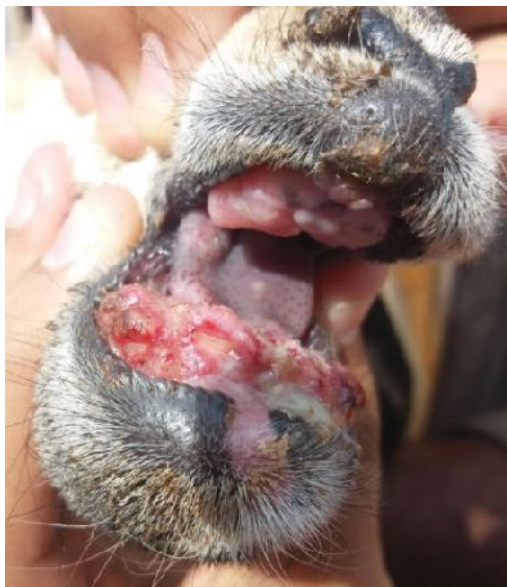

Fig. 2 Photograph of a sheep showing severe proliferative orf lesions and fissure formation on lower lip.

Treatment and Discussion

Therapy was initiated with Enrofloxacin at the rate of 3 mg/ Kg body wt. and Meloxicam at the rate of 0.5 mg/ Kg body wt. intramuscularly for 5 days and boroglycerine ointment topically for 7 days. Improvement of clinical signs was noticed after 5 days, except for the lesion on lips. Enrofloxacin belongs to fluoroquinolones group and is a potent DNA gyrase inhibitor causing bactericidal action (Prescott and Baggot, 1994). It is active against most of gram positive and gram negative bacteria. It might be due to high bioavailability and better tissue

penetration of fluoroquinolones (Anadon et al., 1995). Meloxicam was found to be effective in reducing inflammatory change and relieve the animals from pain and pyrexia.

Several sheep and goats severely infected with contagious ecthyma have been found dead or moribund (Toweill, 2004). It is evident that prehension and mastication are altered due to severe involvement of lips, buccal mucosa and tongue as also observed in the present study. In animals with mild infestation mortality due to contagious ecthyma is probably negligible.

Conclusion

Due to contagious nature of the disease, it is easily transmitted to other animals within herd and also to animals of other herd when they come in contact with infected animals while grazing.

References

1. Anadon, A., Martinez, M.R.M.L., Diaz, J., Bringas, P., Martinez, M. A. and Fernandez, R. 1995. Pharmacokinetics and residues of enrofloxacin in chickens. Amer. J. Vet. Resear., 56: 501 – 506.
2. Housawi, F.M. T., Abu Elzein, E.M.E., Gameel, A.A and Al – Afaleq, A. I. 1993. A close comparative study on the response of sheep and goats to experimental of infection. J. Vet.Med., 40: 272 – 282.
3. Lovatt, F.M., Barker, W.J., Brown, D. and Spooner, R.K. 2012. Case-control study of orf in preweaned lambs and an assessment of the financial impact of the disease. See comment in PubMed Commons below Vet Rec., 170: 673.
4. Nandi, S., Ujjwal, K. D. and Chowdhury, S. 2011. Current status of contagious ecthyma or orf disease in goat and sheep – A global perspective. Small Ruminant Res., 131: 584 – 585.
5. Ndikuwera, J., Odiawo, G. O., Usenik, E. A., Kock, N. D., Ogaa, J. S. and Kuiper, R. 1992. Chronic contagious ecthyma and caseous lymphadenitis in two Boer goats. Vet. Rec. 131: 584 – 585.
6. Prescott, J. F. and Baggot, J. D. 1994. Antimicrobial therapy in veterinary medicine, 2nd Edn. Academic Press, New York.
7. Toweill, D. E., Gordon, S., Jenkins, E., Kreeger, T. and Mcwhirter, D. 2004. A working hypothesis for management of mountain goats proceedings of the 14th biennial symposium, May 15 – 22.

| Access this Article in Online | |
|--|--|
|  | Website: www.ijarbs.com |
| | Subject: Veterinary Medicine |
| Quick Response Code | |

How to cite this article:

Bharath Kumar Reddy C, Amaravathi M and Jyosthna S. (2016). Therapeutic Management of contagious Ecthyma (Orf) in sheep. Int. J. Adv. Res. Biol. Sci. 3(4): 51-53.