



## **Treatment of intertrochanteric fractures of the femur with external fixation**

**Dr Anwar Thamer Adday, MB CH B, F,I,C,M S (Orth),**

Orthopedic specialist,  
Baquba Teaching Hospital, Dyala, Iraq

### **Abstract**

The intertrochanteric fractures of the femur is a common injuries affecting mostly elderly people, unfortunately most of them suffering from many medical problems rendering them at high risk of being exposed to major surgery and anesthesia, the use of external fixation is associated with good functional outcome with minimum complications.

**Keywords:** intertrochanteric fractures, femur, external fixation.

### **Introduction**

Hip fractures is a major health problem in elderly ,the intertrochanteric type makes two third of them .this type of fractures occur in geriatric patients, the per operative mortality, therefore rather high<sup>3</sup>.

The incidence of intertrochanteric fractures is gender and race dependant and varies from country to other ,in USA ,the annual rate of intertrochanteric fractures in elderly female is about 63 per 100,000 ,in male ,34 per 100,000<sup>3</sup>.

In elderly patients ,this fractures occur with low energy trauma(one of fragility fractures due to osteoporosis),while in younger individuals are usually the result of high energy trauma, This study aimed to present our experience to use AO tubular external fixation in treatment of intertrochanteric fractures ,stable or unstable, with or without subtrochanteric extension and to expand the use of external fixation to treat the younger age group with multiple fractures in addition to their use in elderly ,this is especially of value when we face a limited resources.

### **Patients and Methods**

Between April 2013 and June 2016, 78 external fixation were performed in 78 patients with intertrochanteric fractures, 48 were female and 30 were male with the mean age of 52.5 years(25 to 83).

Table 1 summarizes the age distribution of the patients

Age(years)	number	percent
20-30	4	5%
30-40	6	7%
40-50	5	6%
50-60	12	15%
60-70	28	36%
70 & above	25	32%

The categories of the patients we faced in this study were geriatric group (61 patients with different medical problems ) 10 were with multiple fractures and 7 patients younger than 50 years( two of them were with thyroid diseases and recent thyroid surgery, two patients were with chronic renal diseases and three patients refused internal fixation).

The fractures were classified using AO classification, and we include all types of the intertrochanteric fractures.

All types of A1 and A2-1 considered as stable and the remaining A2 and A3 types considered unstable.<sup>45</sup>

patients were group A and 33 were group B, 8 patients were with subtrochanteric extension (as shown below).

Patients with pathological or open fractures were excluded.

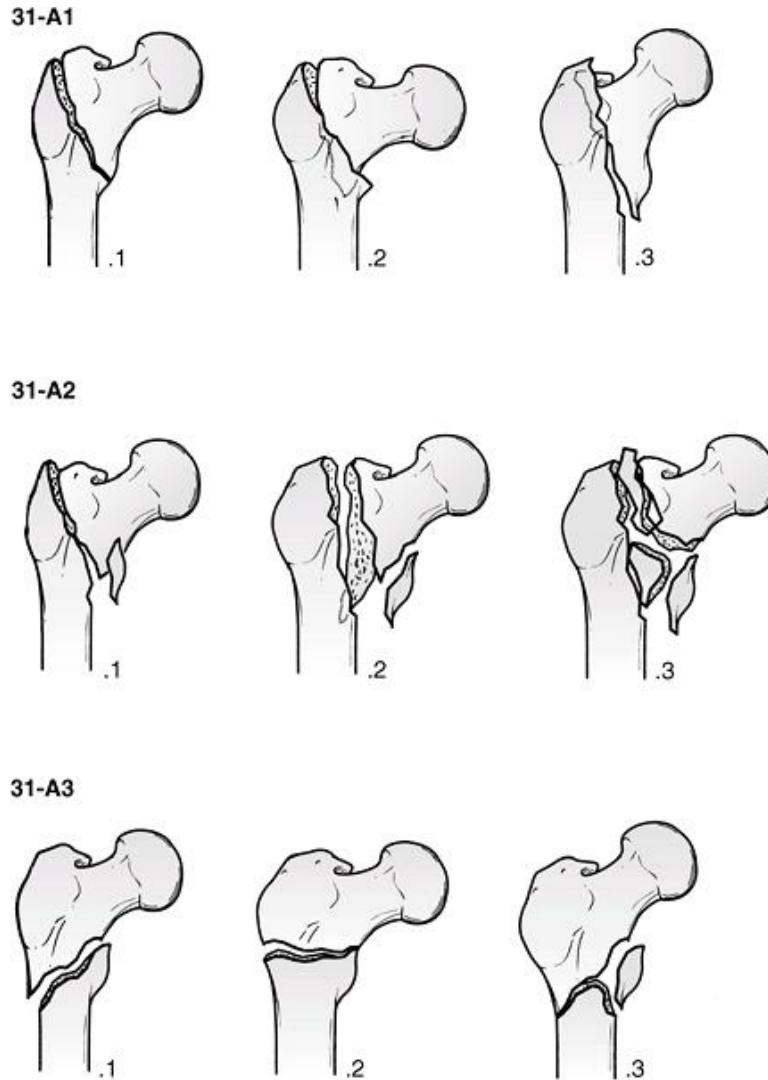


Figure 1 illustrate AO classification of pertrochanteric fractures

### Operative technique

Under anesthesia, usually spinal or short period of general anesthesia or even local anesthesia with narcotic analgesic support, orthopedic table, under c-arm control, gentle reduction to the affected limb started with the limb held in slight internal rotation and 15-20 degrees of abduction<sup>6,10,18</sup>.

After achievement of adequate reduction and length, we apply 2 to 3 schanzs of AO tubular external

fixation, 5-6 mm thickness through a stab incision one inch below greater trochanter across the fracture line to the femoral head, the tip of the screw should lie one cm from the articular surface of femoral head, other two -three schanzs inserted into the femoral shaft below the fracture line.

Tightening of the clamps done after final radiological checking of reduction

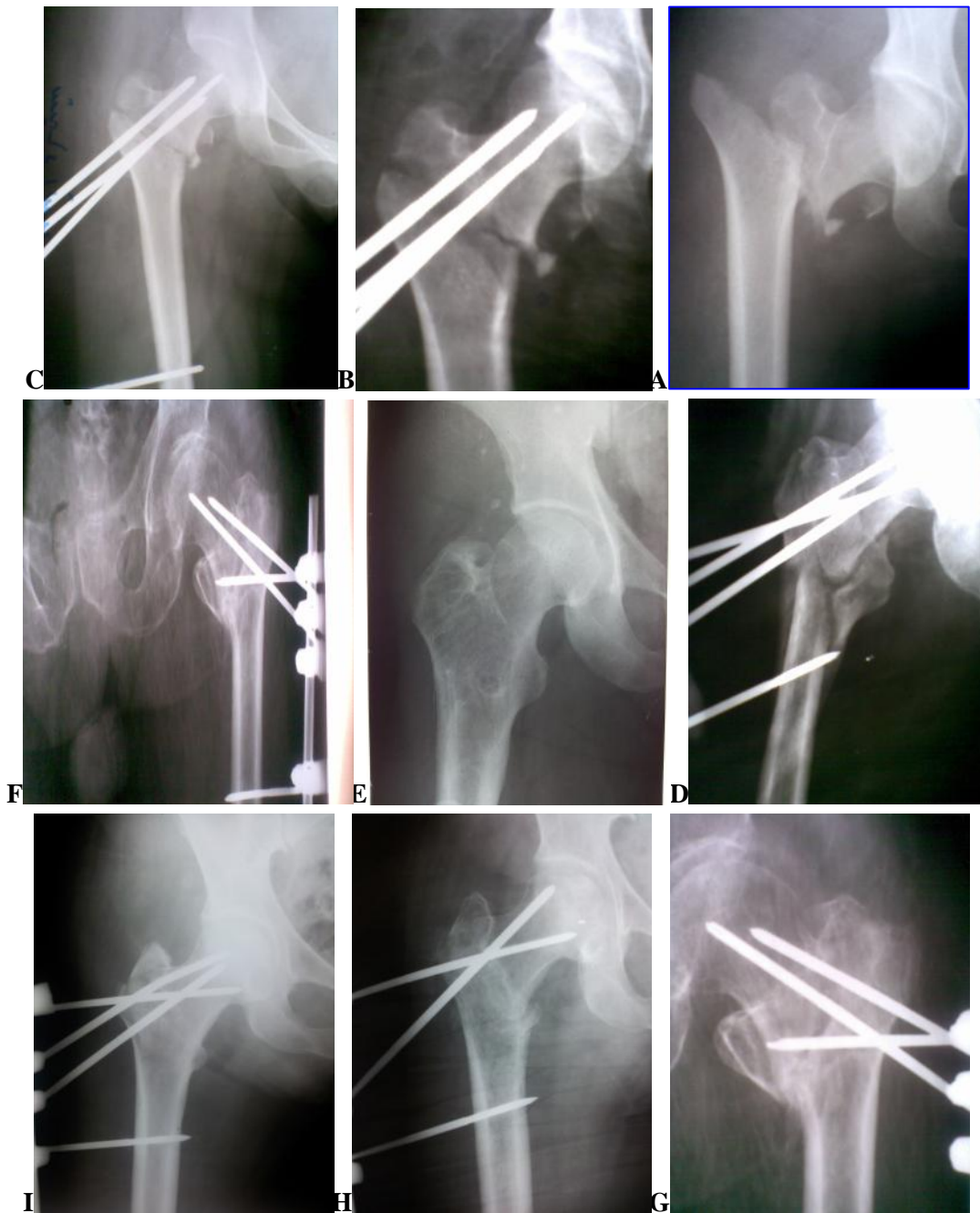

Figure 2 a. Preoperative high velocity fracture with contra lateral distal femur fracture b. immediate postoperative x-ray , unstable intertrochanteric fracture fixed with external fixation.c.4 weeks later, the fracture in stage of union. d. unstable intertrochanteric fracture in 35 years patient ,with high energy trauma, this x-ray show anatomical reduction & fixation e. this x-ray for fracture (d), taken 12 months after removal of external fixator showing excellent healing (F,G,H and I ), geriatric fractures fixed with external fixation taken 8 & 10 weeks shows bone healing in progress.

Daily care of schanzs and surrounding skin using povidon iodine solution. immediate active hip, knee and ankle motion started. The patients were followed for six months to two years postoperatively, they were evaluated clinically and radio logically once weekly for the eight weeks, than twice monthly till removal of the fixators.

The follow up time was from 6 month to 2 years, the age of patient varies from 25 years to 83 years , the youngest patients suffered from multiple injuries, while the elderly patients , most of them were with chronic medical disorders, table 2 shows different types of concomitant medical diseases.

## Results

Over a period of 3 years, 78 intertrochanteric fractures were treated by external fixations.

### Concomitant disease

Coronary diseases	22
hypertension	28
Heart failure	9
Renal diseases	4
Thyroid diseases	2
anemia	12
Pulmonary diseases	5
malignancy	1

All patients achieve union,

Average union time for stable intertrochanteric fractures stabilized with AO tubular external fixation were 14 week± 2 , and for those with unstable type of fractures(group B) were 18 ± 2. The mean operation time for fixation was 20 ± 5 minutes.

Mobilization and physiotherapy started on the second postoperative day and assisted weight bearing as the patient tolerated. The hospital stay of the patient ranged from 2 to 5 days.

No mortality occurred in the first 30 days postoperatively, Two patients died within 6 months , this was related to their medical problems.

Other local complications were minimum, these include

1.Pin tract infection occur in 15 patients,10 of them were superficial and treated by daily dressing with providing iodine and proper antibiotics,5 patient developed deep pin tract infections requiring removal

of the schans , fortunately after that the infection subsided.

2. Pin lessening occurred in 7 patients in the proximal fragments , removal of the pin and insertion of another under local anesthesia solve the problem.

3. Limb length were achieved in all but 6 patients with 2 cm shortening.

4.Varus deformity with neck shaft angle of 115 degrees occurred in 3 patients.

The varus and shortening was explained by Dhal<sup>6</sup> etal to be due to either fixation in varus or to collapse of the neck shaft angle on early weight bearing of the patients.

5 Knee stiffness occurred in almost all the case with a range of motion range from (20 to 50 degrees) immediate postoperatively , this was temporary ,and increased with time to reach normal range after removal of the fixations.

Table 3 shows the possible complications.

complication	number	percent
Pin tract infection	15	19%
Pin loosening	7	9%
Limb shortening	6	7%
Varus malunion	3	4%

## Discussion

With the development of compression hip screw and gamma nail, internal fixation of intertrochanteric fractures remain the gold standard treatment<sup>4,10</sup>, but the morbidity and mortality rate are high in elderly patients with significant co-morbid factors and in those with multiple fracture.

Non operative treatment involves prolonged immobilization and hospitalization with many concomitant problems of high mortality<sup>4</sup>.

The main objective for this high risk group is to operate with least blood loss in the shortest time and low risk anaesthesia rather than obtaining a very perfect reduction.

Achievement of union is not a problem, since intertrochanteric fractures are through vascular cancellous bone.

Previous reports on external fixations showed short operating and hospitalization time, high fracture union rate and minimum blood loss<sup>6,7,17,18</sup>.

The present study was conducted using the minimally invasive technique of external fixation for the management of all intertrochanteric fractures (AO type 31 A1, A2 and A3).

The mean operation time for fixator application in the present study was 20±5 minutes, this was similar to time recorded by Shalaby<sup>10</sup> and kourtzis<sup>11</sup> et al. and less than those recorded by tomak<sup>17</sup> et al and others<sup>7,13</sup>.

Familiarity with application techniques and few instrumentations needed for AO external fixations played a significant role in reducing the mean operation time.

The mean hospitalization time in the present study is 3 days, range from 2 to 5 days, this similar to shabby<sup>10</sup> et al group (3±0.9 days) while it was less than those recorded by kourtzis<sup>11</sup> et al (7.2 days).

The mean time to achieve union in the present study is 14 weeks±2 for unstable fractures (group A), and 18 weeks±2 for (group B) unstable fractures, this is similar to other studies<sup>6,11</sup>, but it is longer than shalaby<sup>10</sup> et al study (10±1.2 weeks) and Gudemez<sup>8</sup> et al study.

The mean age of the patients in the present study is lower than those of shalaby and kourtzis, this is due to inclusion of younger patients with multiple fractures.

As with other studies<sup>(4,7,10,13,17)</sup> the most common complications in the present study was pin tract infections, whether superficial or deep respond well to treatment.

The incidence of loss of reduction and varus malunion more than 10 degrees with shortening of > 2cm is comparable to most previous studies<sup>3,6,12,18</sup>

## Conclusion

The external fixation of intertrochanteric fractures offer the advantages of preserving the fracture hematoma, minimum surgical trauma, this technique is simple, safe and quick. It allows the patients mobilize earlier with shorter hospital stay, this technique can be applied at different age group, but it is especially of value in elderly and in those with multiple fractures or injuries and when we face a limited resources.

## Footnote

This work has been done at baquba teaching hospital & other diyala governorate hospitals.

## References

1. Alcivar E .a new method of external fixation for proximal fractures of the femur .injury 2001: 32 supply4:SD 107-114.
2. Buckley J R. Caiach SM. External fixation in comminuted upper femoral fractures. Injury 1993;24, 476-478.
3. Bucholz, Robert w, Heckman ,rockwood & Green ,fractures in adult, 6<sup>th</sup> edition,2006
4. Christodoulou NA, Sdrenias CV ,external fixation of select intertrochanteric fractures with single hip screw, clinical orthopedic.2000:381,204-211
5. Dergan, sisangwan , external fixation in the management of trochanteric in high risk geriatric patients. Indian journal of medical science 2002, vol.56,issue8,page:385-
6. Dhal A/Singh SJ ,Biological fixation of subtrochanteric fractures by external fixation. injury 1996,27,723- fixation, injury 1996,27,723-731
7. Dhal A, Varghese M, Bhasin VB. external fixation of intertrochanteric fractures of the femur ,J.B joint surgery 1991,73-B,955-958

8. Eksioğlu F, Gudemez ZE, Sepici B. Treatment of intertrochanteric fractures by external fixation. Bull hospital Jt Dis. 2000;56(3):131-5
9. Esser MP, Kassab JY, Jones DHA, trochanteric fractures of the femur, J Bone joint surgery, 1985;68B,557-560
10. George W. Boghadady, Mohammed shalaby, safety & reliability of external fixation for basicervical intertrochanteric fractures in high risk patients, Springer strategies trauma & limb reconstruction.
11. Kourtzis N, pAfilias D, Kasimatis G. management of pertrochanteric fracture in the elderly patients with an external fixation. Injury 2001;32 suppl 1S115-128
12. Kamble KT, Murthy BS, palv et al (1996), external fixation in unstable intertrochanteric fractures. Inj. 27, 139-142
13. Kostas kazakos, Dimitios verehas, external fixation of intertrochanic fractures in elderly high risk patients acta orthop. belg. 2007;73,44-48
14. Moroni A, Faldini C, Peg reffi et al, osteoporotic pertrochanteric fractures can be successfully treated with external fixation, J B joint surg 2005;87-A suppl 2:42-51
15. Perves H, Parker MJ, Pryor Ga et al, 2002, classification of trochanteric fractures of proximal femur. injury 33:713-715
16. Petsattodisg, Christodoulou AG, Venetsanakisg, external fixation for stable & unstable intertrochanteric in patients older than 75 years of age. J orthop. trauma. 2011 Apr; 25(4):218-23
17. Tomak Y, KACAGLU m, Piskin A et al (2005), treatment of intertrochanteric fractures in geriatric patients with a modified external fixation. INJURY 36:635-643
18. Vossinakis IC, Badras LS, the management of pertrochanteric fractures in high risk patient with an external fixation, int. orthop., 2001; 25, 219-222

<b>Access this Article in Online</b>	
	Website: <a href="http://www.ijarbs.com">www.ijarbs.com</a>
<b>Quick Response Code</b>	Subject: Dental Sciences
DOI: <a href="https://doi.org/10.22192/ijarbs.2017.04.12.028">10.22192/ijarbs.2017.04.12.028</a>	

**How to cite this article:**

Anwar Thamer Adday. (2017). Treatment of intertrochanteric fractures of the femur with external fixation. Int. J. Adv. Res. Biol. Sci. 4(12): 262-267.

DOI: <http://dx.doi.org/10.22192/ijarbs.2017.04.12.028>