



Anatomical study on the testicular artery of bull (*Bos Taurus*)

Khalifa, E.F* and Nawal, A. Noor

Anatomy and Embryology Department, Faculty of Veterinary Medicine, Cairo University.

*Corresponding Author

Abstract

The aim of this study was to investigate the topography of the testicular artery in the spermatic cord and testis. 20 samples were collected from slaughter house for this study. The testicular artery was cannulated and flushed with warm normal saline solution (0.9%) then injected with different masses (Urographine®, Epoxy and Latex). The testicular vein injected with blue colored neoprine (60%) latex in order to study the relation between the testicular artery and pampiniform plexus. The testicular artery in the spermatic cord named the funicular part of the testicular artery that gave off two epididymal branches to the head and tail of epididymis before it became marginal artery. The degree of complexity was affected by the number of coils formed by the vessel. The testicular artery appeared more complex in bull. The pampiniform plexus originated from marginal plexus which gathered blood from the intraparenchymal network of the veins.

Keywords: Testicular artery - Pampiniform plexus – Testis- Bull.

Introduction

The angioarchitecture of the testis is still attracts many authors to deal with its pattern among the animal kingdom. The vascular blood supply of the testis in different species of animals has been dealt by a large number of authors. In this regard, *Harrison (1949)*, *Harrison and Weiner (1949)* and *Wilkens and Mtiunster (1976)* gave an adequate description for the blood vessels of male gonads in domestic animals. The majority of studies have been focused on the courses and distributions of the testicular vessels by *El-Gaafry and Aly (1977)* and *Osman et al., (1979)* in camel, *El-Gaafry et al., (1980)* in buffalo, *Wilkens and Mtiunster (1976)* in domestic animals and *Abu-Zaid and Gad (1999)* in buck. Others which are scanty have been dealt with the angioarchetecture of the testicular vessels by *Joffre and Kormano (1975)* in fox. *Dhingra (1979)* in buffalo and goat and *Polguy et al., (2011)* in bovine. The degree of convolutions and the dimensional data of the testicular vessels would appear

very significant in interpretation the events that controlling the thermoregulatory mechanism in bull. Several functions have been assigned to this intimate association between the testicular artery and the pampiniform plexus, especially for the temperature regulation mechanism of the testicular blood (*Waites and Moule 1960*) in ram. However, knowledge about the thermoregulatory mechanism of the testes still needs more clarification. The aim of the current study is to give detailed information and accurate description on the architectural pattern of the testicular blood vessels in bull which similar to that of man.

Materials and Methods

The present study was conducted on twenty healthy gonads of adult bull. The origin and course of the abdominal part of the testicular vessels were traced in slaughter house of the great Cairo. The collected

specimens were kept in normal saline solution at ambient air for 2-3 hours, and then the specimens were divided into two groups: The first one representing 75% of the total numbers of samples for studying the testicular arteries while the second group 25% was prepared to study the testicular veins and plexuses. The testicular artery was cannulated then thoroughly washed by worm normal saline solution NaCl 0.9% containing a small addition of heparin (heparin calcium 5000 I.U.) to remove the remaining blood and clots in the vessels .

I - Radiopaque Imagine “Angiography”.

Five of the specimens were injected by Urographine® then radiographed using 52 KVP, 48 MA, 0.5 second and FFD 70cm.

II - Gum Milk Latex Injection Technique. Rotring® ink.

Five of the specimens were injected by the gum milk latex colored with red Rotring® ink. The specimens were left in a mixture of 10% formalin, 2% phenol and 1% glycerin for three days before dissection. The specimens were bluntly dissected for exposing the arterial loops and tracing the various convolutions.

III - Plastoid Corrosion.

Five of the specimens were injected by Epoxy (E 151 N20) to prepare the vascular casts. The specimens were left in room temperature for polymerization and hardening then the specimens were corroded in strong acid solution (concentrated HCl) for 24 hours, washed in running tap water and then left to dry.

IV - For studying the testicular veins five of the specimens were prepared and injected directly through the cavity of one of the larger branches of the pampiniform plexus by gum milk latex colored with blue Rotring® ink. The obtained results were photographed using Sony® digital camera 12.1 mp, 4x. The nomenclature used in this study was adapted to *Nomina Anatomica Veterinaria Fifth edition N.A.V. (2005)*.

Results

The testicular arteries are the main source of blood supply of the testis and epididymis. They are two slender vessels of considerable size; arise from the ventrolateral aspect of the abdominal aorta at a level with the 5th lumbar vertebrae in the bull.

For the topographical description of the testicular artery (**Figs. 1, 2 and 3/1**) and for its long course it is found more convenient to deal with the vessel funicular and marginal parts.

Pars funicularis cum a. testicularis:

The funicular part of the testicular artery (**Figs.1, 2, 3, and 4/2**) is highly coiled forming numerous loops which are irregularly arranged along the whole length of the vascular cone. The windings are profuse, occupying all angles and spaces of the spermatic cord and their number are gradually increased from proximal to distal. They appear loosely packed in the proximal third of the vascular cone then become tightly packed near its base. The convolutions of the testicular artery are progressively diminished or disappeared at the head pole of the testis and the main vessel is straightened. The length of the vascular cone is ranged between 10-14 cm. while its diameter is ranged 3-5 cm.

Along its course the funicular part of the testicular artery gives off: *Rr. Funicularis, A. Caput epididymalis* and *A. Cauda epididymalis*.

Rr. Funiculares cum pars funicularis:

The funicular branches are 2-3 in number. They emanate from the vascular cone at different levels and at variable depths (**Fig. 3/3**). They extend superficially to supply the surrounding fat, spermatic fascia, cremaster muscle and the tunica vaginalis.

Aa. Epididymales:

The epididymis receives a dual blood supply; one for the head, *A. caput epididymalis*, the other for the tail and body known as *A. cauda epididymalis*. These arteries are considerable vessels arise independently from the funicular part of the testicular artery before reaching the testis. In the majority of the examined cases the *A.cauda epididymalis* arises at a superior level than that of the head. However in few cases, both arteries spring at the same level and opposite to each other.

A. caput epididymalis:

The artery of the head of epididymis (**Figs.1, 2, 3 and 4/4**) springs from the cranial aspect of the funicular part of the testicular artery at a level opposite to the base of the vascular cone. It leaves its origin and proceeds ventral and cranial ward to the head region of the epididymis where it divides into 3-4 branches that ramify in the head region of the epididymis.

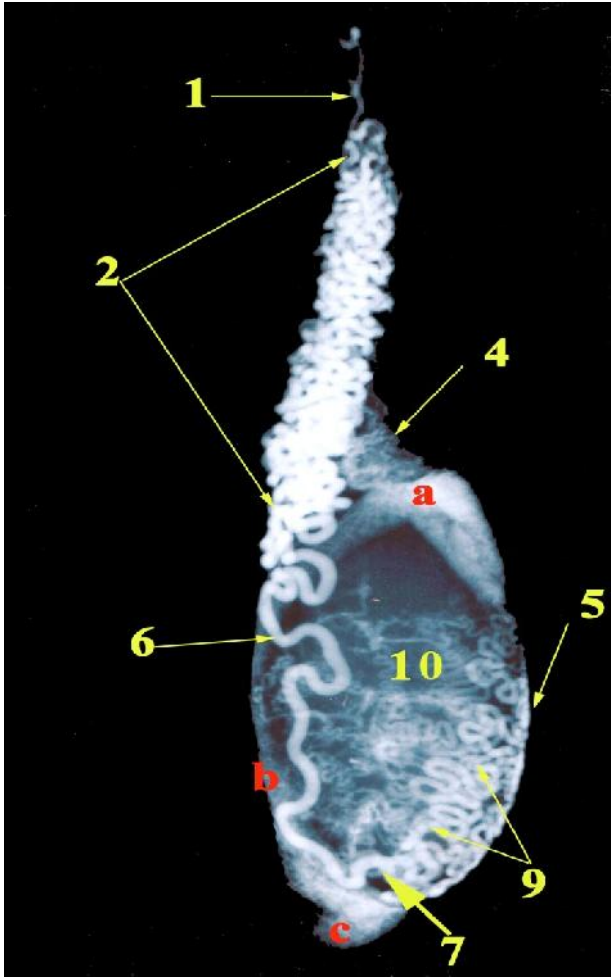


Fig.1: A radiograph of bull right testis showing the distribution of the testicular artery injected with urographin (lateral view)

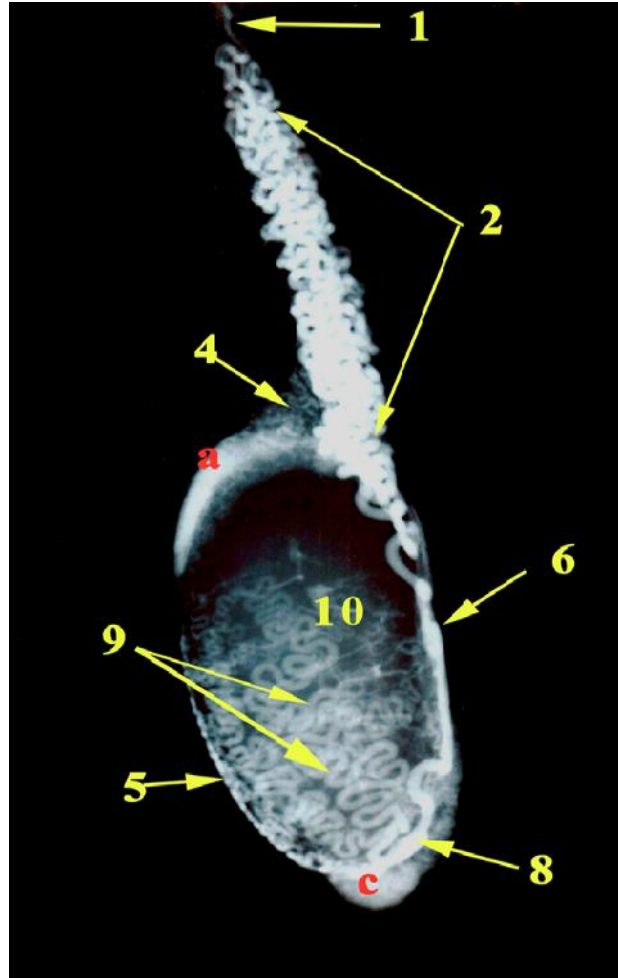
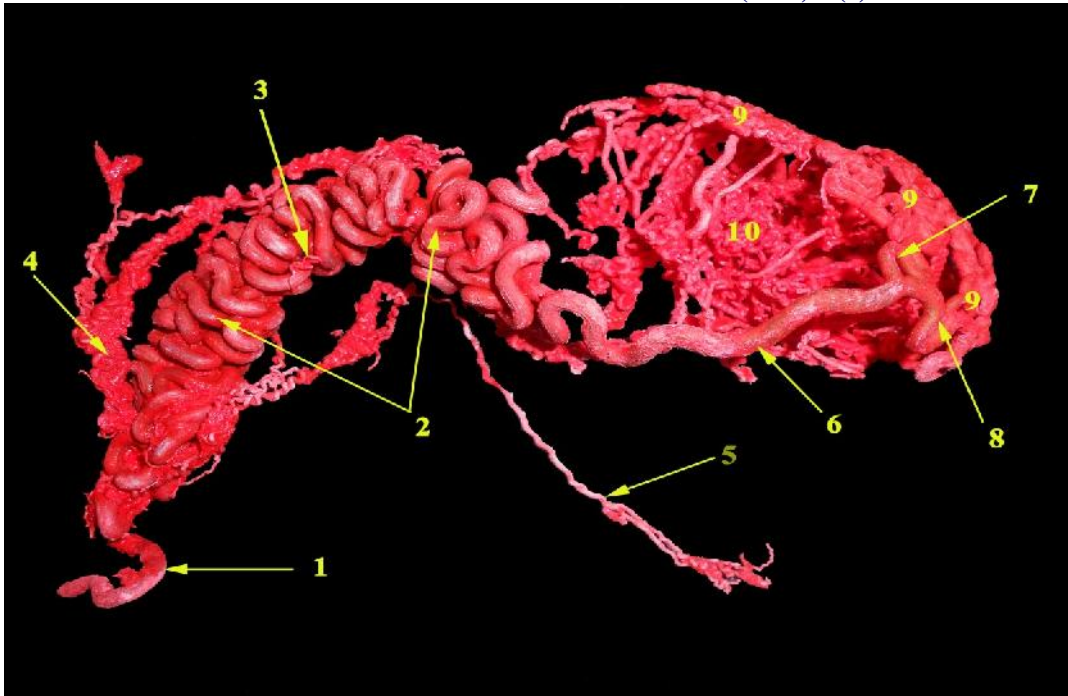


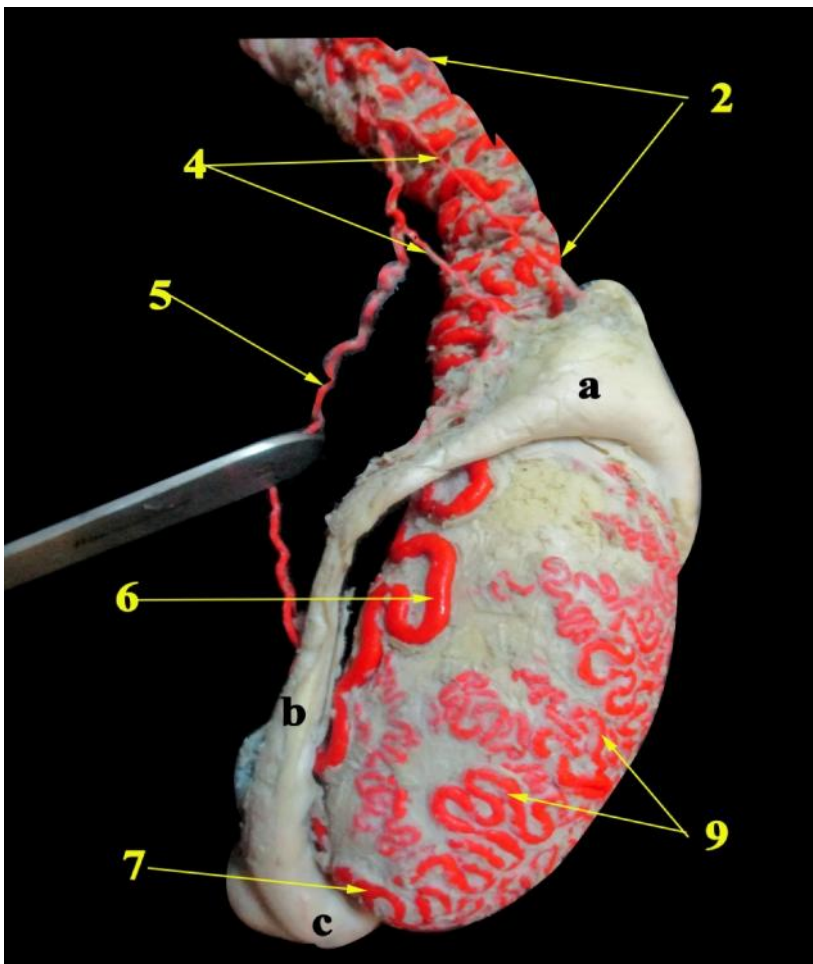
Fig.2: A radiograph of bull right testis showing the distribution of the testicular artery injected with urographin (medial view)

<ol style="list-style-type: none"> 1. A. testicularis 2. Pars funicularis cum a. testicularis 4. A. caput epididymidis 5. A. cauda epididymidis 6. Pars marginalis cum a. testicularis 7. Ramus lateralis of Pars marginalis cum a. testicularis 8. Ramus medialis of Pars marginalis cum a. testicularis 9. Tunica arteriosa testis 10. Rami parenchymalis 	<ol style="list-style-type: none"> A. Caput epididymidis B. Corpus epididymidis C. Cauda epididymidis
--	--



1. A. testicularis
2. Pars funicularis cum a. testicularis
3. Rr. funiculares cum Pars funicularis
4. A. caput epididymidis
5. A. cauda epididymidis
6. Pars marginalis cum a. testicularis
7. Ramus lateralis of Pars marginalis cum a. testicularis
8. Ramus medialis of Pars marginalis cum a. testicularis
9. Tunica arteriosa testis
10. Rami parenchymalis

Fig.3: A photograph of a corrosive cast of bull testis showing the distribution of the testicular artery injected with Epoxy (lateral view)



2. Pars funicularis cum a. testicularis
 4. A. caput epididymidis
 5. A. cauda epididymidis
 6. Pars marginalis cum a. testicularis
 7. Ramus lateralis of Pars marginalis cum a. testicularis
 9. Tunica arteriosa testis
- A. Caput epididymidis
 B. Corpus epididymidis
 C. Cauda epididymidis

Fig.4: A photograph of bull right testis showing the distribution of the testicular artery injected with latex (lateral view)

A. cauda epididymalis:

The artery of the tail of the epididymis (Figs.1, 2, 3 and 4/5) emanates from the caudal aspect of the funicular part of the testicular artery at the middle of the vascular cone. It proceeds distally in a wavy course among the core of the vascular cone and along the lateral border of the epididymis. It pierces the corpus epididymidis and continues in its course to reach the tail region where it ramifies by 2-3 branches.

Pars Marginalis cum a. testicularis:

The marginal part of the testicular artery (Figs.1, 2, 3, 4, 6, 8 and 10/6) is the direct continuation of the funicular part of the testicular artery on a level with the *extrimitas capitata testis* here the artery is superficially located throughout the tunica albuginea, piercing its texture to become deeply seated then

continues distally along the *Margo epididymidis* where it pursues 3-4 windings before its termination at the *extrimitas caudate testis*. The marginal part of the testicular artery forms a sigmoid curve at the level of junction between the proximal ¾ and distal ¼ of the epididymal border of testis then bifurcates into lateral and medial testicular arteries. At the tail extremity of the testis the lateral (Figs.1, 3, 4 and 8/7) and medial (Figs.2, 3 and 8/8) testicular arteries form 2-3 spiral windings around the tail extremity then proceed in a dorsolateral and dorsomedial direction. Both arteries divide into 7-9 smaller branches that extend towards the *Margo epididymidis* in a wavy manner dorsally and cranially. These second branches are closely adherent to each other forming *tunica arteriosa testis* (Figs.1, 2, 3, 4, 5, 6, 7, 8 and 10/9). The density of the *tunica arteriosa testis* is pronounced in the distal third of the testis.

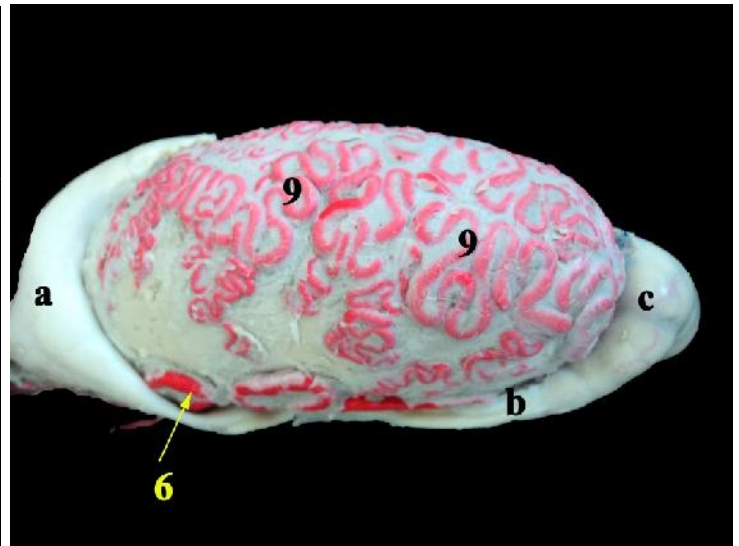
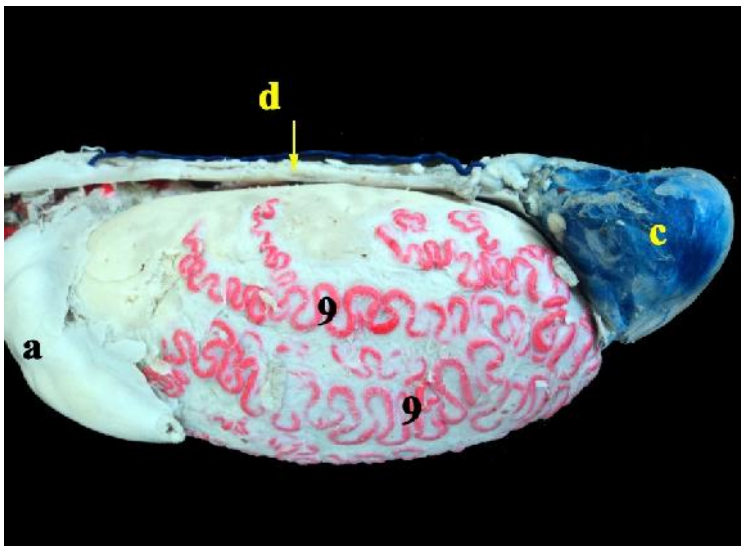


Fig.5: A photograph of bull left testis showing the distribution of the testicular artery injected with latex, medial view

Fig.6: A photograph of bull left testis showing the distribution of the testicular artery injected with latex, Lateral view

- | | |
|--|------------------------|
| 6. Pars marginalis cum a. testicularis | A. Caput epididymidis |
| 9. Tunica arteriosa testis | B. Corpus epididymidis |
| | C. Cauda epididymidis |
| | D. Ductus deference |

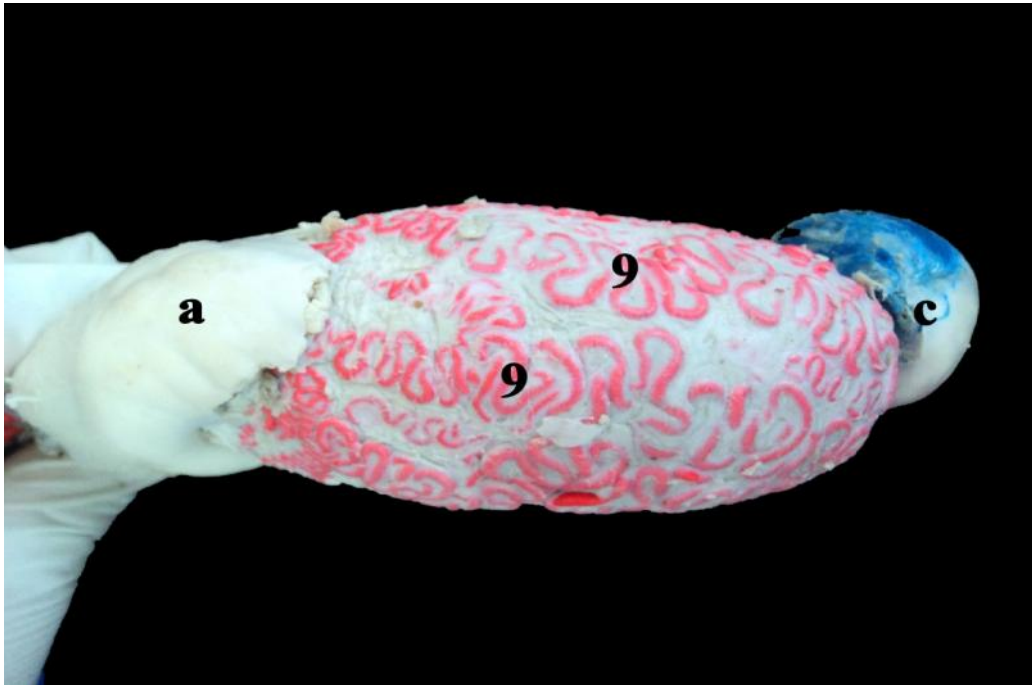
Rami parenchymales:

The arterial parenchymal branches (Figs.1, 2 and 3/10) are 15-20 in number. They are slender delicate

vessels arise from the *tunica arteriosa testis* along the whole surface of the testis. They leave their origin and run through the texture of the testicular parenchyma toward the mediastinum testis.

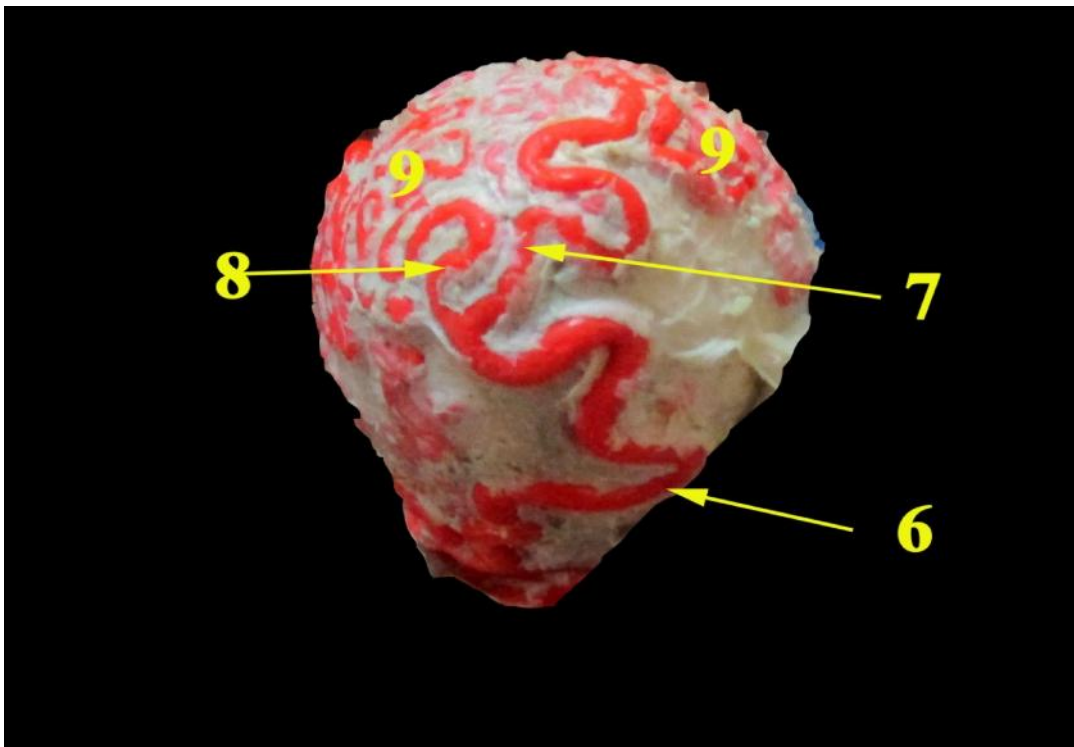
The *pampiniform plexus* (Figs.9 and 10/12) is formed of richly coiled veins which have different dimensions. The architectural orientation of these branches appears profuse, irregular and intensely intermingled with each other, forming a venous layer of high vascular concentration around the testicular

artery. However, some parts of the testicular artery appear devoid of such venous coat and they were visible through small holes of the venous layer (Figs.9 and 10/11).



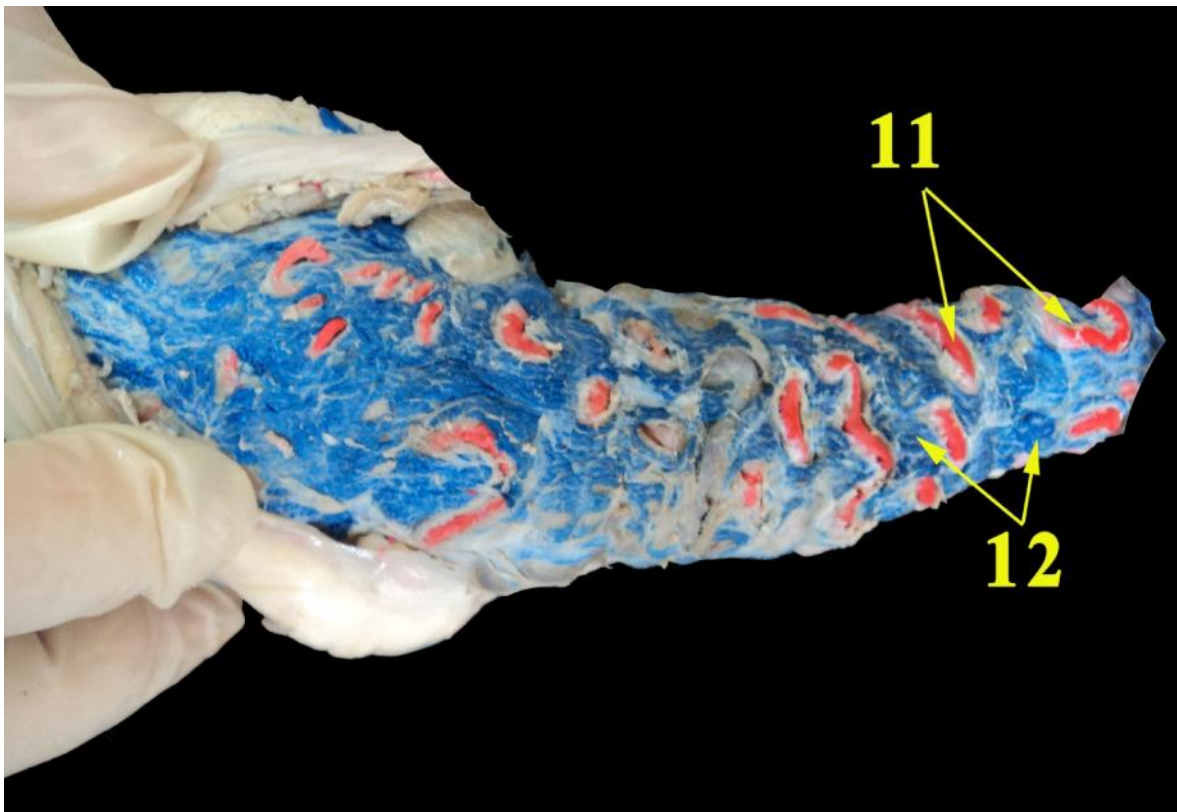
- 9. Tunica arteriosa testis
- A. Caput epididymidis
- C. Cauda epididymidis

Fig.7: A photograph of bull left testis showing the distribution of the testicular artery injected with latex, apical view



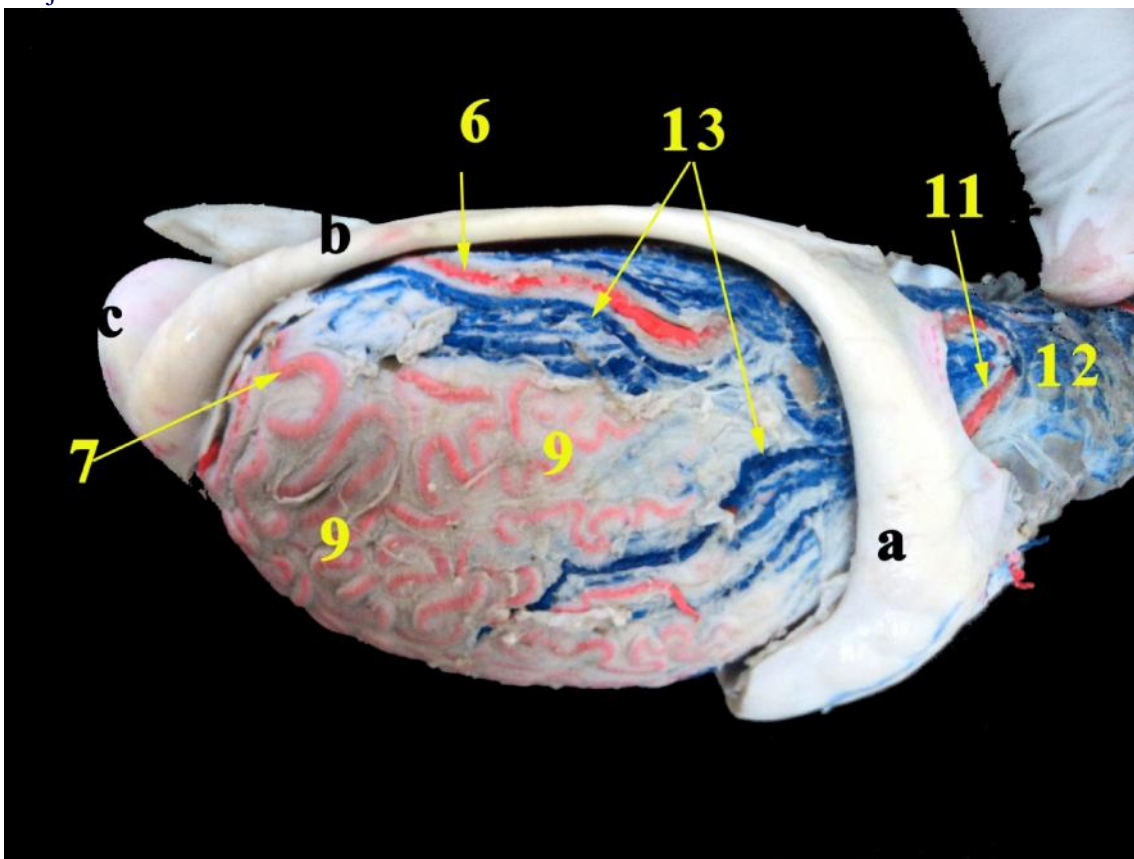
- 6. Pars marginalis cum a. testicularis
- 7. Ramus lateralis of Pars marginalis cum a. testicularis
- 8. Ramus medialis of Pars marginalis cum a. testicularis
- 9. Tunica arteriosa testis

Fig.8: A photograph of bull testis taken at the extrimitas caudata testis showing the mode of division of the pars marginalis injected with latex



11. A. testicularis appear through holes in pampiniform plexus
 12. Pampiniform plexus

Fig.9: A photograph of bull testis showing the relationship between the pampiniform plexus and testicular artery injected with latex



6. Pars marginalis cum a. testicularis
 7. Ramus lateralis of Pars marginalis cum a. testicularis
 9. Tunica arteriosa testis
 11. A. testicularis appear through holes in pampiniform plexus
 12. Pampiniform plexus
 13. Vv. testiculares mediales

A. Caput epididymidis
 B. Corpus epididymidis
 C. Cauda epididymidis

Fig.10: A photograph of bull testis showing the distribution of testicular vein and pampiniform plexus injected with latex

Discussion

The present study revealed that, the testicular artery was present as a single vessel and did not observe any doubled testicular arteries. However, *Elgaafary et al; (1980)* in buffalo, *Amselgruber and Sinowatz (1987)* in bull and *Asala (2001), Raman and Goldstein (2004)* and *Mustafa et al; (2008)* in man, observed an accessory right testicular artery, doubled artery or three arteries.

The present findings have described the coiling pattern of the testicular artery as it is highly coiled forming numerous loops which are irregularly arranged along the whole length of the vascular cone. Similar arrangement for the coiling patterns of the testicular artery were reported by *Dhingra (1979), Abu-Zaid and Gad (1999)* in goat and *Borthakur and Dhingra (1979), Elgaafary et al; (1980)* in buffalo and *Osman et al ;(1979)* in camel and is comparatively less in the donkey (*Fehlings and Pohlmayer; 1978*). While *Khalil (2013)* and *Elayat et al. (2014)* in some farm animal (buffalo, ram, camel, donkey and rabbit) mentioned that there are four patterns of arrangement pattern I in buffalo and ram, pattern II in camel, pattern III in donkey and pattern IV in rabbit. On the other hand, *Harrison and Weiner (1949)* and *Suzuki (1982)* have stated that these loops are missing or not apparent in rodents.

The current work has reported two epididymal arteries in bull, one for the head and the other for the tail, the result which simulating that reported by *Khalil (2013)* and *Elayat et al. (2014)* in some farm animal (buffalo, ram, camel, donkey and rabbit), *El-Gaafary et al; (1980)*, in buffalo *El-Gaafary and Aly, (1977)* in camel, *Abu-Zaid and Gad (1999), Dhingra (1978)* and *Almeida et al; (2008)*, in goat, *Dhingra (1980)* in sheep, *Joffre and Kormano (1975)*, in fox, *Dhingra (1980)*, in donkey, *Chubb and Desjardins (1982)* in rabbit and *Suzuki (1982)* in mouse.

However, *Osman et al., (1979)* in camel recorded a single epididymal artery instead of two in bull. On the other hand, *Fehlings and Pohlmayer (1978)* in donkey and *Rajtová and Danko (2001)* in rabbit have reported three epididymal rami: the former authors named them; *R. epididymalis caudalis; R. epididymalis capitis and R. epididymalis cranialis* while the later authors named them as, cranial, middle and caudal epididymal branches.

Regarding the course and mode of termination of the pars marginalis of the arteria testicularis, the present work has reported that the artery was pursued a spiral course, performing secondary tortuities along its course and was partially concealed by the epididymis. These findings are in agreement with those of *Harrison (1949)* in mammals, *Borthakur and Dhingra (1979)* in buffalo and *Dhingra (1978)* in goat. The terminal division of the testicular artery near the caudal pole of the testis as it gave off two terminal branches named lateral and medial testicular arteries is similar to that of the buffalo (*Borthakur and Dhingra, 1979*), goat (*Abu-Zaid and Gad, 1999*), in camel (*ELGaafary and Aly; 1977*), while *ELGaafary et al., (1980)* in buffalo named them as lateral and caudal branches.. In the donkey, the testicular artery winds round the caudal pole of the testis and gives off numerous collateral branches (*Fehlings and Pohlmayer, 1978*).

The present investigation and *Hees et al., (1984)* in bull as well as *Polgaj et al., (2008)* in human stated that the pampiniform plexus lie between the convolutions of the testicular artery and fill the available space in such a way that the central arterial windings are completely surrounded by the densely lying veins. They added that the superficial convolutions of the artery are not covered by veins on their convex sides. On the other hand, *Ergün, et al., (1997)* in man revealed that a group of veins has no close topographical relationship to the testicular artery ran at a distance of several centimeters embedded within fatty tissue.

References

- Abu-zaid, R.M. and Gad, M.R. (1999).** Goat Testicular Blood Supply: A Study by Corrosion Cast and Angiography. Journal of the Egyptian veterinary medical association, 59 (6).
- Almeida, M.; Neto, A., Penno, A.; Júnior, A.; Menezes, D., Pereira, G.; Azevêdo, L. and Carvalho, M. (2008).** Testicular arteries systematization based on different levels of scrotal configuration in caprines. Ciência Rural., 38 (5).
- Amselgruber, W.; Sinowatz, F. (1987).** Zur Beziehung zwischen der Arteria testicularis und den Venen des Plexus pampiniformis beim Bullen. Anat Histol Embryol., 16: 363–370.
- Asala, S.; Chaudhary, S.; Masumbuko-Kahamba, N. and Bidmos, M. (2001).** Anatomical variations in the human testicular blood vessels. Ann Anat., 183: 545-549.

- Borthakur, S. and Dhingra, L.D. (1979).** Anatomical studies on the blood vessels of the testis in buffalo (*Bubalus bubalis*). *Indian J. Anim. Sci.*, 49: 266.
- Chubb, C. and Desjardins, C. (1982).** Vasculature of the mouse, rat, and rabbit testis-epididymis". *Am. J. Anat.*, 165: 357–372.
- Dhingra, L. (1979).** Angiarchitecture of the arteries of the testis of goat (*Capra aegagrus*). *Zbl. Vet. Med. C. Anat. Histol. Embryol.*, 8: 193-199.
- Dhingra, L. (1979).** Angioarchitecture of the buffalo testis. *Anatomischer Anzeiger.*, 146: 60–68.
- Dhingra, L. (1980).** Angioarchitecture of Sheep Epididymis. *Haryana agric. Univ. J. Res.*, X (1): 115-122.
- Dhingra, L. (1980).** Angioarchitecture of the Epididymis of Indian Donkey Stallion. *Indian vet. J.*, 57: 300-304.
- Elayat M. A., Khalil K. M., Farag F. M. and Rizk H.M (2014).** Gross anatomical studies on the pattern and density of the tunica vasculosa testis in some farm animals (buffalo, ram, camel, donkey and rabbit). *Benha veterinary medical journal*, vol. 26, no. 1:1-9.
- EL-Gaafary, M.A. and Aly, A.A. (1977).** Anatomical studies on the arterial supply of the testis and epididymis of the dromedary camel. *Assiut Veterinary Medical. J.*, 4 (7).
- El-Gaafary, M.A.; Aly, A.E. and El-Ayat, M.A. (1980).** Morphological studies on the testicular artery in the Egyptian water buffalo (*Bos Bubalis L.*). *The egyptain veterinary medical journal*, XXVIII (28).
- Ergün, S.; Bruns, T.; Soyka, A. and Tauber, R. (1997).** Angioarchitecture of the human spermatic cord. *Cell Tissue Res.* 288: 391–398
- Fehlings, K. and Pohlmayer, K. (1978).** Die Arteria testicularis und ihre Aufzweigung im Hoden und Nebenhoden des Esels (*Equus africanus f. asinus*). *Korrosions anatomische und rontgenologische Untersuchungen. Zbl. Vet. Med. C. Anat. Histol. Embryol.*, 7: 74.
- Harrison, R.G. and Weiner J.S. (1949).** Vascular patterns of the mammalian testis and their functional significance. *Journal of Experimental Biology*, 26: 304–316.
- Harrison, R.G. (1949).** The comparative anatomy of the blood supply of the mammalian testis. *Proc. Zool. SOC. (London)*, 119: 325-344.
- Harrison, R.G. (1949):** The distribution of the vassal and cremasteric arteries to the testis and their functional importance. *Journal of Anatomy*, 83: 267–282.
- Hees, H.; Leiser, R.; Kohler, T. and Wrobel, K. (1984).** Vascular morphology of the bovine spermatic cord and testis. Light and scanning electron-microscopic studies on the testicular artery and pampiniform plexus. *Cell Tissue Res.*, 237: 31–38.
- Joffre, M. and Kormano, M. (1975).** An Angiographic Study of the Fox Testis in Various Stages of Sexual Activity. *Anat. Rec.*, 183: 599-604.
- Khalil K. M., (2010).** Comparative anatomical studies on the vascular architecture of the blood vessels of the testis of some farm animals (buffalo, ram, camel, donkey and rabbit). *B.V.Sc., Cairo University. Faculty of veterinary medicine. Anatomy and embryology department.*
- Mustafa, M.D.; Labib, M.D.; El-Khayat, M.D.; El-Shahat, M.D. and Gadallah, M.D. (2008).** Human testicular arterial supply: gross anatomy, corrosion cast, and radiologic study. *Fertility and Sterility*. 90 (6).
- Nomina Anatomica veterinaria (2005).** *Vet. Anat. Nomenclature of the world association vet.anat.*, 5th edition.
- Osman, D.I.; Tingari, M.D. and Moniem K.A. (1979).** Vascular supply of the testis of the camel (*Camelus dromedarius*). *Acta Anat.*, 104: 16–22.
- Polguy, M.; Jędrzejewski, K.S. and Bolanowski, W. (2008).** Comparison of blood vessels complex of human and bovine masculine gonad. *Folia Morphologica* 67: 87–97.
- Polguy, M.; Sopinski M.; Jędrzejewski, K.S.; Bolanowski, W. and Topol, M. (2011).** Angioarchitecture of the bovine tunica albuginea vascular complex – A corrosive and histological study. *Research in Veterinary Science journal*. 181-187.
- Rajtová, V. and Danko, J. (2001).** Vasculature of testis, epididymis and ductus deferens of rabbit. *The arteries. ACTA VET. BRNO.* 70: 3-7.
- Raman, J.D. and Goldstein, M. (2004).** Intraoperative characterization of arterial vasculature in spermatic cord. *Urology*, 64: 561-564.

- Suzuki, F. (1982).** Microvasculature of the mouse testis and excurrent duct system. Am. J. Anat., 163: 309-325.
- Waites, G.M.H. and Moule, G.R. (1960).** Blood pressure in the internal spermatic artery of the ram. J. Reprod. Fertil.,1: 223-229.
- Wilkens, H. and Mtiunster, W. (1976).** Arterian und venen in: Nickel, R.; Schummer, A. and Seiferle, Lehrbuch der Anatomic der Haustier, (3). Verlag paul parey, Berlin, Hambourg.

Access this Article in Online	
	Website: www.ijarbs.com
	Subject: Veterinary Medicine
Quick Response Code	
DOI: 10.22192/ijarbs.2017.04.02.011	

How to cite this article:

Khalifa, E.F. and Nawal, A. Noor. (2017). Anatomical study on the testicular artery of bull (Bos Taurus). Int. J. Adv. Res. Biol. Sci. 4(2): 80-89.
DOI: <http://dx.doi.org/10.22192/ijarbs.2017.04.02.011>