



## **Prevalence and pathology of abnormalities of inflation in sheep**

**Amaravathi M\*, K. Satheesh, P. Annapurna and K V Subramanyam**

Department of Veterinary Pathology, N.T.R College of Veterinary Science,  
Gannavaram – 521 102, Andhra Pradesh

\*Corresponding author: [ammu.nihal@gmail.com](mailto:ammu.nihal@gmail.com)

### **Abstract**

The present study was conducted on 187 sheep to investigate the pathology of spontaneous lung lesions in slaughtered sheep. Abnormalities of inflation were observed in 22 (11.76%) cases out of 187 lungs examined that included pulmonary emphysema and atelectasis. Pulmonary emphysema was seen with an incidence of 9.09%. Grossly, sharply defined foci of pale and enlarged emphysematous areas were observed that showed crepitation and depression upon pressure. Microscopically, sections of lung revealed distended alveoli and ruptured interalveolar septa forming giant alveoli. Atelectasis was noticed with an incidence of 2.67%. Grossly, dark red to bluish areas depressed below the surface of the lungs were present. Microscopically, slit-like collapsed alveoli with narrow lumen were observed.

**Keywords:** Abnormalities of inflation, Atelectasis, Pulmonary emphysema.

### **Introduction**

Non-infectious conditions like abnormalities of inflation and circulatory disturbances are commonly seen in the lungs. This disease causes stress on heart and makes it work harder to pump blood into the lungs. The disease causes permanent holes in the lungs and the airways become obstructed. It causes great difficulty for breathing and generally impaired functioning in animal's entire body. It is an irreversible process and once lung cells are affected, there is no way to rehabilitate them. It causes air to get trapped in the lungs and blow up like a balloon thus affecting normal function of lung.

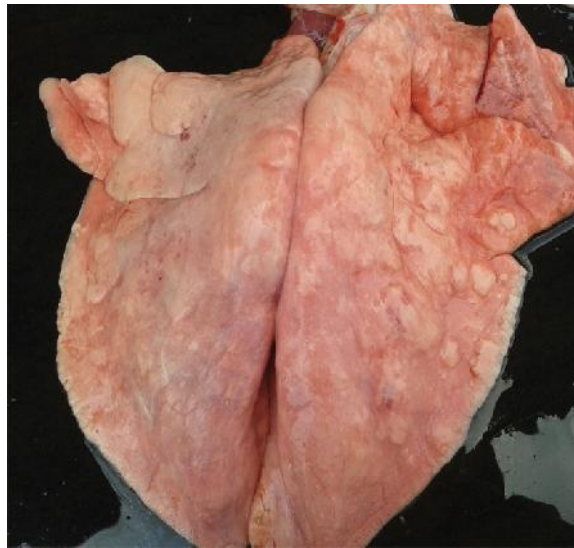### **Materials and Methods**

A cross – sectional study was carried out in a total of 988 lung samples of sheep collected from various slaughter houses located in and around Vijayawada and Tirupati apart from the animals necropsied in the

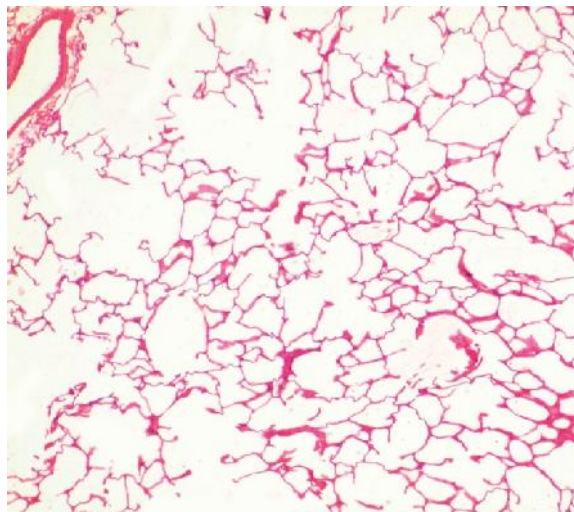
Department of Veterinary Pathology, N.T.R College of Veterinary Science, Gannavaram and from field mortalities during the period of June 2013 – July 2014. The animals were thoroughly examined for gross lesions in lungs if any. The lung with detectable lesions were collected in 10% formalin and processed for routine histopathological examination. Sections of 4-5 $\mu$  thick sections were stained with haematoxylin and eosin.

### **Results**

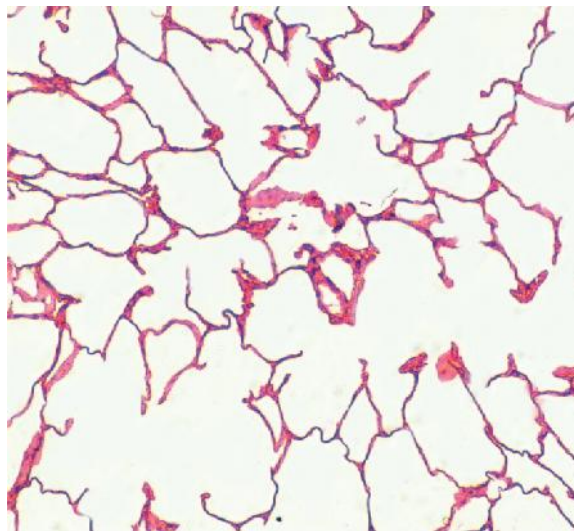
In the present study, pulmonary emphysema was seen with an incidence of 9.09%. Grossly, sharply defined foci of pale and enlarged emphysematous areas (Fig.1) involving one or more lobes of lungs slightly projecting from the neighbouring areas were observed that showed crepitation and depression upon pressure. Microscopically, sections of lung revealed distended alveoli and ruptured interalveolar septa forming giant alveoli (Fig.2 & 3).



**Figure 1** Lung parenchyma with well defined pale areas



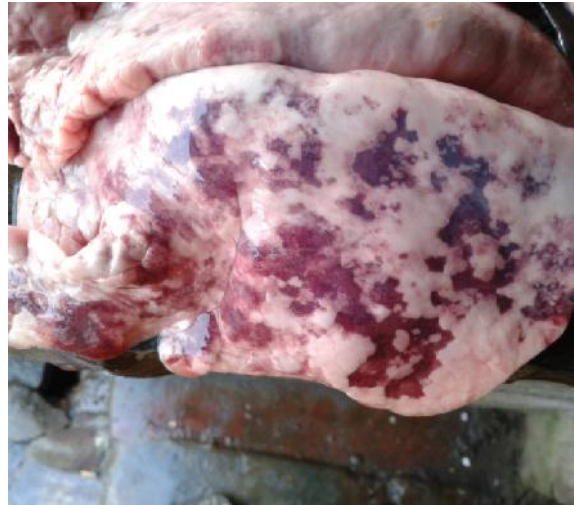**Figure 2** Lung section showing giant alveoli H&E x40.



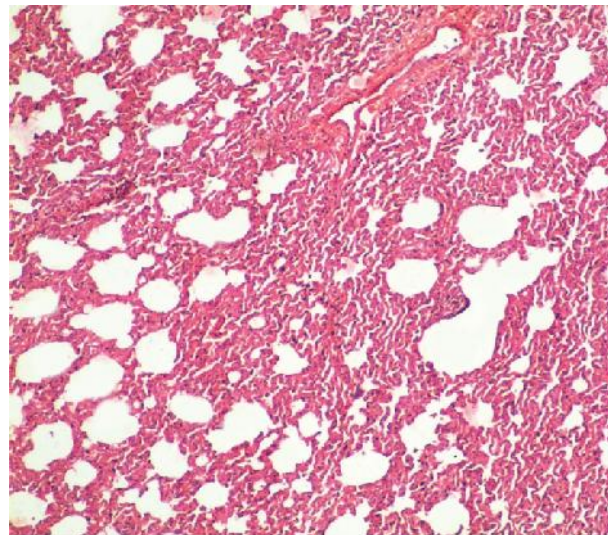
**Figure 3** Lung section showing distended alveoli and ruptured interalveolar septa forming giant alveoli

Atelectasis was noticed with an incidence of 2.67%. Grossly, dark red to bluish areas, depressed below the surface with firm texture were observed in one or more lobes of the lungs (Fig.4). Microscopically, atelectatic areas revealed slit-like collapsed alveoli

with narrow lumen (Fig.5) and with emphysematous foci in the adjacent areas. Alveolar walls appeared parallel and in apposition with no inflammatory change either in the alveoli or in the interstitium.



**Figure 4** Note dark red to bluish areas depressed below the surface of the lung.



**Figure 5** Lung section showing slit-like collapsed alveoli with narrow lumina H&E x 40.

## Discussion

Incidence of pulmonary emphysema (9.09%) noticed in the present investigation was lower than the previous reports by Sriraman and Rama rao (1980), Chattopadhyay et al., (1986), Priyadarshi et al., (2013) and Regassa et al., (2013) and higher than that reported by Kamil and Parihar (1990), Kumar et al., (2005), Dar et al., (2013a) and Belkhiri et al., (2014).

In the present study, emphysema of lungs revealed sharply defined foci of pale, enlarged areas projecting from surface involving one or more lobes of lungs grossly and distension and rupture of alveolar walls forming variably sized giant alveoli microscopically which were in accordance with the findings of Kumar et al., (2005) and McGavin and Zachary, (2007). However, puffy lungs with rib imprints observed grossly by Priyadarshi et al., (2013) were not evident in the present study.

Atelectasis was observed with an incidence of 2.67% in the present investigation. Perusal of the literature revealed a higher incidence of 5.14% (Kumar et al., 2005) and a lower incidence of 1.0% and 2.55% by Sriraman and Rama rao (1980) and Belkhiri et al., (2014) respectively in sheep.

Grossly, dark red to bluish areas depressed below the surface with firm texture were noticed in the present study that revealed slit-like, collapsed alveoli with narrow lumen microscopically. These findings were in corroboration with the description of Kumar et al., (2005). Obstructive atelectasis, also known as resorption atelectasis is common in animal species with poor collateral ventilation like sheep and is due to obstruction of air from reaching distal airways because of blockage by exudate (McGavin and Zachary, 2007).

## References

1. Belkhiri, M., Benhathat, Y. and Tlidjane, M. 2014. Classification and frequency of ovine pulmonary lesions in tiaret's slaughterhouse. Research Journal of Pharmaceutical, Biological and Chemical Sciences, Vol.5 (2): 1181-1188.
2. Chattopadhyay, S. K., Kumar, R., Kumar, P. N. and Vanamayya, P. R. 1986. Pulmonary affections in sheep: An etiopathological study. Indian journal of Comparative Microbiological Immunological Infectious Diseases, Vol. 7 (4): 182-184.
3. Dar, L. M., Darzi, M. M., Mir, M. S., Kamil, S. A., Rashid, A. and Abdullah, S. 2013. Prevalence of lung affections in sheep in northern temperate regions of India: A postmortem study. Small Ruminant Research, 110, 57-61.
4. Kamil, S. A. and Parihar, N. S. 1990. Prevalence of lung lesions of natural origin in sheep. Indian Journal of Animal Sciences, Vol.60, No.11:1319-1320.
5. Kumar, R. P., Kumar, R., Somawane, G. G., Paliwal, O. P. and Sharma, A. K. 2005. Studies on pathology of ovine pneumonias and experimental *Pasteurella multocida* infection in rabbits. Indian Journal of Veterinary Pathology, Volume 29, Issue 29: 153.
6. McGavin, M. D. and Zachary, J. F. 2007. Pathologic Basis of Veterinary Disease. 4<sup>th</sup> Edn. Mosby Elsevier Westline Industrial Drive, St. Louis, Missouri, PP: 492-531.
7. Priyadarshi, B. H., Joshi, D.V., Patel, B. J., Raval, S. H. and Patel, H. A. 2013. Pathomorphology of spontaneously occurring pulmonary lesions in sheep (*Ovis aries*). Ruminant Science, Vol 2, No.1: 31-35.
8. Regassa, A., Moje, N., Megersa, B., Beyene, D., Sheferaw, D., Debela, E., Abunna, F. and Skjerve, E. 2013. Major causes of organs and carcass condemnation in small ruminants slaughtered at Luna Export Abattoir, Oromia Regional state, Ethiopia. Preventive Veterinary Medicine, 110, 139-148.
9. Sriraman. P. K. and Rama Rao, P. 1980. A survey of disease conditions in adult sheep of Andhra Pradesh. Indian Veterinary Journal, 56: 971-978.

Access this Article in Online	
	Website: <a href="http://www.ijarbs.com">www.ijarbs.com</a>
	Subject: <b>Veterinary Pathology</b>
<b>Quick Response Code</b>	

### How to cite this article:

Amaravathi M, K. Satheesh, P. Annapurna and K V Subramanyam. (2016). Prevalence and pathology of abnormalities of inflation in sheep. Int. J. Adv. Res. Biol. Sci. 3(3): 43-46.