



## Hepato-protective activity of three different extracts of *Butea monosperma* in CCl<sub>4</sub> and Isoniazid induced toxicity in wistar rats

Shweta Sharma\* and B.K. Mehta

Department of Chemistry and Biochemistry, Vikram University, Ujjain (M.P.) India

\*Corresponding author- Ms. Shweta Sharma, E-mail: [sharma.harshali10@gmail.com](mailto:sharma.harshali10@gmail.com)

### Abstract

**Objective:** In this study the comparative hepato-protective efficacy of aqueous, ethanolic or benzene-acetone extracts of *Butea monosperma* (AEBM, EESC and BAEBM, respectively) were evaluated in carbon tetra chloride (CCl<sub>4</sub>) and isoniazid (INH) induced toxicity.

**Material & Method:** For this, two parallel sets of experiments were performed. Hepatotoxicity was induced by either single dose of CCl<sub>4</sub> or regular doses of INH (100 mg/kg b.w., i.p.). In both experiments standard drug (silymarin, 100 mg/kg, p.o.) and test extracts (500 mg/kg for each extract) were given for ten days. Serum liver function enzymes were estimated spectrophotometrically.

**Results:** Both CCl<sub>4</sub> and INH treated animals showed significant increased values of serum alkaline phosphatase, aspartate transaminase, alanine transaminase and TBil (P<0.001 for all). However, these were found to be restored in one or more test extracts. The decreased values of these parameters were seemed to be less or more equivalent to standard drug.

**Conclusion:** Present findings suggest that the BM extracts can ameliorate hepatic injury. However, different extracts showed differential protective activities against parameter used, in both experiments. Possibly, different extracts contain different phytochemicals.

**Keywords:** CCl<sub>4</sub>, hepatoprotective, silymarin, *Butea monosperma*, total bilirubin, isoniazid

### Introduction

For long different parts of *Butea monosperma* (BM) has been medicinally used as antifungal agent, antioxidant, depurative and tonic. The bark of this plant is also a good source of polyphenolic compounds and flavonoids. In addition to this, hepato-protective potential of BM has also been reported earlier[1,2]. Since, hepatic tissues are prominently involved in drug clearance, detoxification and metabolism of carbohydrate, protein and fats and also serve as the primary site of almost all the biochemical pathways for growth, fight against disease, nutrient supply and

storage and energy provision etc[2,3]. Thus, to maintain a healthy liver is an essential factor for the overall health and well being[4]. Contradictory, because hepatic cells are core site of detoxification and drug metabolism, thus are more exposed by certain toxin/drug/ foreign agents[3-5].

Most of the hepatotoxins cause tissue damage via generation of excessive free radicals[6]. Carbon tetrachloride (CCl<sub>4</sub>) is a known pro-oxidative compound which converted into a trichloromethyl

peroxyl radical (+OOCCL<sub>3</sub>) in tissues and thus causes damages to tissue lipids and proteins[7]. On the other hand, Isoniazid (INH) is one of the most commonly used antibiotic has been found to be associated with increased oxidative stress and severe hepatotoxicity[8]. In a number of scientific studies high free radical exposure have been reported to induce membrane lipid peroxidation and protein oxidation as well as deleterious effects on enzymatic system of the cells[6-8]. In both of the above mentioned treatments, the serum values of alkaline phosphatase (ALP), aspartate transaminase (AST), alanine transaminase (ALT) and total bilirubin (TBil) were found to be abnormally increased, hence are often used as biochemical markers of hepatic injury[9].

Antioxidants are well known protective agents which either inhibit generation of free radicals or by enhance their removal[7,9]. Thousands of herbs have been reported to have antioxidative property[6,10-12]. BM is known source of potent antioxidants such as quercetin, flavanoids, tannins, triterpenoid, gallic acid, ellagic acid, resin etc. In different premedical and medical analysis different parts of this plant has been known to show anti-diabetic, antibacterial and the inflammatory action[1,9,14]. But available reports also showed differential potencies of herbs in different extraction medium. As diverse active constituents of herb may have different solubility in different solvents, thus medicinal properties of the same herb vary with extraction system[15]. So, this investigation was aimed to find out the extract with greater protective efficiency of the BM bark, to cure drug induced hepatic injury. For this, the comparative hepatoprotective efficacy of ethanolic, aqueous and benzene: acetone (50:50) extracts of BM in CCl<sub>4</sub> and INH induced hepatotoxic rats were analyzed. Enzymatic activity such as ALP, AST and ALT as well as serum total bilirubin (TBil) were taken as studied parameters. In both experiments, silymarin a known hepato-protective drug[9] was used as standard drug. Tissue histology was also performed to authenticate the results.

## Materials and Methods

### Chemicals

All chemicals were of the highest commercially available purity. The bark of *Syzygium cumini* were collected from D-1 university campus, Dewas road, Ujjain, M.P., India. The identification of plant was done in department of botany, Safia college of science,

Bhopal. (M.P.) and the voucher specimen 437/ Bot /saf/13, was deposited in the Safia college of science, Bhopal.

### Preparation of extracts

The bark of BM was cleaned, air-dried at room temperature on a cool dry place keeping away from direct sunlight for 7 to 10 days and finally ground to a coarse powder. The powdered bark was exhaustively extracted in soxhlet extractor with ethanol (100%), removal of solvent under reduced pressure afforded solid mass. The obtained ethanolic extract was stored at 4 C for further use. Similar process was repeated to obtain benzene:acetone (50:50) extract where, the air dried bark powder was systematically extracted in soxhlet extractor with benzene: acetone (50:50). And here again removal of solvent under reduced pressure afforded solid mass.

To obtained aqueous extract of BM bark, the fine powder of bark dissolved in 20 volume double distilled water and stirred for 4 hours on magnetic stirrer. After that, the solution was kept for 24 hour at room temperature. This suspension was then filtered by whatman filter paper (no. 1) and the filtrate was collected. The residue was again soaked with 700 ml distilled water to get additional extractive. The solvent was removed by using vacuum rotary evaporator, to yield powder. The powdered extract was stored at 4 C for further work.

### Animals

Healthy in-bred albino wistar rats of either sex (2-2.5 months old) were housed in polypropylene cages under constant temperature (27±2°C) and photo-schedule (14 h light and 10 h dark). They were provided rodent feed (Golden Feeds, New Delhi, India) ad libitum and had free access to boiled drinking water. The approval of departmental ethical committee for handling and maintenance for experimental animals was also obtained before starting the experiments.

### Induction of hepatotoxicity

Hepatic injury was induced by single oral administration of CCl<sub>4</sub> mixed with olive oil as vehicle in 1:1 ratio (3 ml/kg of rat body weight). While in other experiment regular doses of INH (100 mg/kg b.w., i.p.) were given to healthy animals for successive ten days.

### Acute oral toxicity study

Acute oral toxicity study was carried out in young healthy female mice using the 'Limit dose test of up and down procedure' (UDP) according to organization for economic corporation and development guidelines 425. Dose up to 2000 mg/kg body weight (bw) was given in an increasing dose order and animals were checked for general behavioural, physical and autonomic changes.

### Experimental design- the overall research work was divided into two experiments.

In the experiment 1<sup>st</sup>, a total of 36 rats were used, which were divided into 6 groups having 6 animals in each group as follows:

Group I: Normal control rats received 1ml/100gm of 0.5% CMC using an intragastric tube for 7days.

Group II: Negative control rats received CCl<sub>4</sub> 3 ml/kg, p.o. only once at day 1.

Group III: Rats received CCl<sub>4</sub> 3 ml/kg, p.o. and silymarin (100mg/kg, p.o.) for next 10 days, designated as STAND group.

Group IV: Rats received CCl<sub>4</sub> 3 ml/kg, p.o. and aqueous extract of BM (500mg/kg p.o.) once daily for 10 days, designated as AEBM group.

Group V: Rats received CCl<sub>4</sub> 3 ml/kg, p.o. and ethanolic extract of BM (500mg/kg p.o.) once daily for 10 days, designated as EEBM group.

Group VI: Rats received CCl<sub>4</sub> 3 ml/kg, p.o. and benzene- acetone extract of BM (500mg/kg p.o.) once daily for 10 days, designated as BAEBM group.

In the experiment 2<sup>nd</sup>, a total of 36 rats were used, which were divided into 6 groups having 6 animals in each group as follows:

Group I: Normal control rats received 1ml/100gm of 0.5% CMC using an intragastric tube for 10 days.

Group II: Negative control group given isoniazid (100mg/kg, i.p.) only once at day 1, designated as induced group

Group III: Rats received isoniazid 100mg/kg, i.p. and silymarin (100mg/kg, p.o.) simultaneously, for 10 days, designated as stand group.

Group IV: Rats received isoniazid 100mg/kg, i.p. and aqueous extract of BM (500mg/kg p.o.) once daily for 10 days, designated as AEBM group.

Group V: Rats received isoniazid 100mg/kg, i.p. and ethanolic extract of BM (500mg/kg p.o.) once daily for 10 days, designated as EEBM group.

Group VI: Rats received isoniazid 100mg/kg, i.p. and benzene-acetone extract of BM (500mg/kg p.o.) once daily for 10 days, designated as BAEBM group.

At the end of the experiments on 10<sup>th</sup> day, animals were kept on overnight fasting and blood was collected by orbital puncture method. This blood was then allowed to clot for 30 minutes at room temperature. The serum was separated by centrifugation at 3000 rpm at 30°C for 15 minutes.

### Biochemical estimation

The serum samples were analyzed spectrophotometrically for ALP, AST, ALT and total bilirubin (TBil) levels using standard kits (Span diagnostics Ltd). Activity of AST and ALT were measured at 505 nm and is expressed as IU/ L of serum. In ALP assay the blue color developed which was read at 510 nm against blank and the activity is expressed as IU/L of serum. To estimate the TBil readings were taken at 540 nm, the level of total bilirubin was expressed as mg/ dl of serum [9].

### Histological study

Histopathological study was done using protocol of Deepa and Varlakshmi [16]. Tissues were fixed in 10% formaldehyde and then dehydrated in descending grades of isopropanol, cleared in xylene, and then embedded in molten paraffin wax. These fixed tissues were subsequently cut in to 5 µm thick sections using microtome. The ribbons were then stained with hematoxylin and eosin and viewed under light microscope to study histopathological changes.

### Statistical analysis

Data are expressed as mean ± SE. Statistical analysis was done by using one -way ANOVA followed by unpaired student's t-test and p-values of 5% and less were considered as significant.

### Results

In case of acute toxicity test, all three extracts were found to be safe upto 2000 mg/kg body weight. While, In first experiment, As compared to normal control animals CCl<sub>4</sub> induced animals showed significant increased values of serum ALP, AST, ALT and TBil (P<0.001, for all). As already demonstrated earlier, here also treatment with standard drug significantly reduced the values of all above mentioned parameters (P<0.001 for all). Although, all three herbal extracts

were found to be significantly effective against CCl<sub>4</sub> induced toxicity, but maximum reduction for serum ALP was seen in BAEBM, while, EEBM administered animals exhibited maximum protection for AST and TBil (P<0.05 than AEBM and BAEBM).

In second experiment, Treatment of INH exhibited considerable increase in serum values of all test parameters P<0.001) while parallel drug therapy of

silymarin or one of the three test extracts showed drastic decrease in almost all of the used parameters (at least P<0.05). In these results also BAEBM showed maximum restoration in ALP (P<0.05 more than other two test extracts) while aqueous extract was observed to be most effective for AST (P<0.05). however, for TBil no significant difference were seen among different extracts treated groups in both experiments.

**Table – 1: Acute toxicity study of AEBM, EEBM and BAEBM bark.**

S. No.	Extract used	100	200	500	1000	2000
1	AEBM	All animals survived	All animals survived	All animals survived	All animals survived	All animals survived
2	EEBM	All animals survived	All animals survived	All animals survived	All animals survived	All animals survived
3	BAEBM	All animals survived	All animals survived	All animals survived	All animals survived	1 died & rest survived

Where, (no. of animals in each group=3) drug doses in mg/kg body weight. AEBM (aqueous extracts of *Butea monosperma*), EEBM (ethanolic extracts of *Butea monosperma*), and BAEBM (benzene:acetone 50%-50% extracts of *Butea monosperma*).

**Table 2: Effects of different extracts of *Butea monosperma* (BM) in experimental animals.**

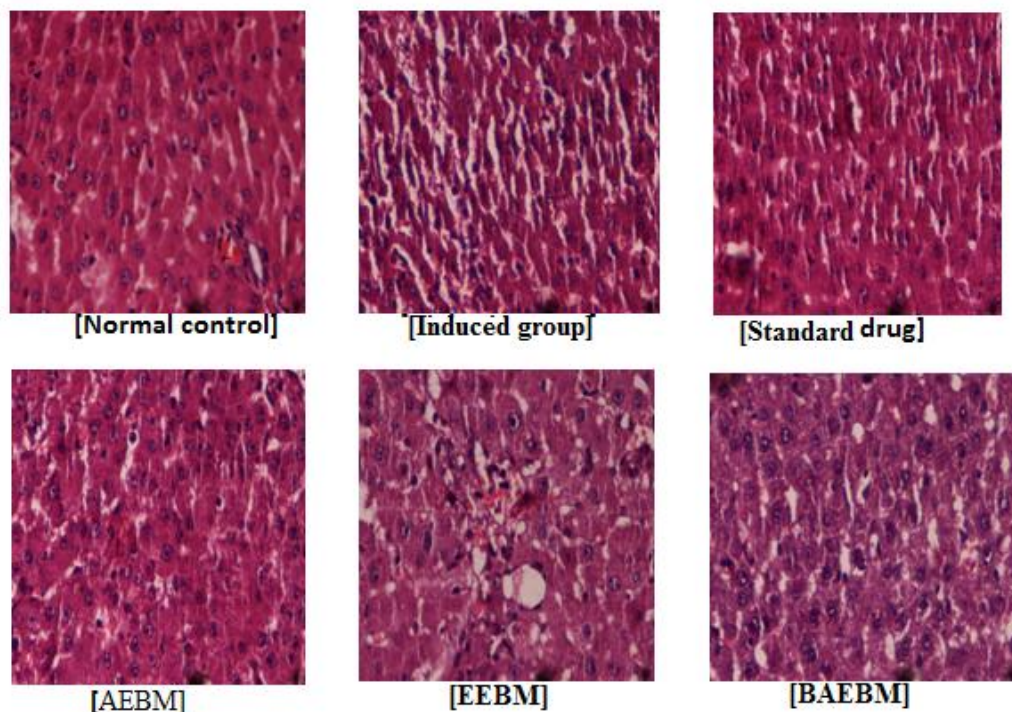
Experiment – 1 (CCl <sub>4</sub> induced hepatotoxicity)				
GROUP	ALP (IU/L)	AST (IU/L)	ALT (IU/L)	TBil (mg/dl)
Cont	69.60 ± 3.08	76.00 ± 2.60	72.0 ± 4.38	0.9 ± 0.25
Induced	141.40 ± 2.24*	181.30 ± 3.82*	148.50 ± 3.18*	4.38 ± 0.73*
STAND (100 ml/kg)	76.10 ± 3.05 <sup>c</sup>	87.00 ± 2.88 <sup>c</sup>	75.83 ± 3.06 <sup>c</sup>	2.26 ± 0.30 <sup>a</sup>
AEBM (500mg/kg)	130.40 ± 2.75 <sup>b,z</sup>	130.0 ± 3.09 <sup>c,z</sup>	86.50 ± 2.36 <sup>c,x,p</sup>	3.40 ± 0.42
EEBM (500mg/kg)	118.20 ± 2.60 <sup>c,z</sup>	119.16 ± 4.39 <sup>c,z,p</sup>	94.16 ± 2.30 <sup>c,y</sup>	2.80 ± 0.30 <sup>c</sup>
BAEBM (500mg/kg)	102.20 ± 1.26 <sup>c,z,p</sup>	131.00 ± 3.12 <sup>c,z</sup>	115.0 ± 3.50 <sup>c,z</sup>	3.90 ± 2.20 <sup>c,x</sup>

Where, Cont (Normal control), Induced (CCl<sub>4</sub> treated), STAND (CCl<sub>4</sub> + silymarin), AEBM (CCl<sub>4</sub>+ aqueous extract of BM), EEBM (CCl<sub>4</sub>+ ethanolic extract of BM) and BAEBM (CCl<sub>4</sub>+ benzene:acetone 50%-50% extracts of BM). Each bar represents the mean ± SE (n=6), \*P<0.001, as compared to normal control, <sup>a</sup>P<0.05, <sup>b</sup>P<0.01 and <sup>c</sup>P<0.001 as compared to CCl<sub>4</sub> treated group, <sup>x</sup>P<0.05, <sup>y</sup>P<0.01 and <sup>z</sup>P<0.001, as compared to standard drug while <sup>p</sup>P<0.05 increased than other herbal extract treated group.

**Table 3: Effects of different extracts of *Butea monosperma* (BM) in experimental animals.**

Experiment – 2 (INH induced hepatotoxicity)				
GROUP	ALP (IU/L)	AST/AST (IU/L)	ALT/ALT (IU/L)	Total Bilirubin (mg/dl)
Cont	69.63 ± 0.36	75.05 ± 0.28	62.00 ± 0.33	0.8 ± 0.05
Induced (INH)	174.70 ± 1.34*	168.41 ± 0.66*	118.73 ± 0.89*	4.38 ± 0.03*
STAND (100 mg/kg)	75.15 ± 0.41 <sup>c</sup>	86.01 ± 0.40 <sup>c</sup>	68.60 ± 0.55 <sup>c</sup>	2.40 ± 0.13 <sup>c</sup>
AEBM 500mg/kg	118.45 ± 0.46 <sup>c,z</sup>	119.10 ± 0.64 <sup>c,z</sup>	78.25 ± 0.95 <sup>c,z</sup>	3.31 ± 0.10 <sup>c,z</sup>
EEBM 500mg/kg	121.43 ± 0.65 <sup>c,z</sup>	121.10 ± 0.59 <sup>c,z</sup>	70.65 ± 0.41 <sup>c,y,p</sup>	3.36 ± 0.11 <sup>c,z</sup>
BAEBM 500mg/kg	106.33 ± 0.45 <sup>c,z,p</sup>	120.10 ± 0.64 <sup>c,z</sup>	89.80 ± 0.59 <sup>c,z</sup>	3.40 ± 0.12 <sup>c,z</sup>

Where, Cont (Normal control), Induced (CCl<sub>4</sub> treated), STAND (CCl<sub>4</sub> +silymarin), AEBM (CCl<sub>4</sub>+ aqueous extract of BM), EEBM (CCl<sub>4</sub>+ ethanolic extract of BM) and BAEBM (CCl<sub>4</sub>+ benzene:acetone 50%-50% extracts of BM). Each bar represents the mean±SE (n=6), \*P<0.001, as compared to normal control, <sup>a</sup>P<0.05, <sup>b</sup>P<0.01 and <sup>c</sup>P<0.001 as compared to CCl<sub>4</sub> treated group, <sup>x</sup>P<0.05, <sup>y</sup>P<0.01 and <sup>z</sup>P<0.001, as compared to standard drug while <sup>p</sup>P<0.05 increased than other herbal extract treated group.



**Figure: 1 Histology of different experimental animals.**

## Discussion and Conclusion

The BM bark has been recognized to possess astringent, bitter, pungent, aphrodisiac and anthelmintic properties. Medicinally, it is also useful in tumors, bleeding, piles and ulcers treatment. Safe and non-toxic effects of the test extracts were re-established with acute toxicity assay, as also observed earlier. This study was performed to assess the comparative hepatoprotective activity of BM extracts in rats against CCl<sub>4</sub> and INH as hepatotoxin to find a better drug from same plant.

Induction of oxidative injury with the CCl<sub>4</sub> treatment has widely used and already been reported earlier [6,8-12]. In biological system CCl<sub>4</sub> get converted into trichloromethyl free radical by cytochrome P450 system, which is a highly reactive free radical species that result lipid peroxidation of membranes. This is a characteristic system of the xenobiotic induced hepatotoxicity and is a commonly used model for the screening of hepatoprotective activity [13-15]. Excessively generated free radicals may cause plasma membrane damage and lead to the leakage of cytosolic proteins into the blood stream [7]. Thus, increased serum values of cytosolic proteins are used as useful quantitative markers of hepatocellular damage. In this investigation also in CCl<sub>4</sub> induced rats the increased levels of AST, ALT, ALP and TBil indicated severity of hepatocellular damage by CCl<sub>4</sub> [8,13]. The INH used here, is actually an antibiotic drug but also known to cause oxidative injury particularly in liver cells [7]. Moreover, INH produces hydrazine metabolites (nitrogen free radicals) after metabolism. These reactive free radicals act as stimulator of lipid peroxidation resulting in cell death and hepatic necrosis. In this investigation also, INH treatment showed considerable liver injury. Which was resembles with earlier investigations [9,13].

Increased level of TBil indicated hepatobiliary disease and severe disturbance of hepatocellular function [15-18]. The extracts mediated suppression of the increased bilirubin level suggests the possibility of the extracts being able to stabilize biliary dysfunction. In a similar way, ALP is an active hydrolase enzyme in the cells lining the biliary ducts of the liver and its increased level indicates large bile duct obstruction, intrahepatic cholestasis, or infiltrative diseases of the liver [19-21]. In addition, AST and ALT both are vital transaminase enzymes and play central role in amino acid metabolism. Both of these are found in the different body's organs such as liver, heart, skeletal muscle, kidneys, brain, and red blood cells [16].

Serum AST and ALT level, and their ratio (AST/ALT ratio) are frequently measured clinically as biomarkers for liver health [17, 22]. Their increased level has been linked with abnormal liver functions, though these are not very specific to liver disease. Though, the toxin treated animals showed increased levels of these enzymes. Conversely, extract therapies attenuated the increased level of these enzymes in serum. Recovery towards the normalization suggests that these extracts caused parenchymal cell regeneration in liver, thus protecting membrane fragility and thereby decreasing enzyme leakage [21].

Histopathological examination of liver sections of the normal control group demonstrated normal cellular architecture with separate hepatic cells and a central vein. While, both induced groups exhibited disarrangement of hepatic cells with intense necrosis [12]. The liver sections of the rat treated with different drug therapies showed more or less recovery of the tissue damage than induced group [19].

Here, all three extracts were observed to be significantly effective against both toxins. Earlier studies showed that BM bark possesses beneficial polyphenolic compound, flavonoids, tannins, and other protective biochemicals [1, 16]. Thus the presence of these active ingredients could be considered responsible for the hepatoprotective activity of bark's extracts [17]. Further, comparison with silymarin indicated that in both experiments, all the extracts were significantly less effective than standard drug used. In addition, AEEM, EEEM and BAEM were found to be effective against different serum parameters used. These findings revealed that different extracts possess different active compounds which served via different mechanism [22]. Therefore, to get maximum benefits, either additional alteration in the composition of extracts or mixed extracts therapy could be applied.

In conclusion, treatment CCl<sub>4</sub> and INH both responsible for drastic elevated values of liver stress markers, indicated severe hepato-toxic events, which were observed to be completely recovered in silymarin drug therapy. Though, the three extracts possess appreciably effective protection against both toxins but these were comparatively less effective than standard drug. In addition, AEEM, EEEM and BAEM showed maximum efficacies in assay dependent manner which possibly indicated the presence of diverse group of active compounds which served via different pathways. Further investigations are needed with altered extraction method or mixed extracts therapy might provide better amelioration.

## References

- Panda S, Jafri M, Kar A and Meheta BK. Thyroid inhibitory, antiperoxidative and hypoglycemic effects of stigmasterol isolated from *Butea monosperma*. *Fitoter* 2008; 80:123–6.
- Yadava RN and Tiwari L. New antifungal flavone glycoside from *Butea monosperma*. *J Enzyme Inh Med Chem* 2007; 22(4):497-500.
- Jiang Y, Ren-xiu P, Jing Y, Rui K, Juan L. CYP2E1 mediated isoniazid-induced hepatotoxicity in rats. *Acta Pharmacologica Sinica* 2004 25:699-704.
- Halim AB, el-Ahmady O, Hassab-Allah S, Abdel-Galil F, Hafez Y, Darwish A. Biochemical effect of antioxidants on lipids and liver function in experimentally-induced liver damage. *Ann Clin Biochem* 1997; 34:656-63.
- Vadivu R, Vidhya S, Jayshree N. Standardization and evaluation of hepatoprotective activity of polyherbal capsule. *Int J Pharmac Sci Rev Res* 2013; 21:93-9.
- Mehta V, Sharma A, Kailkhura P, Malairaman U. Antioxidant, anti-inflammatory, and antidiabetic activity of hydroalcoholic extract of *Ocimum sanctum*: an in-vitro and in-silico study. *Asian J Pharm Clin Res* 2016; 9:44-9.
- Achliya GS, Wadodkar SG, Dorle AK. Evaluation of hepatoprotective effect of *Amalkadi Ghrita* against carbon tetrachloride-induced hepatic damage in rats. *J Ethnopharmacol* 2004; 90:229–32.
- Noda A, Hsu KY, Noda H, Yamamoto Y and Kurozumi T. Is Isoniazid-hepatotoxicity induced by the metabolite, hydralazine? *J UOEH* 1983; 5:183-90.
- Al-Sayed E, Abdel-Daim MM, Kilany OE, Karonen M, Sinkkonen J. Protective role of polyphenols from *Bauhinia hookeri* against carbontetrachloride-induced hepato- and nephrotoxicity in mice. *Ren Fail* 2015; 37:1198-207.
- Al-Sayed E, Martiskainen O, Seif el-Din SH, Sabra AN, Hammam OA, El-Lakkany NM, Abdel-Daim MM. Hepatoprotective and antioxidant effect of *Bauhinia hookeri* extract against carbon tetrachloride-induced hepatotoxicity in mice and characterization of its bioactive compounds by HPLC-PDA-ESI-MS/MS. *BioMed Res Int* 2014;245171.
- Fahmy NM, Al-Sayed E, Abdel-Daim MM, Karonen M, Singab AN. Protective effect of *Terminalia muelleri* against carbon tetrachloride-induced hepato and nephro-toxicity in mice and characterization of its bioactive constituents. *Pharma Biol* 2016; 54:303-13.
- Al-Sayed E, Abdel-Daim MM. Protective role of Cupressuflavone from *Cupressus macrocarpa* against carbon tetrachloride-induced hepato- and nephrotoxicity in mice. *Planta Med* 2014; 80:1665-71.
- Karavadi B, Suresh MX. Receptor identification and lead molecular discovery of phage encoded protein in tch8431/19a strain of streptococcus pneumoniae: a computational approach. *Int J App Pharm* 2016; 6:6-10.
- Pandit A, Sachdeva T, Bafna P. Drug-Induced Hepatotoxicity: A Review. *J Appl Pharmac Sci* 2012;2:233-43.
- Agrawal J, Kar A. Synergistic action of phytochemicals augments their antioxidative efficacy: an in vitro comparative Study. *Asian J Pharmac Clin Res* 2013; 6:121-6.
- Likhar R, Perumal P, Kolhe N, Bhaskar VH, Daroi P. Synthesis And Antioxidant Activity Of Novel 2-Aryl Substituted Benzothiazole Derivatives. *Int J Curr Pharm Res* 2015; 7:34-7.
- Sarkar S, Chakraverty R, Datta S, Ghosh A. In-vitro assays for neutralization of snake venom using herbal drugs: a review. *J Crit Rev* 2015;3:30-3.
- Yadava RN, Tiwari L. A potential antiviral flavone glycoside from the seeds of *Butea monosperma*. *J Asian Nat Prod Res* 2005; 7:185-8.
- Sehrawat A, Sultana S. Chemoprevention by *Butea monosperma* of hepatic carcinogenesis and oxidative damage in male wistar rats. *Asian Pac J cancer Prev* 2006; 7:140-8.
- Deepa PR, Varlakshmi P. Protective effects of certoparin sodium, a low molecular weight heparin derivative, in experimental atherosclerosis. *Clinica Chimica Acta* 2004; 339:105-15.
- O'Malley SS, Gueorguiev R, Wu R, Jatlow PI. Acute alcohol consumption elevates serum bilirubin: An endogenous antioxidant. *Drug and Alc Depend* 2015; 149:87–92.

22. Dharmalingam K, Stalin R, Sachidanandam P, Shanthi P. Chemotherapeutic efficacy of tridham and 1,2,3,4,6-penta-o-galloyl- -dglucose on antioxidants status and tumor markers in experimental mammary carcinoma in sprague-dawley rats. Asian J Pharm Clin Res 2016; 9:202-8.
23. Azab SS, Abdel-Daim M, Eldahshan OA. Phytochemical, cytotoxic, hepatoprotective and antioxidant properties of Delonix regia leaves extract. Med Chem Res 2013; 22:4269-77.

Access this Article in Online	
	Website: <a href="http://www.ijarbs.com">www.ijarbs.com</a>
	Subject: <b>Biochemistry</b>
<b>Quick Response Code</b>	
<b>DOI:</b> <a href="https://doi.org/10.22192/ijarbs.2016.03.11.031">10.22192/ijarbs.2016.03.11.031</a>	

**How to cite this article:**

Shweta Sharma and B.K. Mehta. (2016). Hepato-protective activity of three different extracts of *Butea monosperma* in CCl<sub>4</sub> and Isoniazid induced toxicity in wistar rats. Int. J. Adv. Res. Biol. Sci. 3(11): 247-254.  
**DOI:** <http://dx.doi.org/10.22192/ijarbs.2016.03.11.031>