



Toxicological effects of cypermethrin on sperm morphology in male rabbit

Yasser Salah Mahdi¹, Inam Badr Falih¹ and Nazih Wayes Zaid²

¹Department of Pathology, Collage of Vet. Med. University of Baghdad.

²Department of Surgery and Obstetric, Collage of Vet. Med. University of Baghdad.

*Corresponding author: ay.s-fcb@yahoo.com

Abstract

The current study was conducted to assess the toxic effect of cypermethrin-induced reproductive toxicity in male rabbits. cypermethrin 10% (64mg/kg) was used as orally .twenty five male rabbit was divided into two groups (cypermethrin group 15 animals and control group 10 animals) were killed at 3 periods (3 weeks, 6 weeks, and 9 weeks). Sperms were collected from the tail of epididymis by slicing and rinsing pressing techniques of each epididymis in 5 ml of physiological normal saline at 37 c in a small glass dish, then a drop of suspension was put on slide then stained by eosin-nigrosin stain. The presented results showed that there was significant sperm deformities in head, mid peace and tail of cypermethrin group as compared with control group. In conclusion, the study observed that cypermethrin have toxic effect on sperm morphology. It was therefore recommended that the use of Cypermethrin be applied with caution in animals as it may affect the fertility.

Keywords: Cypermethrin, rabbits, sperms

Introduction

Pyrethroids are typically grouped into two general classes, called type I and type II, on the basis of a combination of toxicological and physical properties. Type II pyrethroids, such as cypermethrin, are those with a cyano group and are characterized by their ability to elicit sinuous writhing (choreoathetosis) and salivation in mammals (Mueller, *et al.*, 2006). Cypermethrin is an insecticide in the synthetic pyrethroid family. It was first marketed in 1977 (Caroline, 1996). Cypermethrin is used as pesticide in large-scale commercial agricultural applications as well as in consumer products for domestic purposes (Debbab, *et al.*, 2014). In animals, Cypermethrin has been used as a chemotherapeutic agent against ectoparasite infestations (Wang, 2009). There have been reports of lowered fertility in experimental

animals exposed to Cypermethrin (Handerson, 1981 ; FAO, 1983 ; Assayed, *et al.*, 2008 and Ling, *et al.*, 2008). Furthermore, studies conducted on occupational insecticide workers have shown that exposure to these chemicals caused abortion, stillbirth, male infertility, neonatal deaths, congenital defects and testicular dysfunction (Kumar, *et al.*, 2000 and Saradha, and Mathur, 2006). El-Khalek *et al.* (1999) observed significant decreases in plasma testosterone levels in cypermethrin-treated rats.

2. Materials and Methods

2.1.Experimental Animals

The research was carried out at in Baghdad province, performed in Baghdad- college of veterinary medicine,

twenty five sexually-mature, healthy albino rabbits aged (6-8 months) and weighting between (1500 – 2000 KG) with clinically normal genitalia were used. The rabbits were divided into two groups of 15 rabbits for cypermthrine group and 10 rabbits for control group. They were given concentrate feed *adlibitum*.

2.2. Experimental Design and Treatment

The rabbits were divided into groups A and B, where A was the treated group (15 rabbits) and B the control group (10 rabbits). The rabbits in group (A) were administered Cypermethrin (10%) at the dose rate of (64mg/kg) body weight, orally. The control group (B) were administered distilled water at the same rate. These treatments were repeated every day for a period of 9 weeks divided in to 3 kills each 3 weeks.

2.3. Sperms collection and evaluation

Sperms were collected from the tail of epididymis by slicing and rinsing pressing techniques of each epididymis in 5 ml of physiological normal saline at 37 c in a small glass dish according to (Tajik and Hassan-Nejad 2008). The sperm were evaluated according to following parameters:

2.3.1 Sperms abnormalities: drop of sperm suspension was placed over the edge of a glass slide,

then a drop of Eosin-Nigrosin stain was added and mixed, then two smears of this prepared on another slide for examination for abnormal sperms morphology on light heated stage microscope under x40 and x100 objective power, when each smear dry it was examined immediately under coverslip. 200-400 sperms were counted in each smear and the final percentage was calculated by taking the average of two smears. . The sperm abnormalities was calculated as following equation according to (Türk et al., 2007):

$$\text{Sperm abnormalities \%} = \frac{\text{Number of abnormal sperms}}{\text{Total number of sperms}} \times 100$$

Results

Cypermethrin exposure resulted in a significant decrease in testicular sperm head counts, sperm motility and live sperm counts and increase in sperm abnormalities in cyp group as compared with control group. The percent of deformities was increased with significant difference ($p < 0.05$) between kills and control group. So as we show in (table1) cypermthrine group was the higher percent of deformities and showed significant increase form 1st killed to 3rd killed. The higher percent of deformities observed in 3rd killed reached to (57.6±3.35).

Table 1. Effect of group and period in the Deformities of sperms (%)

Groups	Period			LSD value
	K1	K2	K3	
Cypermthrin	37.0 ±6.45 A c	48.0±2.46 A b	57.6±3.35 A a	17.069 *
Control	15.0 ±1.58 C a	14.8±1.95 D a	16.2±2.08 D a	5.813 NS

* (P<0.05), NS: Non-significant.

Means having with the different big letters in same column (between groups) and small letters in same row (between period) differed significantly. (K1= 1st killed, k2= 2nd killed and k3= 3rd killed).

The results of cypermthrin effect on sperm morphology showing an increase in cypermethrin-induced Sperm morphological abnormalities as

compared with control group as summarized in the Table 2 and table 3.

Table (2) Types of deformities in cypermthrin group (1st, 2nd, 3rd killed)

Periods	K1	K2	K3
Types of deformities	Mean &SE	Mean &SE	Mean &SE
	37.0 ±6.45 c	48.0±2.46 b	57.6±3.35 a
In head (%)			
Narrow base	3%	3%	4%
Pear shape	4%	4%	3%
Small head	3%	3%	5%
Giant head	2%	3%	4%
Double head	0%	2%	2%
Acrosomal detach	2%	3%	4%
Free head	5%	5%	4%
Mid piece (%)			
Fracture neck	2%	3%	2%
Thickening mid piece	3%	4%	7%
Irregular mid piece	2%	4%	4%
Cytoplasmic droplet (%)			
Proximal	3%	4%	3%
Distal	1%	0%	2%
Tail (%)			
dag tail	1%	3%	5%
free tail	3%	4%	2%
coiled tail	3%	3%	4%
circle tail	1%	2%	3%
double tail	0%	1%	3%

Table (3) Types of deformities in control group (1st, 2nd, 3rd killed)

Periods	K1	K2	K3
Types of deformities	Mean & SE	Mean & SE	Mean & SE
	15.0 ±1.58 a	14.8±1.95 a	16.2±2.08 a
In head:			
Narrow base	0%	1%	0%
Pear shape	0%	0%	2%
Small head	2%	0%	1%
Giant head	0%	0%	0%
Double head	0%	0%	0%
Acrosomal detached	0%	0%	0%
Free head	5%	4%	5%
Mid piece:			
Fracture neck	1%	3%	3%
Thickening mid piece	0%	0%	0%
Irregular mid piece	0%	0%	0%
Cytoplasmic droplet:			
Proximal	0%	0%	0%
Distal	0%	0%	0%
tail:			
dag tail	0%	1%	0%
free tail	4%	2%	4%
coiled tail	2%	1%	1%
circle tail	0%	0%	0%
double tail	0%	0%	0%

The types of deformities were divided according to location (head, mid piece and tail) which showing varying abnormalities observed in (figure 1).

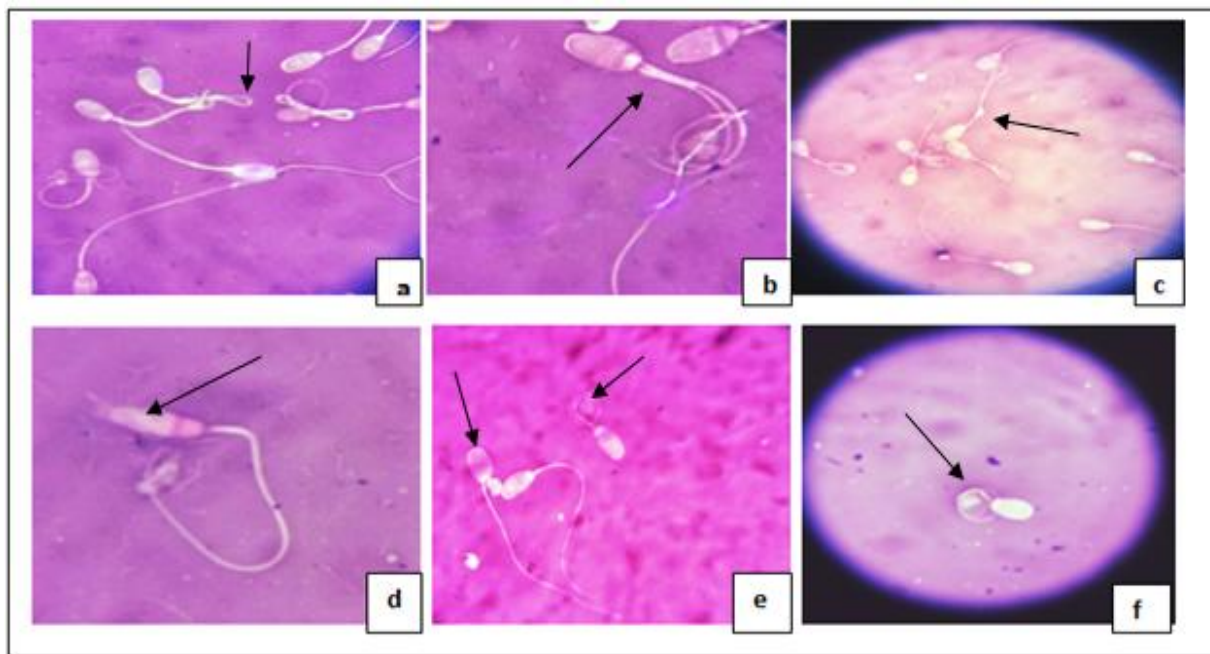


Figure (1) showed types of deformities in CYP group
(a) Showed dag tail, (b) show double tail. (c) show distal cytoplasmic droplet, (d) show abnormal head (narrow head), (e) show pear shape head and coiled tail, (f) show coiled tail.

Discussion

Exposure to environmental toxicants including pesticides is a proven factor in impairment of male reproductive system and infertility. Cypermethrin initially thought to be safe for household application, a number of recent reports showed its reproductive toxicity in mammalian and nonmammalian laboratory and wildlife animal species (Hu et al., 2013 and Assayed et al., 2010).

Accumulation of cypermethrin in testis and other reproductive organs may have accelerated oxidative stress leading to accelerated death of spermatogenic cells associated with sperm abnormalities (Sharma, et al., 2010). Decrease in sperm motility, live sperm and increase in the number of the abnormal sperm may be due to enhanced ROS production by cypermethrin in the testis and epididymis as observed in this study. Pesticide induced ROS production is known to adversely affect sperm motility, live sperm, and increased sperm abnormality (Joshi, et al., 2011 el-Demerdash, et al., 2004 and Kumar, et al., 2004). A significant elevation in the number of abnormal

shape of sperm head was noticed in cypermethrin exposed rats (Li, et al., 2013).

Yousef et al. (2003) showed that treating rabbits with the pyrethroid cypermethrin caused a significant decline in ejaculate volume, sperm concentration, total sperm output, sperm motility, total motile sperm per ejaculate and packed sperm volume, increased the numbers of abnormal and dead sperm.

However, a significant elevation in the number of abnormal shape of sperm head was noticed in higher dose groups cypermethrin as compared to control. It was observed that the abnormality in the shape of sperm head was dose-dependent. The cytological changes in the root tip cells of *Allium cepa* indicated that cypermethrin is having toxic effects on the root tip cells in the form of stickiness of chromosomes and also affect the mitotic activity. This study suggest that cypermethrin may have the potential to induce adverse effects on sperm head shape morphology of mouse (Kumar et al., 2004).

Conclusion

Based on the findings of this research it was concluded that treatment of animals with 64mg/kg body weight of Cypermethrin (orally) led to a significant reduction in the sperm quality and morphology significant affect in compared with control group, It was recommended that the use of 10% Cypermethrin at the dose of 64mg/kg body weight be applied with caution in animals as it may affect the fertility of the rabbits. The use of this formulation in animals should not be prolonged.

References

- Assayed, M. ; Salem, H. and Khalaf, A. (2008).** Protective effects of garlic extract and vitamin C against Cypermethrin reproductive toxicity in male rats. *Research Journal of Vet. Science*, 1: 1-5.
- Caroline, C. (1996).** Insecticide fact sheet. Journal of Pesticide Reform/Summer Vol. 16, No 2.
- Debbab, M.; El-Hajjaji, S.; Aly, A.; Dahchour, A.; El-Azzouzi M and Zrine A, (2014).** Cypermethrin Residues in Fresh Vegetables: Detection by HPLC and LCESIMS deca-methrin, permethrin, and their degradation products in soil. *J. of Agriculture* .
- El-Demerdash FM, Yousef MI, Kedwany FS, Baghdadi HH.(2004).** Role of alpha-tocopherol and beta-carotene in ameliorating the fenvalerate-induced changes in oxidative stress, hemato-biochemical parameters, and semen quality of male rats. *J Environ Sci Health B*.39:443–59.
- El-Khalik, M. (1999).** Toxicological profile for pyrethrins and pyrethroids, pesticide & sperm impact research pp.61-62.
- FAO. (1983).** Food production trends in Africa. Food and Agricultural Organisation of the United Nations. Rome.
- Handerson, H. and Parkinson, F.(1981).** Effect of cypermethrin on haematology, clinical chemistry and gonads of male rabbit. *Vet. Med. J. (Giza)*. 31(1): 32-37.
- Hassan, A.; Soliman, G. and Farag, A. et al.(1993).** Effect of the synthetic pyrethroids Sumicidin and S3206 on male rat fertility. *Vet Med J Giza* 41(2):33-38.
- Hu JX, Li YF, Li J, Pan C, He Z, Dong HY, (2013).** Toxic effects of cypermethrin on the male reproductive system: With emphasis on the androgen receptor. *J Appl Toxicol*.33:576–85.
- Jindal, S. and Panda, J. (1980).** Epididymal sperm reserves of the goat (*Capra hircus*). *Journal of Reproduction and fertility*. 59: 469-471.
- Joshi SC, Bansal B, Jasuja ND.(2011).**Evaluation of reproductive and developmental toxicity of cypermethrin in male male albino rats. *Toxicol Environ Chem.*; 93:593–602.
- Kumar S, Gautam AK, Agarwal KR, Shah BA, Saiyad HN.(2004).** Demonstration of sperm head shape abnormality and clastogenic potential of cypermethrin. *J Environ Biol*.25:187–90.
- Kumar, R. ; Pant, N. and Srivasta, S. (2000).** Chlorinated pesticides and heavy metals in human semen, *Int. J. Androl.*, Vol.23, 2000, p.145–149.
- Lawrence, J. and Casida, J. (1982).** Pyrethroid toxicology: mouse intracerebral structure-toxicity relationships. *Pestic. Biochem. Physiol.* 18:914.
- Li YF, Pan C, Hu JX, Li J, Xu LC.(2013).** Effects of cypermethrin on male reproductive system in adult rats. *Biomed Environ Sci*.26:201–8.
- Ling, S. ; Yu-Bang, W. ; Hong, S. ; Chen, Y. ; Xia, H. ; Jian-Hua, Q. ; Jian-wei, Z. and Xin-Ru, W. (2008).** Effects of Fenvalerate and Cypermethrin on rat sperm motility patterns in vitro as measured by computer assisted sperm analysis. *Journal of Toxicology and Environmental*.
- Mueller, U.; Lenton, L. & Ray, D. (2006).** Cypermethrin :Including ALPHA- AND ZETA-CYPERMETHRIN. *Cypermethrins X-X JMPR*.
- Osman, A. and El-Azab, E. (1974).** Gonadal and Epididymal Sperm Reserves in The Camel, *Camelus Dromedarius*. *J. Reprod. Fert.* 38: 425-430.
- Saradha, B. and Mathur, P. (2006).** Effect of environmental contaminants on male reproduction, *Environ. Toxicol. Pharmacol.*, Vol.21, p.34–41.
- Sharma P, Singh R.(2010).** Protective role of curcumin on lindane induced reproductive toxicity in male wistar rat. *Bull Environ Contam Toxicol*. 84:378–84
- Wang, X. ; Liu, S. ; Sun, U. ; Wu, J. ; Zhou, Y. and Zhang, J. (2009).** - Cypermethrin impairs reproductive function in male mice by inducing oxidative stress. *Theriogenology*, 72,599-611.
- World Health Organization (WHO) (2002).** The WHO Recommended Classification of pesticides by hazard, Guidelines to classification. (www.inchem.org/documentmts).
- Türk G, Atessahin A, Sönmez M, Yüce A, Ceribasi AO.(2007).** Lycopene protects against cyclosporine A-induced testicular toxicity in rats. *Theriogenology*.67:778–85.
- Tajik, P.; Hassan-Nejad Lamsoo M. (2008).** Assessment of epididymal sperm obtained from dromedary camel. *Iranian journal of veterinary research*, Volume 9, Issue 1, Page 46-50.

Yousef, M.I , El-Demerdash, F. M., Al-Salhen, K. S.(2003) Protective role of isoflavones against the toxic effect of cypermethrin on semen quality and testosterone levels of rabbits, J. Environ. Sci. Health, vol. 38, Issue 4B, p. 463–478.

Access this Article in Online	
	Website: www.ijarbs.com
	Subject: Toxicology
Quick Response Code	
DOI:10.22192/ijarbs.2016.03.10.007	

How to cite this article:

Yasser Salah Mahdi, Inam Badr Falih and Nazih Wayes Zaid. (2016). Toxicological effects of cypermethrin on sperm morphology in male rabbit. Int. J. Adv. Res. Biol. Sci. 3(10): 46-51.

DOI: <http://dx.doi.org/10.22192/ijarbs.2016.03.10.007>