



## **Kinetics Of The Hyoid Skeleton Of The Rock Dove (*Patagioenas livia*)**

**Fatma A. Al-Nefeiyy**

Biology Department, Faculty of Science, King Abdulaziz University, Jeddah, Saudi Arabia

### **Abstract**

The hyoid skeleton of the rock dove (*Patagioenas livia*) is a well developed. It consists of three axial unpaired elements and a paired hyoid horn. The axial skeleton comprises anterior paraglossale, a middle basihyale, and a posterior urohyale. The paired hyoid horn consists of ceratobranchiale and epibranchiale. The hyoid skeletal elements allows sites for attachment of extrinsic and intrinsic lingual muscles which are forces generate the mechanical structure of the tongue. The retraction of the tongue performs by the contraction of the muscle stylohyoideus. The muscle branchiomandibularis perform the protraction of the tongue. The expression of the anterior part of the tongue must done by the contraction of the muscle ceratoglossus. Bending of this part of the tongue is allowed by the contraction of the muscle hypoglossus anterior.

**Keywords:** rock dove, *Patagioenas livia*, axial skeleton, hyoid skeletal, tongue.

### **Introduction**

Birds has unique features which help them with the adaptations for life style, selecting or rejecting, transporting and manipulating the food towards the gullet. The structural adaptations of the feeding apparatus of birds protrude an important role for functional morphological studies. The jaw apparatus, lingual apparatus, and laryngeal apparatus are the components of the feeding apparatus of any bird. The shape and size of the various hyoid bones are indicative of what the tongue looks like and how it functions. Long hyoid horn bones mean that the tongue can be protruded well outside the lingual cavity. The movements of all these three components are coordinated with each others during feeding and drinking processes. The lingual apparatus, like the jaw apparatus plays a very significant role in selecting or rejecting, transporting and manipulating the food. Many studies (Zweers, 1974, 1982a; Zweers et al., 1977; Kooloos, 1986) have analyzed the synchronized interactions between the jaw and tongue during

feeding and drinking in several avian species. Birds show many examples of highly adaptations of their beak and tongue apparatuses as graspers, collectors, selectors, or detectors of food (Zweers et al., 1977, for mallards and Homberger 1980b, for parrots. Long-billed birds use catch and throw mechanism for the transport of their food. Bhattacharyya (1990) studied the functional morphological adaptation of the tongue in imperial Pigeons with the diversity of their feeding behavior. Korzoun et al., (2003) studied the morpho-functional analyses the skeleton and musculature of the bill and hyoid apparatus of Pigeons (Columbidae) and sandgrouse (Pteroclididae) that show a key of adaptation to vegetarian feeding. Bhattacharyya (1980, 1985) described the function morphology of the jaw and tongue muscles of the Common pigeon and of some Indian insect-eating birds; Zweers (1982a) studied the functional anatomy of feeding apparatus of the Pigeon. Korzoun et al. (2001, 2003, 2004) studied the distinctive morphofunctional features of the bill

and hyoid apparatus of turacos and *Momotus momota* and their relation to frugivory and omnivorous feeding adaptation and of the Hoatzin, *Opisthoco-mus hoazin* to leaf-eating. Full description of the hyoid skeleton of the Common kestrel, *Falco tinnunculus* has been done by Shawki (2006a). Igwebuike and Eze (2010) designed study to provide basic data on the anatomy of the oropharynx and tongue of the African pied crow, *Corvus albus*. Jung, et al., 2016 described the structural analysis of the tongue and hyoid apparatus in a woodpecker. Depending on whether the tongue aids in the catching and collecting of food, drinking or swallowing, or turning food morsels around, its anatomy in birds shows various species-specific modifications connected with, for example, the structures of the hyoid cartilage. Such modifications result in differing tongue mobility and the ability to slide the tongue out, extract food, and manipulate food in the beak cavity.

## Materials and Methods

### Animals:

Twenty adult rock dove were used in this study. Chloroform inhalation were used to kill birds. The specimens then were dissected under the binocular with camera Lucida attachment.

### Preparation of birds for gross anatomical study:

Birds were killed and the head and neck were separated. The specimens were dissected and then fixed in 10% formalin for 48 Hrs according to the method of (Calislar, 1977). For preservation, tongues were stored in 3% phenoxy-ethanol solution. The skin of the head and the neck was carefully removed under the binocular. For differentiation between muscles and connective tissues, iodine solution (Bock & Shear, 1972) were used for staining them. Camera Lucida was used to draw the figures and outlining the anatomical preparations.

### Preparation and staining of skeletal elements:

The method of (Minoru, 1976) was used to differentiate between the bone and cartilage. The skeletal elements were carefully dissected from the surrounding muscles, gland and fascia. Then, skeletal elements were fixed in 95% ethanol for 4 days, then were placed in acetone for one day to remove fats.

The samples were stained for 2 – 3 days in following staining solution at 37°C ; 0.3 % alcian blue 8GS in 70 % ethanol, 0.1 % alizarin red S in 95 % ethanol, acetic acid and 70 % ethanol. The stained samples were washed in Distilled water. The samples were cleared in 1 % aqueous solution of KOH for 12- 48 HRS.. Then, The samples were placed in aqueous solution of 20 % glycerin containing 1% KOH for 1 – 5 days. Finally, the specimens were cleared through 50 % and 80 % glycerin, and store in 100 % glycerin.

## Results

### Skeletal elements and sites of muscles

#### The hyoid skeleton and the mandible (Figs. 1&3)

The hyoid skeleton (Fig. 1) consists of three axial unpaired elements and a paired hyoid horn. The axial skeleton comprises anterior paraglossale, a middle basihyale, and a posterior urohyale. The paired hyoid horn consists of ceratobranchiale and epibranchiale. The hyoid horns are curved dorsolaterally reaching the posterior side of the skull. The mandible of the Rock dove (Fig. 3) is composed of two diverged rami, which are fused anteriorly through the mandibular symphysis. The medial and lateral surfaces of the mandible provides sites for origin of different muscles.

#### The paraglossale (PG.) and basihyale(BH.)

The muscle hypoglossus posterior originates (Fig.2) from the processus posterior paraglossalis affects of the paraglossale. Therefore, the full contraction of this muscle bends the paraglossale ventrally. Consequently, that full contraction produces a ventral bending the tip of the anterior part of the tongue. Meanwhile, the partial contraction of the muscle causes a ventral bending of the lingual nail which means the bending of the anterior tip of the tongue. The muscle tracheolateralis (Fig. 1) extends from the syrinx along the entire length of the cervical region to be inserted on the lateral surface of basihyale. This muscle tracheolateralis retracts the larynx

#### The Ceratobranchiale (CB.)

The bony ceratobranchiale provides sites of origin for the muscles; ceratoglossus, ceratohyoideus and branchiomandibularis, as well as an insertion site for muscle cricohyoideus (Figs. 1& 3).

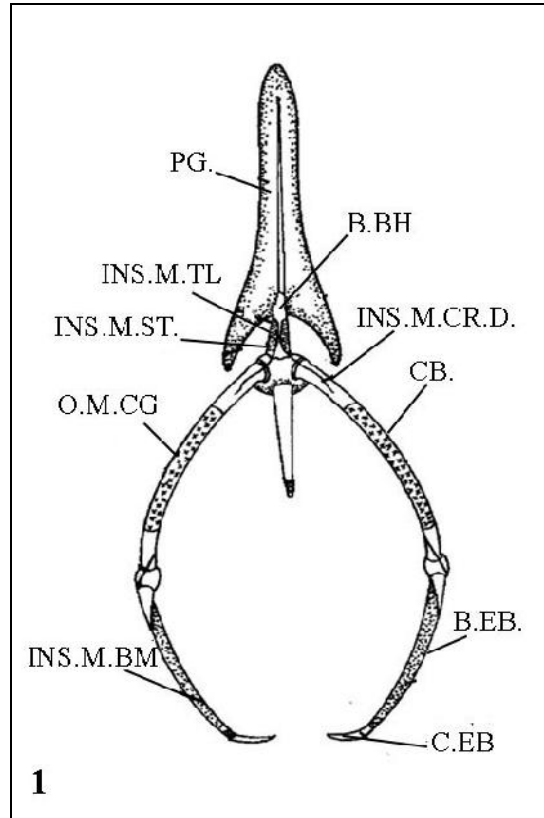


Fig.1. Diagram of dorsal view of the hyoid skeleton of the rock dove showing the paraglossale (PG), bony basihyale (B.BH), Ceratobranchiale (CB.), bony epibranchial (B.EP) and cartilaginous epibranchial (C.EP), insertion of muscle tracheolateralis (M.TL.), muscle stylohyoideus (M.ST.), muscle cricohyoideus dorsalis (INS.M.CR.D), origin muscle ceratoglossus (O.M.CG.), insertion of muscle branchiomandibularis (INS.M.BM.).

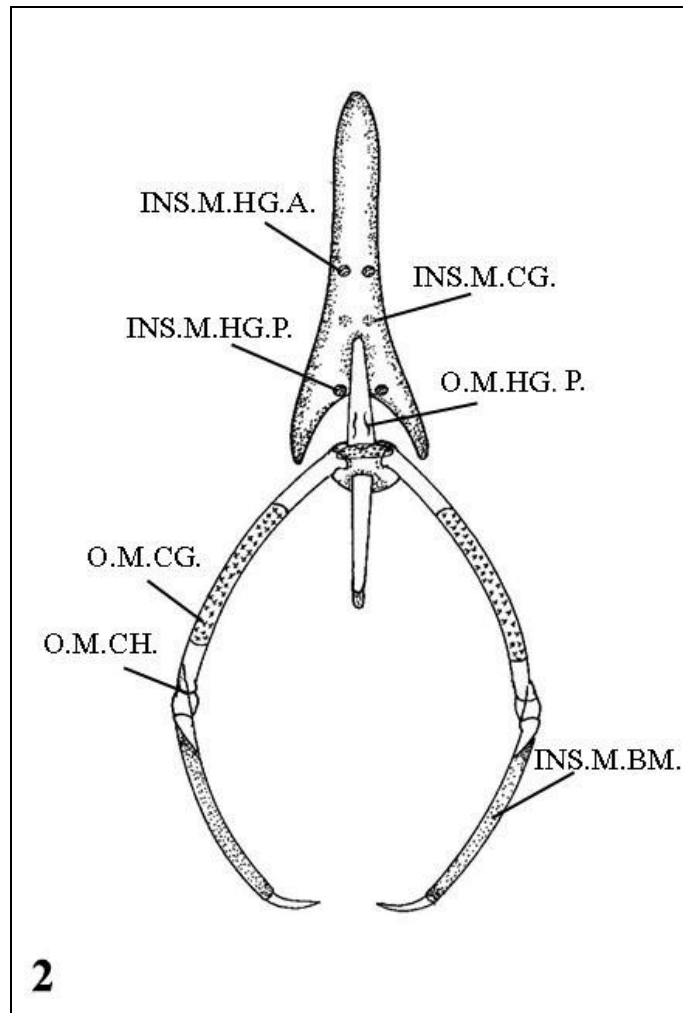


Fig.2. Diagram of ventral view of the hyoid skeleton of the rock dove showing insertion of the muscle hypoglossus anterior and posterior (INS.M.HG.A. & INS.M.HG.P.), origin and insertion of muscle ceratoglossus (O. M.CG.& INS. M.CG.), origin of muscle ceratohyodeus ( O.M.CH) and insertion of muscle branchiomandibularis (INS.M.BM.).

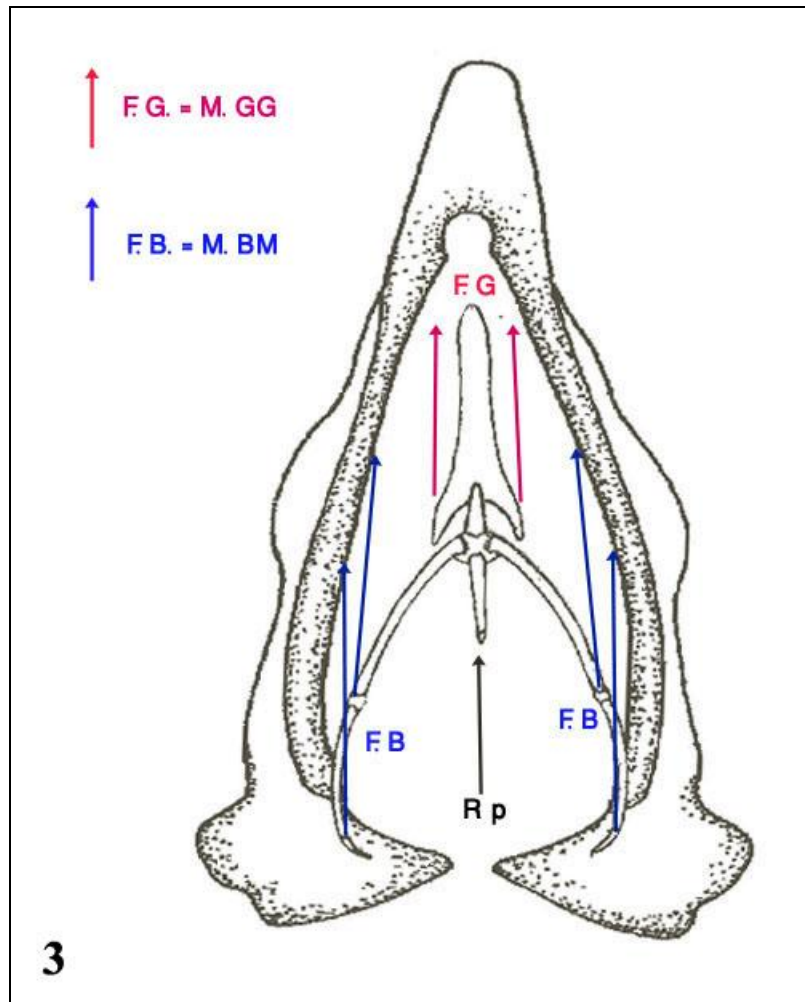


Fig.3. Dorsal view of the hyoid skeleton with a ventral view of the mandible of the rock dove, hence F.B. is the vector of the muscle branchiomandibularis, F.G. is the vector of the muscle genioglossus and the big arrow refers to the direction of the resultant force which causing protraction of the tongue, is represented by Rp .

The muscle cricohyoideus (Fig 1) originates from the distal part of ceratobranchial, This muscle retracts the tongue by pulling the basihyale and ceratobranchiale backwards. It is synergistic with the muscle stylohyoideus and the other extrinsic laryngeal muscle. Meanwhile, it affects the Articulatio cerato-basihyalis yielding to the adduction of the paired hyoid horn. Thus, it is synergistic with the muscle ceratohyoideus.

The muscle ceratoglossus (Fig 2) which originates from ceratobranchial, affects two joints within the hyoid skeleton; the Articulatio paraglossobasihyalis yielding to the flexion of the paraglossale resulting in the depression of the free portion of the tongue. Meanwhile, the muscle ceratoglossus affects the paired Articulatio cerato-basihyalis yielding to the abduction of the paired hyoid horns.

### The epibranchiale (EP.)

The epibranchiale consists of a proximal bony element and a distal cartilaginous one. It provides the site of insertion for the muscle branchiomandibularis (Fig.1). The muscle branchiomandibularis represents the main protraction muscle of the tongue. Its contraction leads to the protraction of the tongue. The muscle ceratohyoideus originates from the dorsal surface of the distal end of the ceratobranchial (Fig 2). The branchiomandibularis muscle is antagonistic to the muscle ceratohyoideus which yielding to the adduction of the paired hyoid horn resulting in the elevation of the laryngeal mound and the retraction of the tongue

**Analysis of the movements of the tongue of the Rock dove**

The base of the present morphological illustrating the analysis of the movements:

The muscle branchiomandibularis (M.BM.) and its synergistic muscle genioglossus (M.GG.) perform the

protraction of the tongue. Thus, **F.B.** and **F.G.** (Fig.3) represents the lines of action of the muscles branchiomandibularis and muscle genioglossus respectively. However, the resultant force causing the protraction of the tongue is represented by the vector **R<sub>p</sub>**.

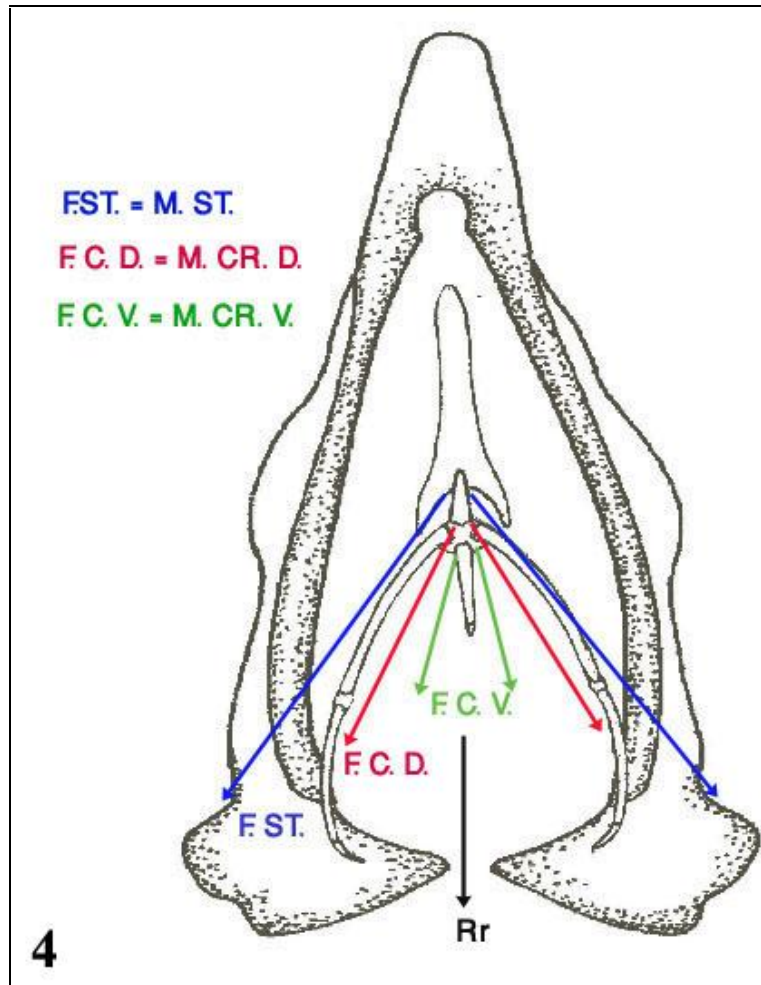


Fig.4. Dorsal view of the hyoid skeleton with a ventral view of the mandible of the rock dove, hence F.ST. is the vector of the muscle stylohyoideus, F.CR.D. is the vector of the muscle cricohyoideusdorsalis and F.CR.V. is the vector of the muscle cricohyoideusventralis. The resultant force which causing retraction of the tongue, is illustrated by R<sub>r</sub> .

The retraction of the tongue performs by the contraction of the muscle stylohyoideus (M.ST.) and by cooperation of the muscle cricohyoideus dorsalis (M.CR.D.) and muscle cricohyoideus ventralis (M.CR.V.). However, the force arm of the muscle stylohyoideus is represented by the vector **F.ST.** , and the force arm of the muscle cricohyoideus dorsalis and muscle cricohyoideus ventralis are represented by the

vector **F.C.D.** and **F.C.V.** respectively. The resultant force is illustrated by the vector **R<sub>r</sub>** (Fig. 4).

That resultant force acts along the longitudinal axis of the hyoid skeleton, but antagonistic to the resultant force of the muscles branchiomandibularis and genioglossus.



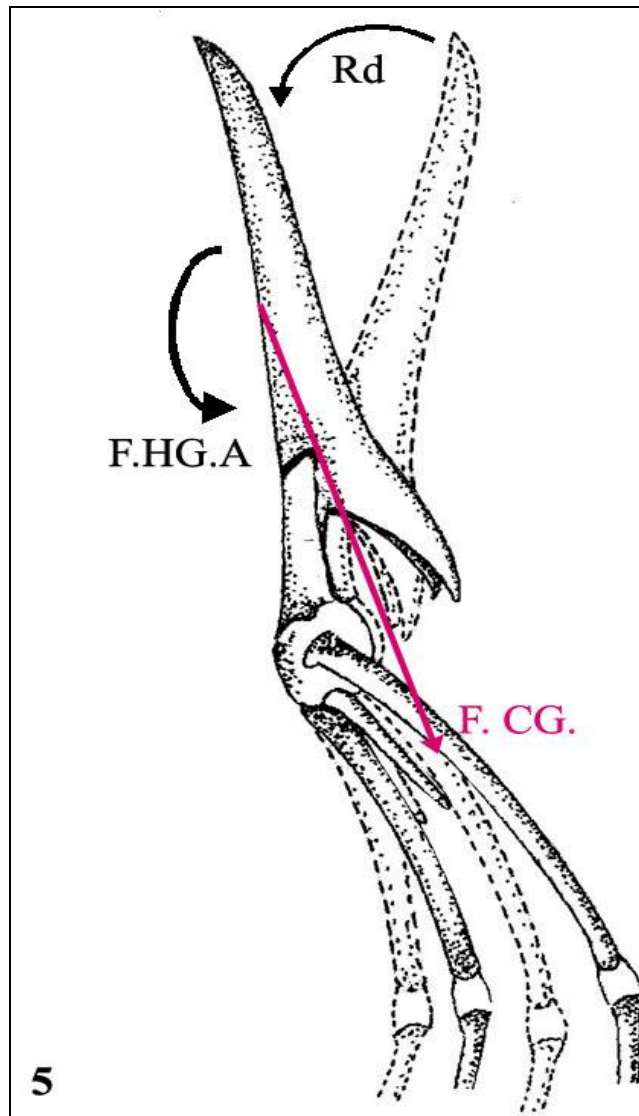


Fig.5. Lateral view of the hyoid skeleton of the rock dove, hence F.CG. is the vector of the muscle ceratoglossus, the big arrow refers to the downward movement of the free portion and the resultant force Rd. In addition, F.HG.A. is the vector of the muscle hypoglossus anterior which bending the tip of the free portion of the tongue.

The depression of the anterior tip of the tongue must be done by the contraction of the muscle ceratoglossus (M.CG.), its force arm is represented by the vector **F.CG.**. Meanwhile, the antagonistic movement is done by the contraction of the muscle hypoglossus posterior (M.HG.P.), its force arm is represented by the vector **F.HG.A.** (Fig. 5). Both muscles are antagonistic to each other and affecting the Articulatio paraglossobasihyal resulting in turning the paraglossale with counterclockwise on the basihyale. During the depression of the free portion, its posterior end elevates, causing the elevation of the posterior process of the paraglossale and vice versa.

Considering the ventral bending of the tip of the free portion of the tongue with a slight curvature, that movement is allowed by the contraction of the muscle hypoglossus anterior. This muscle does not pass on certain articulation, acts along the ventral surface of the paraglossale. However, the flexibility of the movement of the tip of the free portion is allowed by the cartilaginous endoskeleton, as well as, the exoskeletal support represented by the well formed lingual nail. The force arm of the muscle hypoglossus posterior is illustrated by the vector **F.HG.P.** (Fig.6). The relaxation of the muscle hypoglossus anterior returns the bending portion into its original position.

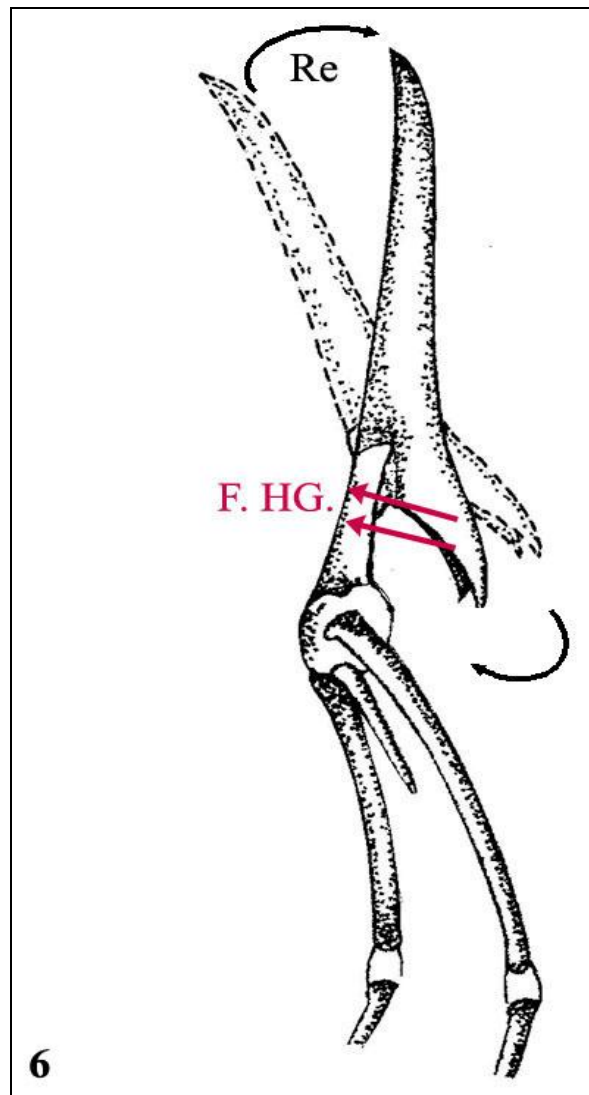


Fig.6. Lateral view of the anterior portion of the hyoid skeleton of the rock dove, hence F.HG.P. is the vector of the muscle hypoglossus posterior, the big arrow refers to upward the downward movements of the free portion, the resultant force of the muscle hypoglossus posterior is represented by Re.

## Discussion

The movements of the avian tongue is performed by the action of the lingual muscles. Meanwhile, the hyoid skeleton, the main support of the tongue, allows sites for attachment of the lingual muscles, which are in turn the generator of forces. Results of the present study showed that the hyoid skeleton is a well developed in the Rock dove like the hyoid skeleton was found in the Parrot (Homberger, 1986), and in the Egyptian black kite (Shawki, 1995). The surface structures of the paraglossale usually indicate attachment sites for muscle i.e. muscle cricohyoideus dorsalis, insertion of the muscle hypoglossus anterior and posterior. The paraglossale of Rock dove which supports the free portion of the tongue, is consisting of hyaline cartilage which has a great ability of

bending and ability to resist load and weight forces acting on the free portion of the tongue during the passage of heavy food items due to the action of several intrinsic lingual muscles. Similar observations were made in *Columba livia*, *Ducula aenea*, *Ducula badia* and *Gallinula chloropus meridionalis* (Zweers, 1982a; Bhattacharyya, 1980, 1990; and El-Beltagy, 2013), and in *Bubulcus ibis* (Shawki & Abdel-Rahmaan, 1998), but are missing in other birds like *Streptoplia decaocto* where the paraglossale is a bony element (Shawki & Al-Jaloud, 1994a). The dorsal surface of the basihyale bony provides the sites of origin for the muscle hypoglossus posterior. Results of this study also showed that the ceratobranchiale is composed of bony element and show the same result



in Chicken and Herring gull (Homberger & Meyers, 1989 and Shawki & Al-Jaloud, 1994a). The ceratobranchiale connects to the epibranchiale by a synchondrosis between two bony elements as stated by (Zweers, 1982 ; Battacharyya, 1980,1990 ; Shawki, 1995 ; Shawki & Al-Jaloud, 1994a, and Shawki & Abdel-Rahmaan, 1998). While in the Common Moorhen this synchondrosis connects bony and cartilaginous elements (Shawki & Ismail, 2006a).

Also, the ceratobranchiale provides the sites of origin and insertion for these muscles: muscle ceratoglossus, muscle branchiomandibularis, muscle ceratohyoideus. The different structural elements of the hyoid skeleton move along each other, resulting in the mobility of the tongue itself. It is allowed to roll from right to left and back.

Also, our results showed that the mandible of the Rock dove is composed of two diverged rami, which are fused anteriorly through the mandibular symphysis this is similar to the results (Zweers, 1982 ; Homberger & Meyers, 1989 and Shawki & Ismail, 2006a). Also, showed that the mandible provides sites for origin of these muscles: muscle branchiomandibularis in the medial surface while the lateral surface provides sites for origin of these muscles: muscle branchiomandibularis posterior, muscle stylohyoideus. this is similar to the results (Zweers, 1982 and Shawki & Ismail, 2006a).

The anatomy of the lingual muscles has been the object of interest since the earlier studies of the avian tongue . Recently, this interest was directed to the study of the lingual musculature as a force generator system affecting the mechanical structure, the tongue ( Berkhoudt, 1985; Shawki, 1995 ; Shawki & Al-Jaloud, 1994a,b and Shawki & Abdel-Rahmaan, 1998b). These studies exhibit the correlation between the anatomy of the tongue with its mechanical performance, which differs from species to species, and even within the same species such as in *Bubulcus ibis* (Shawki & Abdel-Rahmaan, 1998b). This variability is most probably due to the type of feeding habit of the bird. Consequently, these studies showed an extensive wide range of the anatomical variability in the musculature of the different studied species.

The intrinsic lingual muscles are the generators of forces exerting on the skeletal elements of the tongue. Meanwhile, the tongue swing as a whole inside the buccal cavity within the frame-work of the mandible, that swing movement is expressed by the protraction and retraction of the tongue which are performed by

the contraction of the muscles branchiomandibularis and stylohyoideus respectively. That performance is allowed by the wrinkled connection between the tongue and the floor of the mouth, as well as, its non-keratinized covering epithelium. Meanwhile, the Rock dove tongue has able to resist load and weight forces acting on the free portion of the tongue during the passage of heavy food items. The cartilaginous paraglossale also shows the ability of bending and temporary deformation due to the action of several intrinsic lingual muscles. That movement can be explained theoretically according to the available anatomical and histological data, since that portion is supported by the paraglossale which constitutes of hyaline cartilage (Zweers, 1982). Indeed, Shawki & Al-Jaloud (1994b) suggested the catch and throw mechanism for *Larus argentatus* depending on the anatomical investigation of the tongue of that fish eater bird. In fact, the observation of the movement of the tongue during the feeding is impossible because the tongue is a hidden organ.

However, Suzuki & Nomura (1975) described the feeding mechanism of the Chicken by using electromyography. While, Zweers (1982) suggested two different mechanisms in *Columba livia*, slide and glue for eating small grains and catch and throw for eating large ones by using cinematography. But it is interesting to note that they used domestic birds which are easily to observe in captivity.

In conclusion, the hyoid skeleton of the rock dove (*Patagioenas livia*) is a well developed. The hyoid skeletal elements allows sites for attachment of extrinsic and intrinsic lingual muscles which generate the main forces and the mechanical structure of the tongue.

### Acknowledgement

We would like to thank Deanship of Scientific Research (DSR), King Abdulaziz University, Jeddah, for their kind help and providing the necessary facilities for the preparation of this paper. This work would not have been possible without the generous assistance of DSR.

## References

- Berkhoudt, H. (1985): Structure and function of avian taste receptors. In: "Form and Function in Birds". Vol. 3. (King, A. S. and McLelland, J., eds). Academic Press, London.
- Bhattacharyya, B. N. (1980): The morphology of the jaw and tongue musculature of the common pigeon, *Columba livia*, in relation to its feeding habit; Proc. Zool. Soc. Calcutta 31: 95-127.
- Bhattacharyya, B. N. (1990): The functional morphology of the lingual apparatus of two species of Imperial Pigeons, *Ducula aeneanicobarica* and *Duculabadia insignia*; Proc. Zool. Soc. Calcutta 43: 65-92.
- Bhattacharyya, B. N. (1985): Functional morphology of the tongue muscles of Indian insect-eating birds. Morph. Jb., Leipzig, 131: 93-23.
- Bock, W. J. and Shear, C. R. (1972): A staining method for gross dissection of vertebrate muscles. Anat. Anz., 130: 222-227.
- Calislar, T. (1977): Tavuk diseksiyonu Ankara Univ Basimevi, Ankara, Turkey. 28-31.
- El-Beltagy AM (2013) Comparative studies on the tongue of whitethroated kingfisher (*Halcyon smyrnensis*) and common buzzard (*Buteo buteo*). Egypt Acad J Biol Sci 4: 1–14.
- Homberger, D.G., and Meyers, R.A. (1989): Morphology of the lingual apparatus of the domestic chicken, *Gallus gallus*, with special attention to the structure of the fascia. Am. J. Anat., 186(3):217-257.
- Homberger, D. G. (1986): The lingual apparatus of the African grey parrot *Psittacus erithacus* Linn. (Aves, Psittacidae): Description and theoretical mechanical analysis. American Ornithologists Union (AOU), 39: 1-233.
- Igwebuike, U.M., and Eze, U.U. (2010): Anatomy of the oropharynx and tongue of the African pied crow ( *Corvus albus* ). Veterinarski arhiv., 80 (4): 523-531
- Jung, J. Y; Naleway, S.E; Yaraghi, N.A; Herrera, S.; Sherman, V.R.; Bushong, E.A.; Ellisman, M. H.; Kisailus, D.; McKittrick, J. (2016): Structural analysis of the tongue and hyoid apparatus in a woodpecker. Acta Biomaterialia. 37 , 1–13
- Kooloos, J. G. M. (1986): A conveyor belt model for pecking in the mallard, *Anas platyrhynchos* L., Neth. J. Zool., 36: 47-87
- Korzoun LP, Erard C, Gasc JP (2001) Distinctive morphofunctional features of the bill and hyoid apparatus of turacos (Aves, Musophagidae): relations with frugivory. CR Acad Sci III 324: 965-77.
- Korzoun, L. P.; Erard, C., and Gasc, J. P. (2004): Morphofunctional study of the bill hyoid apparatus of *Momotus momoto* (Aves, Coraciiformes, Momotidae): implications for omnivorous feeding adaptation in motmots. C. R. Bio., 327: 319-333
- Korzoun, L. P.; Erard, C.; Gasc, J. P., and Dzerzhinsky, F. J. (2003): Adaptations of the hoatzin, *Opisthocomus hoazin*, to leaf-eating. Morphological characteristics and functional features of its bill and hyoid apparatus. C. R. Bio., 326(1): 75-94.
- Minoru, I. (1976): Differential staining of cartilage and bone in fetal mouse skeleton by alcian blue and alizarin red s. Cong. Anom., 16: 171-173.
- Shawki, N.A. (2006a): The functional morphology of the hyoid skeleton of the kestrel, *Falco tinnunculus* (Falconiformes, Aves). J. Union Arab Bio. Cairo., 25(A):18-34.
- Shawki, N.A. and Al-Jaloud, N.A. (1994b): Functional morphology of the lingual apparatus of the herring gull, *Larus argentatus*. Egypt. J. Anat., 17(4):79-108.
- Shawki, N.A., and Abd El-Rahmaan, G. H. (1998b): The functional morphology of the lingual apparatus of the cattle egret, *Bubulcus ibis*, (Aves.). J. Union Arab Bio., 9(A): 22-38.
- Shawki, N.A., and Abd El-Rahmaan, G. H. (1998b): The functional morphology of the lingual apparatus of the cattle egret, *Bubulcus ibis*, (Aves.). J. Union Arab Bio., 9(A): 22-38.
- Shawki, N.A., and Abd El-Rahmaan, G. H. (1998b): The functional morphology of the lingual apparatus of the cattle egret, *Bubulcus ibis*, (Aves.). J. Union Arab Bio., 9(A): 22-38.
- Shawki, N.A., and Al-Jaloud, N. A. (1994a): Structure and function of the lingual apparatus of the collared dove, *Sterptopelia decaocto*, Egypt. J. Anat., 17(4): 51-78
- Shawki, N. A. (1995): A correlation between the functional morphology of the lingual apparatus and feeding behavior of the Egyptian black kite, *Milvus migrans aegyptius*. Egypt. J. Anat., 18(2): 179-209
- Shawki, N. A. (1995): A correlation between the functional morphology of the lingual apparatus and feeding behavior of the Egyptian black kite, *Milvus migrans aegyptius*. Egypt. J. Anat., 18(2): 179-209
- Suzuki, M. and Nomura, S. (1975): Electromyographic studies on the deglutition movement in fowl. Jap. J. vet. Sci. 37: 289-293.

- Zweers, G. A. (1974): Structure, movement and myography of the feeding apparatus of the mallard, *Anas platyrhynchos L.*, Neth. J. Zool. 24: 323-467.
- Zweers, G. A. (1982a): The feeding system of the pigeons, *Columba livia L.*, . Adv. Anat. Embryol. Cell Bio., 73: 1-108
- Zweers, G. A.; Gerritsen, A. F. C., and Kranenburg-Voogd, P. J. van (1977): Mechanics of feeding of the mallard (*Anas platyrhynchos L.*, Aves, Anseriformes). In: Hecht MK., Szalay FS. (eds.). Contributions to Vertebrate Evolution.3: 109. Karger, Basel

Access this Article in Online	
	Website: <a href="http://www.ijarbs.com">www.ijarbs.com</a>
	Subject: <b>Biology</b>
<b>Quick Response Code</b>	
DOI: <a href="https://doi.org/10.22192/ijarbs.2017.04.10.009">10.22192/ijarbs.2017.04.10.009</a>	

**How to cite this article:**

Fatma A. Al-Nefeyy. (2017). Kinetics Of The Hyoid Skeleton Of The Rock Dove (*Patagioenas livia*). Int. J. Adv. Res. Biol. Sci. 4(10): 51-61.

DOI: <http://dx.doi.org/10.22192/ijarbs.2017.04.10.009>